

Toric Implantable Collamer Lens Implantation Combined with Femtosecond Laser-Assisted Arcuate Keratotomy to Correct High Post-Penetrating Keratoplasty Refractive Errors

Jingliang He¹, Tao Zhang¹, Tiehong Chen², Suqing Liu¹ and Shaowei Li^{1*}

¹Aier School of Ophthalmology, Central South University, Changsha, Beijing, China

²Shenyang Aier Eye Hospital, Shenyang, China

Received March 20, 2018; Accepted April 18, 2018; Published June 18, 2018

ABSTRACT

We report a case of a young patient with keratoconus, whose left eye presented with high myopia astigmatism (-2.25 -8.5 × 100) following penetrating keratoplasty. Femtosecond laser assisted arcuate keratotomy (FLAK) was performed and the patient's astigmatism was significantly reduced after the procedure. However, the visual acuity was still limited by residual myopia astigmatism (-8.00 -3.75 × 110). A Toric implantable collamer lens (TICL) was used to this condition. The refraction after implantation improved to -0.50 -0.75 × 65 with an uncorrected distance visual acuity (UDVA) of 20/25 and a corrected distance visual acuity (CDVA) of 20/20. The combination of TICL implantation and FLAK is a candidate for correcting residual myopia astigmatism following PKP.

Keywords: Keratoplasty, Arcuate keratotomy, Toric implantable collamer lens, Femtosecond laser

INTRODUCTION

Arcuate keratotomy (AK) is a procedure which has been widely used in correction of astigmatism after penetrating keratoplasty (PKP) [1,2]. However, AK has certain limitations such as low reproducibility and tendency to undercorrect [3,4]. Despite that the application of femtosecond laser in AK has improved its accuracy, this procedure is still not effective enough, as evidenced by the frequent occurrences of residual astigmatism or/and myopia [5,6]. Nonsurgical therapies such as spectacles and contact lenses are not always effective in correcting these residual refractive errors, because spectacles correction is unsuitable for high level of anisometropia, and the use of contact lenses is dependent on lens tolerance of patients. Laser in situ keratomileusis (LASIK) and photorefractive keratectomy (PRK) are common procedures for correcting these residual refractive errors are limited by the thickness of graft and therefore, are not appropriate in ameliorating high level of residual refractive errors after AK. Here, we present a case of high myopia astigmatism post-PKP, which was not completely corrected by femtosecond laser-assisted arcuate keratotomy (FLAK) alone, but was properly corrected by a combined therapy of FLAK and Toric implantable collamer lens (TICL implantation).

CASE REPORT

The patient was a 23-year-old man who had received PKP in his left eye. Three months after suture removal, the vision in his left eye could not be improved to a satisfying level due to high residual myopia astigmatism (Table 1). Regarding his

right eye, the manifest refraction was -0.75 -0.75×60. The UDVA was 20/20. The examination of intraocular pressure (IOP), crystalline lens and retina was normal. AK was implemented under topical anesthesia with INTRALASE FS SYSTEM (Advanced Medical Optics) after receiving patient's informed consent. The length and location of the arcuate incisions were determined based on the borders of the steep semi-meridians, which were identified by corneal topography [1] Parameter settings including posterior depth (469 μm, 80% depth of the thinnest corneal thickness), anterior diameter (6.0 mm), anterior energy (1.5 μJ), cut position 1 (35 degree), cut angle 1 (70 degree), cut position 2 (175 degree), cut angle 2 (90 degree), anterior side cut angle (120 degree) and anterior side cut spot separation (3μm).

Corresponding author: Shaowei Li, M.D., Aier School of Ophthalmology, Central South University, Changsha, China; Beijing Aier-Intech Eye Hospital, Panjiayuan plaza, 12# Panjiayuan Nanli, Chaoyang District, Beijing, China, Post: 100021, Tel: +86-185-1848-3765; Fax: 010-67758429; E-mail: shaoweili2005@vip.163.com

Citation: He J, Zhang T, Chen T, Liu S & Li S. (2018) Toric Implantable Collamer Lens Implantation Combined with Femtosecond Laser-Assisted Arcuate Keratotomy to Correct High Post-Penetrating Keratoplasty Refractive Errors. *Ophthalmol Clin Res*, 1(1): 13-16.

Copyright: ©2018 He J, Zhang T, Chen T, Liu S & Li S. This is an open-access article distributed under the terms of the Creative Commons Attribution License, which permits unrestricted use, distribution, and reproduction in any medium, provided the original author and source are credited.

The astigmatism was obviously reduced (**Figure 1**), but with high residual myopia astigmatism remained (**Table 1**) 22 months after FLAK. Therefore, a TICL was implanted after another informed consent was signed. Preoperative examinations established the following parameters: corneal

topography (50.7@25/47.0@115), anterior chamber depth (3.69 mm), white-to-white distance (11.5 mm), manifest refraction (-8.00 -3.75x110), IOP (11 mmHg) and endothelial cells density (ECD, 2196/mm²).

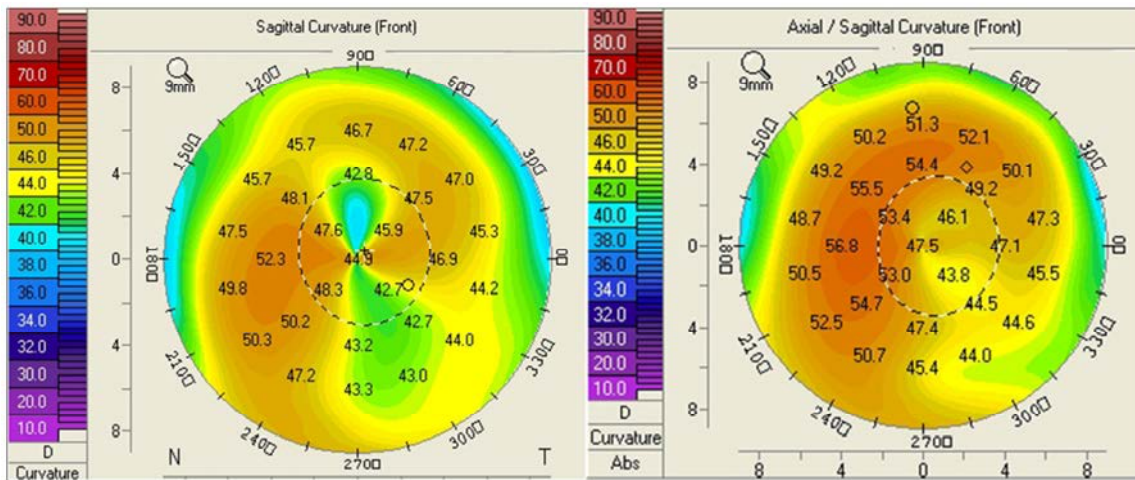


Figure 1. Left, corneal topography before FLAK. Right, astigmatism was obviously improved at 22-months follow-up.

Table 1. Preoperative and postoperative clinical measurements.

	UDVA	CDVA	Keratometry (D)	Manifest refraction (D)
Preoperative	20/125	20/32	50.2@7/41.6@97	-2.25 -8.5 × 100
After AK				
1w	20/200	20/25	48.9@12/44.5@102	-3.50 -6.00 × 126
3month	20/125	20/32	50.2@7/47.3@97	-7.75 -3.25 × 114
12month	20/200	20/32	50.4@176/47.1@86	-7.50 -3.75 × 110
22month	20/125	20/32	50.7@25/47.0@115	-8.00 -3.75 × 110
After TICL implantation				
3month	20/25	20/20		-1.00 -0.5 × 135
6month	20/25	20/20		-0.50 -0.75 × 65

A final TICL (VTICMO 13.2 mm, -13.5 +4.0x023, STAAR surgical) was determined by the software provided by

manufacturer and it was implanted into the left eye of the patient under topical anesthesia (**Figure 2**).

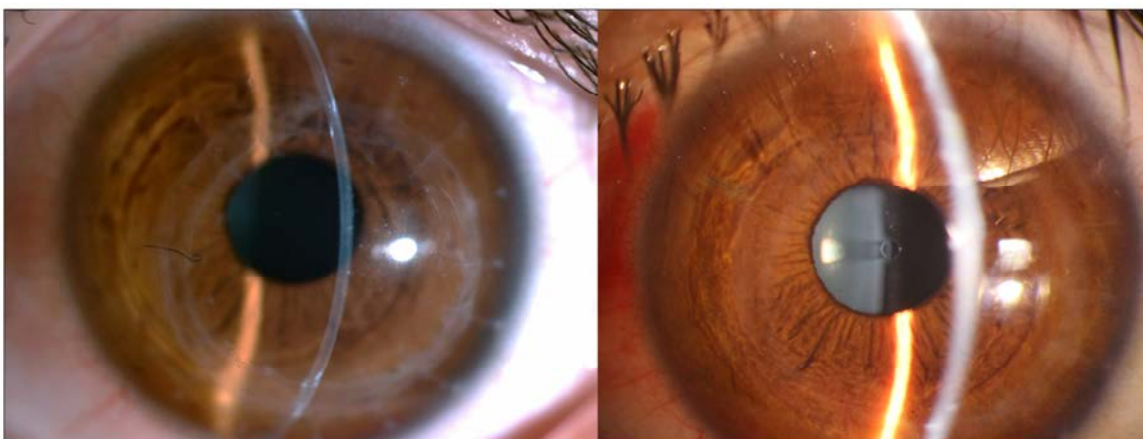


Figure 2. Left, Photograph of slitlamp shows the transplanted cornea was transplant before FLAK. Right, photograph of slitlamp shows the TICL in patient's left eye.

The manifest refraction, UCVA and CDVA showed obvious improvements 3 months after TICL implantation compared with those before the procedure (**Table 1**). These significant improvements of his vision and refractive error were sustained at the 6-month follow-up. In addition, the ECD was 2106/mm² with a loss rate of 4.1% at 3-month follow-up and 2055/mm² with a loss rate of 6.4% at 6-month follow-up. No intraoperative or postoperative complications were observed at the follow-ups.

DISCUSSION

AK was considered as an effective way to reduce the high level of astigmatism after PKP [1,2]. In this study, we observed a reduction of refractive cylinder of 55.9%, which was consistent with previous reports [1,7-9]. The reduction of keratometric cylinder was 57%, which was also similar to those seen in other studies [7,8]. However, neither the UDVA nor the CDVA improved evidently (**Table 1**). It is worth noting that we observed an obvious myopia shift of spherical equivalent (SE) at 3-month follow-up. This trend of myopic shift development after AK was probably associated with the increase in central corneal curvature, which occurred due to the release of axial tension within the graft and a concomitant increase in the corneal vault. Another possible reason of this process was two large arcuate incisions (70 degree and 90 degree) performed on graft, which dramatically weakened the mechanical strength of graft and resulted in ectasia. Fortunately, this process stopped, and the topography and refraction were stable at the subsequent follow-ups.

Although there was a significant reduction in astigmatism after FLAK, the residual myopia astigmatism (-8.00 - 3.75×110) was so high that the patient's vision was still unsatisfactory, which was too high for refractive surgery to be safe. Severe anisometropia rendered spectacle correction infeasible, and the patient was intolerant of long-term use of contact lenses. We therefore performed TICL implantation to improve the results of FLAK. TICL implantation has been reported as a potential procedure for correcting myopia and astigmatism after PKP and anterior lamellar keratoplasty [10-12]. However, to our knowledge, the management of TICL implantation to correct high residual refractive errors after FLAK has not been reported.

The manifest refraction and visual acuity showed significant improvements and reached satisfactory levels after the surgery (**Table 1**). A low rate of ECD loss (6.4% at 6 months) similar to that reported by a previous study (5.11% at 6 months) [7] was observed in our case. No cataract, opacification and IOP elevation were observed during 6-month follow-up. However, Fernandes et al. [13] reported that 5.2% of eyes developed cataract after ICL implantation during at least 3-year follow-up. So we need to perform longer follow-ups to estimate the long-term safety of this treatment.

Although AK can effectively reduce severe astigmatism after PKP, the predictability of AK remains unsatisfactory and secondary treatments are usually inevitable. TICL implantation not only can accurately correct residual myopia astigmatism, especially high residual myopia astigmatism after AK, which is unsuitable to perform LASIK or PRK. It may also be a safer option than LASIK and PRK, which might be responsible for complications such as iatrogenic corneal ectasia [14] and the increased risk of graft rejection. Therefore, in our opinion, combining TICL implantation with FLAK is a candidate for the correction of high residual myopia astigmatism after PKP. The effectiveness, safety and predictability of this procedure are worthy of further studies.

ACKNOWLEDGEMENTS

Disclosure: Neither author has a financial or proprietary interest in any material or method mentioned.

Funding: No funding

Additional contributions: No additional contribution.

REFERENCES

1. Nubile M, Carpineto P, Lanzini M, et al. (2009) Femtosecond laser arcuate keratotomy for the correction of high astigmatism after keratoplasty. *Ophthalmol* 116: 1083-1092.
2. Viswanathan D, Kumar NL (2013) Bilateral femtosecond laser-enabled intrastromal astigmatic keratotomy to correct high post-penetrating keratoplasty astigmatism. *J Cataract Refract Surg* 39: 1916-1920.
3. Buzzonetti L, Petrocelli G, Laborante A, et al. (2009) Arcuate keratotomy for high postoperative keratoplasty astigmatism performed with the intralase femtosecond laser. *J Refract Surg* 25: 709-714.
4. Bayramlar H, Karadag R, Cakici O, et al. (2016) Arcuate keratotomy on post-keratoplasty astigmatism is unpredictable and frequently needs repeat procedures to increase its success rate. *Br J Ophthalmol* 100: 757-761.
5. Fadlallah A, Mehanna C, Saragoussi JJ, et al. (2015) Safety and efficacy of femtosecond laser-assisted arcuate keratotomy to treat irregular astigmatism after penetrating keratoplasty. *J Cataract Refract Surg* 41: 1168-1175.
6. Loriaut P, Borderie VM, Laroche L (2015) Femtosecond-Assisted Arcuate Keratotomy for the Correction of Postkeratoplasty Astigmatism: Vector Analysis and Accuracy of Laser Incisions. *Cornea* 34: 1063-1066.
7. Cleary C, Tang M, Ahmed H, et al. (2013) Beveled femtosecond laser astigmatic keratotomy for the

treatment of high astigmatism post-penetrating keratoplasty. *Cornea* 32: 54-62.

8. Hoffart L, Proust H, Matonti F, et al. (2009) Correction of postkeratoplasty astigmatism by femtosecond laser compared with mechanized astigmatic keratotomy. *Am J Ophthalmol* 147: 779-787.
9. Wetterstrand O, Holopainen JM, Krootila K (2013) Treatment of postoperative keratoplasty astigmatism using femtosecond laser-assisted intrastromal relaxing incisions. *J Refract Surg* 29: 378-382.
10. Akcay L, Kaplan AT, Kandemir B, et al. (2009) Toric intraocular Collamer lens for high myopic astigmatism after penetrating keratoplasty. *J Cataract Refract Surg* 35: 2161-2163.
11. Alfonso JF, Lisa C, Abdelhamid A, et al. (2009) Posterior chamber phakic intraocular lenses after penetrating keratoplasty. *J Cataract Refract Surg* 35: 1166-1173.
12. Qin Q, Yang L, He Z, et al. (2017) Clinical application of TICL implantation for ametropia following deep anterior lamellar keratoplasty for keratoconus: A CONSORT-compliant article. *Medicine* 96: e6118.
13. Fernandes P, Gonzalez-Mejome JM, Madrid-Costa D, et al. (2011) Implantable collamer posterior chamber intraocular lenses: a review of potential complications. *J Refract Surg* 27: 765-776.
14. Ghanem RC, Ghanem MA, Bogoni A, Ghanem VC (2013) Corneal ectasia secondary to LASIK after arcuate keratotomy. *J Refract Surg* 29: 426-429.