

Effects of Mobile Phone Radiation and Exercise on Testicular Function in Male Wistar Rats

Okechukwu Chidiebere Emmanuel*

*Department of Physical Activity and Health Promotion, Faculty of Medicine, University of Rome Tor Vergata, Rome, Italy.

Received September 10, 2018; Accepted November 11, 2018; Published October 10, 2019

ABSTRACT

Background: No study has been carried out before to determine the “effects of mobile phone radiation and exercise on serum testosterone levels, testicular weight and testicular architecture in male wistar rats as a combined research work. The aim of this study is to investigate the effects of mobile phone radiation and exercise on testicular function in male wistar rats.

Methods: Twenty male wistar rats weighing 150-198 g were used for this experiment. The animals were divided into 4 groups (n=5). The first group was the control group. The second group was exposed to mobile phone radiation for 6 h daily. The third group was subjected to swimming >3 times a week and >30 min each session or >90 min a week. The fourth group containing 5 rats was exposed to mobile phone for 6 h daily and was subjected to swimming for >3 times a week and >30 min each session or >90 min a week. This experiment lasted for 30 days. A Nokia 1280 cell phone was used to emit electromagnetic waves (EMW) and the cages of group 2 and 4 were surrounded with aluminum foils to focus and limit the waves to the interior of the cages, the phone was placed 0.5 cm under the cage. A radiofrequency radiometer was kept close to the cages to detect cell phone radiation.

Results: Short term exposure of male wistar rats to mobile phone radiation (6 h/day × 30 days at 1.6 w/kg specific absorption rate) lead to a statistical non-significant (p>0.05) decrease in serum testosterone levels and testicular weight. Exercise (>3 times a week and >30 min each session or >90 min a week) lead to statistical non-significant (p>0.05) increase in testosterone levels and testicular weight.

Conclusion: The findings of this study indicated that Short term exposure of male wistar rats to mobile phone radiation lead to a statistical non-significant decrease in serum testosterone levels and testicular weight while regular exercise lead to a statistical non-significant increase in testosterone levels and testicular weight.

Keywords: Mobile phone radiation, Exercise, Testicular function, Testosterone levels, Testicular weight, Male wistar rats, Swimming

INTRODUCTION

Mobile phones are radio devices that transmit and receive radio frequency radiation at 900-2000 MHz. Electromagnetic waves emitted by mobile phones can damage sex organs and cause hormonal disorders, Cell phone technology is an integral part of everyday life and its use is not only restricted to voice conversations but also conveying news, high resolution pictures and internet.

Exercise consists of activities that are planned and structured and that maintains or improves one or more of the components of physical fitness. Dynamic exercise is defined as skeletal muscle contractions at changing lengths and with rhythmic episodes of relaxation. The magnitude of testosterone release during exercise can be varied by exercise mode, intensity, and duration [1]. An acute bout of exercise rapidly elevates testosterone level in circulation. This response is mediated by increased sympathetic activity

during exercise and lactate, a metabolite produced from exercised skeletal muscle during anaerobic glycolysis [2].

No study has been carried out before to determine the “effects of mobile phone radiation and exercise on serum

Corresponding author: Okechukwu Chidiebere Emmanuel, Department of Physical Activity and Health Promotion, Faculty of Medicine, University of Rome Tor Vergata, Rome, Italy, Tel: +393249908039; E-mail: Chidiebereokechukwu2015@gmail.com

Citation: Emmanuel OC. (2019) Effects of Mobile Phone Radiation and Exercise on Testicular Function in Male Wistar Rats. *Adv Res Endocrinol Metab*, 1(1): 1-10.

Copyright: ©2019 Emmanuel OC. This is an open-access article distributed under the terms of the Creative Commons Attribution License, which permits unrestricted use, distribution, and reproduction in any medium, provided the original author and source are credited.

testosterone levels, testicular weight and testicular architecture in male wistar rats as a combined research work. Nigeria has the highest number of mobile phone users in Africa, with more than 150 million subscribers and recent studies have shown that Electromagnetic radiation emitted by mobile phones has an adverse effect on male fertility.

Lack of exercise and obesity adds to the general effect of aging and low testosterone levels [3]. Recent studies have shown that testosterone is more responsive to higher intensity exercise [4] and a longer duration of exercise [5-9]. The aim of this study is to investigate the effects of mobile phone radiation and exercise on testicular function in male wistar rats.

This study gives an insight into the possible effects of mobile phone radiation and exercise on serum testosterone levels, testicular weight and testicular architecture in male wistar rats, this can be linked to adult human males that make use of the mobile phones frequently in their homes and offices, e.g. bankers, telecommunication workers, Customer care service men, doctors, pilots, receptionists, etc., and male individuals who are fond of putting their mobile phones on their side pockets which is very close to their testes. This study will also help researchers to understand testosterone response to exercise with regards to athletes and individuals who exercise regularly. Further studies will determine if mobile phone radiation and exercise has a significant effect on testicular function.

METHODS

Study design

This experimental study was conducted at the department of Human Physiology Laboratory, Faculty of basic medical science, Nnamdi Azikiwe University Anambra state Nigeria with a total of twenty male wistar rats that were allowed to acclimatize to the environment for one week; they were subjected to exercise for one month and exposed to mobile phone radiation for 30 days. The rats were fed ad-libitum with standard rat diet and distilled water. The animal room was well ventilated within temperature range of 25-27°C. The rats were labeled and divided into 4 groups. The weights were recorded weekly before and during experimentation.

Study procedure

Twenty male wistar rats weighing 150-198 g were divided into 4 groups (n=5). The first group was the control group. The second group was exposed to mobile phone radiation (900-1800 MHz) for 6 h daily. The third group containing 5 rats was subjected to swimming >3 times a week and >30 min each session or >90 min a week. The fourth group was exposed to mobile phone radiation (900-1800 MHz) for 6 h daily and was subjected to swimming >3 times a week and >30 min each session or >90 min a week, this experiment lasted for 30 days. A Nokia 1280 cell phone was used to emit Electromagnetic waves (EMW) radiation and the cage

of group 2 and 4 were surrounded with aluminum foils to focus waves and limit the electromagnetic field to the interior of the cages. During wave exposure, the cell phone was set in different modes; including call, missed call and turned-on mode (without real talk), the mobile phone was placed 0.5 cm under the cage.

Measurement of mobile phone radiation

A dual band (900 MHz, 1800 MHz) Nokia 1280, in receiving mode was used as radiation source in this experiment. Its SAR rating is 1.15 based on 1.6 W/kg averaged over one gram of body tissue or 0.81 based on 2.0 W/kg averaged over ten grams of body tissue. The lower the specific absorption rate (SAR) rating of a phone the better it is. Therefore using a phone with SAR rating of 1.15 represents a near worst-case scenario. Nokia Asha 202 also of the same dual band, SAR rating 1.01 based on 1.6 W/kg averaged over one gram of body tissue or 1.11 based on 2.0 W/kg averaged over ten grams of body tissue, was used as transmitting phone in this experiment. The SAR ratings of both the receiving and transmitting mobile phones fall within the international standard of exposure limit for public exposure which is 1.6 W/kg radiation rating averaged over one gram of body tissue. A radiofrequency radiometer was kept close to the cages to detect cell phone radiation.

Animal sacrifice

At the end of the 30 days experiment, the animals were sacrificed between 9:00 AM and 11:00 AM to minimize the diurnal fluctuations of hormonal secretion. The animals were anesthetized using chloroform and sacrificed by cervical dislocation 12 h after the last experiment and their testes were excised following abdominal incision and were weighed with an electronic weighing machine, fixed in 10% formalin for histological analysis.

Serum testosterone analysis

Blood samples were collected via cardiac puncture, stored in plain tubes without anticoagulants and allowed to clot. The clotted blood samples were centrifuged at 2000 rpm for 15 min to obtain the serum. Serum was stored at -20°C until analysis. Serum testosterone level was measured by using Enzyme-Linked-Immuno Sorbent Assay (ELISA) kits produced by Monobind Inc., Lake Forest, CA, USA. Accu Bind ELISA Microwells Testosterone test system with the product code: 3725-300. The sensitivity of hormone detected per assay tube was 0.05 ng/ml.

Histological analysis

The rats' testes were carefully dissected out following abdominal incision and fixed in 10% formalin. The left testes of the rats in all the groups were processed routinely for paraffin embedding. 5 μ sections were obtained with rotatory microtome. The tissue samples were embedded in paraffin and 5 mm cross-sections was stained with hematoxylin-eosin. All slides were examined under a light

microscope on a 400x magnification and Sections were observed.

Measurement of testicular weight

The left and right testes of the rats in all the groups were dissected out, freed from adherent tissues and weighed up to the nearest 0.001 g on a mettler analytical balance (PE 1600, Mettler Instrument AG; Switzerland). The result was computed per 100 g of body weight.

STATISTICAL ANALYSIS

The data collected during the experiment was analyzed by one way ANOVA test determined at (P<0.05) using SPSS version 20 software package. Depended paired T-test was used to compare the results within the groups. All the result were presented as Mean and Standard error of Mean (Mean ± SEM), n=5.

RESULTS

Effect of mobile phone radiation and exercise on serum testosterone levels of male wistar rats

Table 1 shows ANOVA analysis comparing serum level of testosterone based on groups’ treatment. **Figure 1** shows the mean of serum testosterone concentration of Group 1 (control group) (3.18 ± 0.41) when compare to that of the Group 2 (1.74 ± 0.73) which was exposed to mobile phone radiation only for 30 days shows a decreased statistically no significant difference (p>0.05), but when it was compare to the mean of Group 3 (3.44 ± 0.49) which was subjected to exercise only for one month it shows an increased statistically no significant difference (p>0.05), however, when compared to the mean of Group 4 (2.84 ± 0.33) which was exposed to mobile phone radiation and exercise for 30 days shows a slight decreased statistically no significant difference (p>0.05).

Table 1. ANOVA analyses comparing serum level of testosterone based on groups treatment.

Groups	N	Mean ± STD (ng/ml)	P-Value	F-Value
Serum testosterone concentration group 1 (control)	5	3.18 ± 0.41		2.112
Serum testosterone concentration group 2 (exposed to mobile phone radiation only)	5	1.74 ± 0.73	0.065	
Serum testosterone concentration group 3 (exercise only)	5	3.44 ± 0.49	0.726	
Serum testosterone concentration in group 4 (exposed to mobile phone radiation and exercise)	5	2.84 ± 0.33	0.647	

*. The mean difference is significant at the 0.05 level

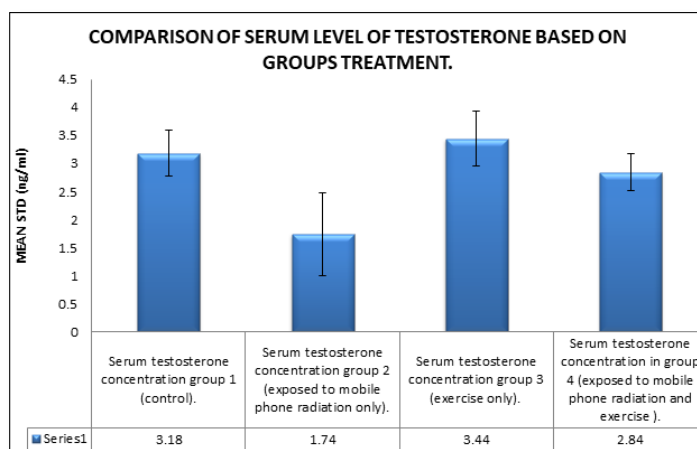


Figure 1. Comparison of serum testosterone based on group’s treatment.

Effect of mobile phone radiation and exercise on testicular weight of male wistar rats

Table 2 shows the ANOVA analysis comparing the left testicular weight and right testicular weight of the various groups respectively based on groups’ treatment. **Figure 2**

shows the mean of left testicular weight of Group 1 (control group) (1.27 ± 0.04) when compared to that of the Group 2 (1.11 ± 0.04) which was exposed to mobile phone radiation only for 30 days shows a decreased statistically no significant difference (p>0.05),when it was compared to the mean of Group 3 (1.37 ± 0.03) which was subjected to

exercise only for one month it shows an increased statistically no significant difference ($p > 0.05$), however, when compared to the mean of Group 4 (1.53 ± 0.07) which was exposed to mobile phone radiation and subjected to exercise for one shows an increased statistically significant difference ($p < 0.05$). for the right testicular weight, the result shows the mean of right testicular weight of Group 1 (control group) (1.27 ± 0.03) when compared to that of the Group 2 (1.13 ± 0.05) which was exposed to mobile phone

radiation only for 30 days shows a decreased statistically no significant difference ($p > 0.05$), but when it was compare to the mean of Group 3 (1.38 ± 0.06) which was subjected to exercise only for one month it shows an increased statistically no significant difference ($p > 0.05$), however, when compared to the mean of Group 4 (1.50 ± 0.06) which was exposed to mobile phone radiation and subjected exercise for one month shows an increased statistically significant difference ($p < 0.05$).

Table 2. ANOVA analysis comparing testicular weight/100 g of body weight based on groups treatment.

Parameter Comparism		N	Mean \pm SEM	P-Value	F-Value
Left Testicular Weight	Group 1	5	1.27 ± 0.041	0.000	10.788
	Group 2	5	1.11 ± 0.04		
	Group 3	5	1.37 ± 0.03		
	Group 4	5	1.53 ± 0.07		
Right Testicular Weight	Group 1	5	1.27 ± 0.03	0.002	7.575
	Group 2	5	1.13 ± 0.05		
	Group 3	5	1.38 ± 0.06		
	Group 4	5	1.50 ± 0.06		

*. The mean difference is significant at the 0.05 level

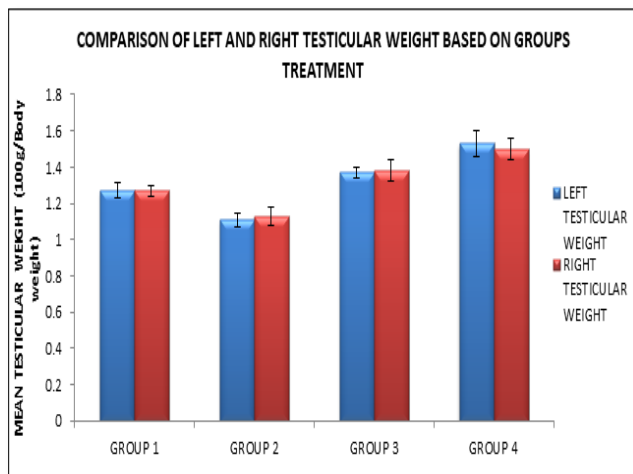


Figure 2. Comparison of left and right testicular weight based on group’s treatment.

Histological examination of testes

The testes of the rats in the control Group 1 (**Figure 3**) contain a good number of seminiferous tubules with connecting tissue separating them, boundary tissue consists

of outer layer of collagen fiber, normal sized seminiferous tubules which were full of spermatogenic cells with scanty interstitial tissue and few Leydig cells and intact germinal epithelial layers of adjacent seminiferous tubules were present.

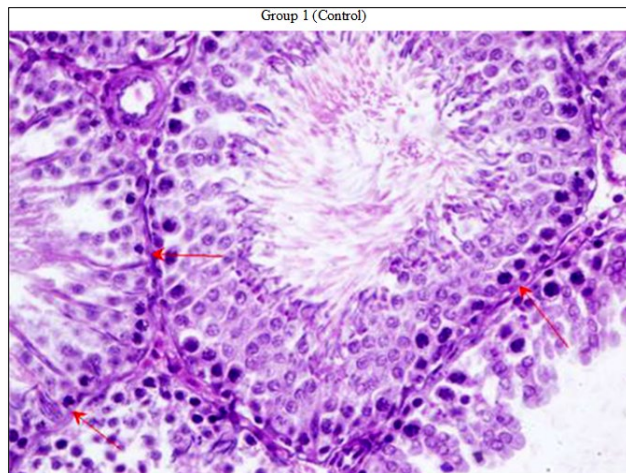


Figure 3. Testicular section of wistar rat testis (control group) not exposed to mobile phone radiation and was not subjected to exercise [H+E stain, 400 magnifications] shows normal spermatogenesis (first and second red arrow from the left) within seminiferous tubule. Intact germinal epithelial layers of adjacent seminiferous tubules (arrow on the right side), Leydig cells at the interstitial spaces, Sertoli cells, spermatogonia, spermatocytes, spermatids, and numerous mature spermatozoa are clearly visible.

Light microscopic examination of the testes sections of rats in Group 2 (**Figure 4**) exposed to mobile phone radiation for 6 h/day for 4 weeks shows alterations in the seminiferous tubules of testis compared with the control group. Inhibition of spermatogenesis was observed. The number of the sperms was reduced; some tubules showed spermatocytes. The

Leydig cells were degenerated and the intertubular blood vessels were dilated and congested. Most of the tubules were devoid of sperms and in others the sperms were scattered randomly in the tubules. Although other phases of the cycle could be observed, some tubules present signs of necrosis.

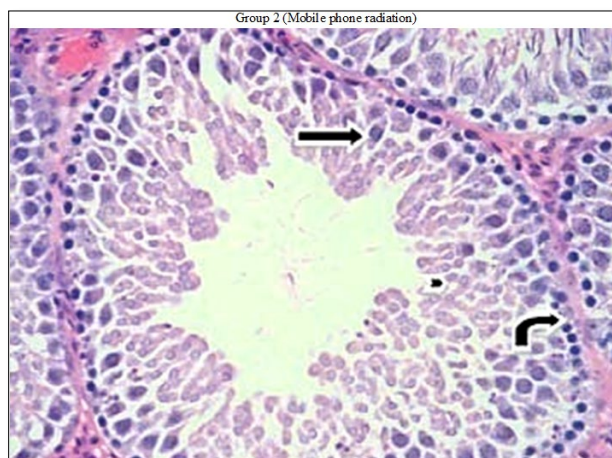


Figure 4. Testicular section of Wistar rat testis exposed to mobile phone radiation [H+E Stain, 400 magnifications] shows features of incomplete spermatid maturation arrest. [Mature spermatozoa are almost totally absent]. Shows the seminiferous tubule, the Leydig cells at the interstitial spaces are small and few in number, Sertoli cells, spermatogonia (curved arrow), spermatocytes (straight arrow) and spermatids (arrow head). Mature viable spermatozoa are almost completely absent.

Light Microscopic examination of the testes section of rats in Group 3 (**Figure 5**) subjected to exercise for one month shows full spermatogenic activity of the seminiferous epithelium cycle represented by spermatogonia, primary

spermatocytes, secondary spermatocytes and spermatids as well as nutritive Sertoli cells was observed. Seminiferous tubules separated by intertubular connective tissues with Leydig cells. The lumen was filled with spermatozoa.

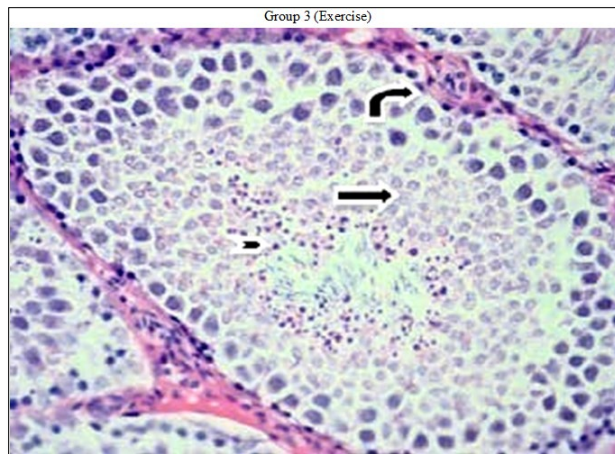


Figure 5 Testicular section of male wistar rat testis subjected to exercise [H+E Stain, 400 magnifications] shows normal active spermatogenesis, there are Sertoli cells, spermatogonia (curved arrow), and many Leydig cells at the interstitial spaces, spermatocytes, spermatids (straight arrow) and numerous mature spermatozoa (arrowhead).

Light Microscopic examination of the testes section of rats in Group 4 (**Figure 6**) exposed to mobile phone radiation and exercise for one month revealed some alterations in both the interstitial tissue and seminiferous tubules. The

detachment between the adjacent seminiferous tubules was observed at several places and number of Leydig cells at interstitial space was observed as decreased.

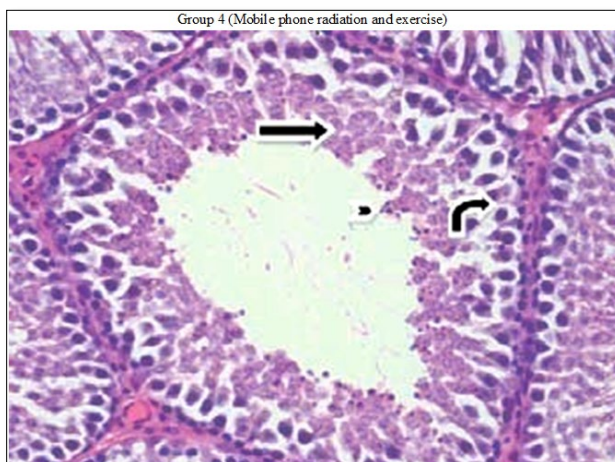


Figure 6. Testicular section of Wistar rat testis exposed to Mobile phone radiation and exercise [H+E stain, 400 magnifications] shows a seminiferous tubule with low spermatogenesis. The numbers of Leydig cells at the interstitial spaces are slightly decreased. Sertoli cells, spermatogonia (curved arrow), spermatocytes, spermatids (straight arrow). However there is a significant reduction in the number of mature spermatozoa (arrow head).

The overall research findings of this study (**Figure 7**) proves that exercise (>3 times a week and >30 min each session or >90 min a week) lead to a statistical non-significant increase in testicular weight, increase in Leydig cells, increase in spermatogenesis and serum testosterone levels while mobile phone radiation (6 h/day × 30 days at 1.6 w/kg specific absorption rate) lead to a statistical non-significant decrease in testicular weight, decrease in Leydig cells, decrease in spermatogenesis and serum testosterone levels. The graph of mean testosterone (ng/dl) of the groups (**Figure 8**) shows an

increase in serum testosterone levels in the group that performed an exercise when compared to the control group while there was a decrease in serum testosterone levels in the group exposed to mobile phone radiation when compared to the control group. There was a slight decrease in the serum testosterone levels of the group exposed to both mobile phone radiation and exercise when compared to the control group. These findings prove that exercise leads to an increase in male fertility while mobile phone radiation leads to a decrease in male fertility.

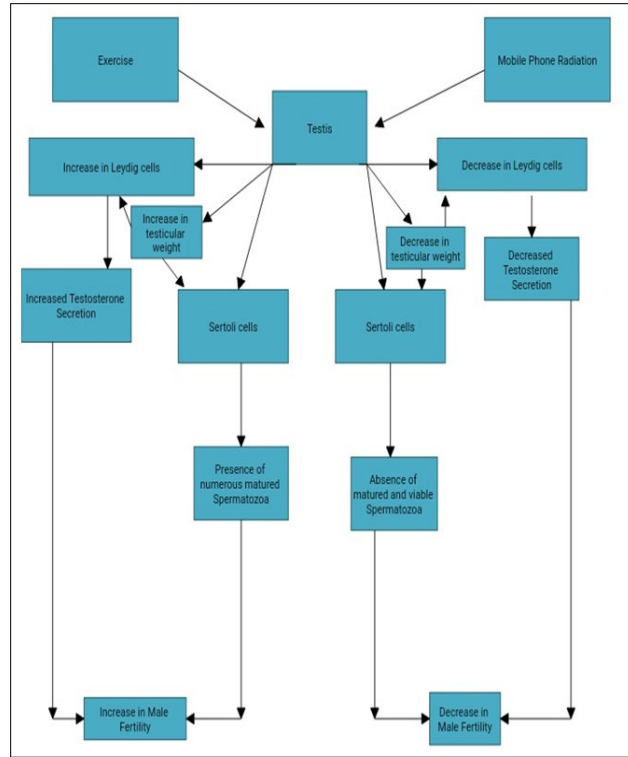


Figure 7. Schematic summary of the overall research findings.

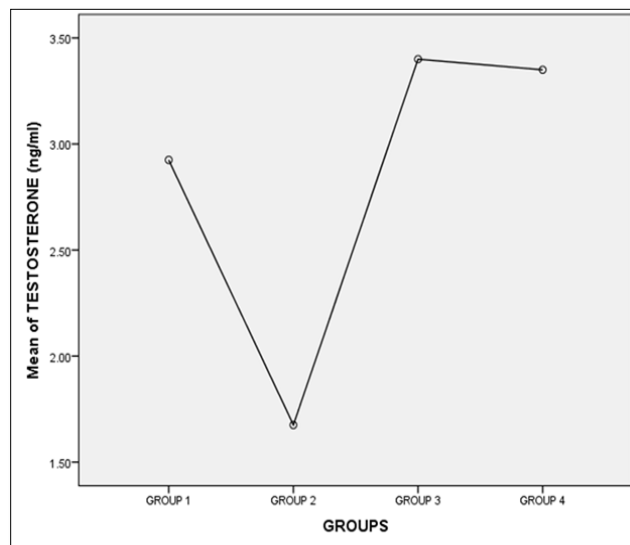


Figure 8. Mean of testosterone levels of the groups.

DISCUSSION

According to the results of this study, exposure of male wistar rats to mobile phone radiation 6 h daily for 30 days lead to a statistical decrease in serum testosterone levels which was non-significant ($p > 0.05$) when compared to the control group, but which might be significant if the duration of the experiment was extended beyond 30 days, this is nearly similar to the reports of Oyewopo et al. [10] stated

that mobile phone radiation caused a significant decrease in serum testosterone concentration. There was a statistical increase in serum testosterone levels in male rats subjected to exercise only but it was non-significant ($p > 0.05$) when compared to the control group, but which might be significant if the duration of the experiment was extended beyond one month, this is contrary to the findings of Hu et al. [11], they observed a significant reduction in testosterone levels in rats subjected to continuous swimming for 3 weeks.

Testosterone levels were restored to normal following 6 weeks of training, suggesting an adjustment to training on Luteinizing Hormone secretion in the endocrine system that was associated with negative feedback mechanism. However there was a slight statistical decrease in serum testosterone levels in male wistar rats exposed to mobile phone radiation and subjected to exercise when compared to the control group but it was non-significant ($p>0.05$).

Short term exposure of male wistar rats to electromagnetic field radiation emitted from a Nokia 1280 cell phone for 30 days cause a non-significant ($p>0.05$) decrease in testicular weight, Similarly Aminollah et al. [12] assessed the effects of EMF with an intensity of 1 mT 50 Hz on reproductive variables and sex hormones in male rats and found a non-significant decrease in testicular weight. Swimming for >3 times a week and >30 min each session or >90 min a week lead to a statistical non-significant increase ($p>0.05$) in the testicular weight of male wistar rats subjected to exercise when compared to the control group. However there was a significant increase ($p<0.05$) in testicular weight of the male rats exposed to mobile phone radiation and subjected to exercise when compared to the control group.

Microscopic changes such as reduction in mean seminiferous tubule diameter, vacuolar degeneration and desquamation of the seminiferous epithelium, maturation arrest in the spermatogenesis of the peripheral tubules, reduction in the number of Sertoli and Leydig cells were observed in the testis of the male rats exposed to mobile phone radiation this is similar to the findings of Cetkins et al. [13], Oh et al. [14], Forgacs et al. [15], Kesari et al. [16], Kesari et al. [17], Kesari et al. [18], Kumar et al. [19], Meo et al. [20], Ozguner et al. [21] and Salama et al. [22].

Microscopic changes such as full spermatogenic activity of the seminiferous epithelium cycle represented by spermatogonia, primary spermatocytes, secondary spermatocytes and spermatids as well as nutritive Sertoli cells were observed in the testis of rats subjected to exercise. However microscopic changes in the testis of rats in the test group exposed to mobile phone radiation and subjected to exercise show alterations in both the interstitial tissue and seminiferous tubules. The detachment between the adjacent seminiferous tubules was observed at several places and the number of Leydig cells at interstitial space was observed as decreased.

LIMITATIONS

The present study has limitations. The sample size was relatively small and the study was performed at a single institution. The duration of study was less; therefore there is need for further studies and long term research on the effects of mobile phone radiation and exercise on testicular functions which may likely have a significant effect on testicular function.

FUTURE DIRECTION AND RECOMMENDATION

Based on this animal study excessive use of mobile phone over a long period of time should be avoided because such effects are also expected in humans. Mobile phones should not be kept inside the pocket for a long period time due to its thermal effect and proximity to the testes. Use of hand-free materials and gadgets to limit direct contact of cell phones to the body, example is the Bluetooth ear-piece. Shield case or pulse should be encouraged by manufacturers. The cell phone should be used only where reception is good. The weaker the reception, the more the power the phone must use to transmit and the more power it uses the more radiation it emits and the deeper the dangerous radio waves penetrate into the body. Ideally, man should only use the phone with full bars and good reception. The damage from cell phone exposure will take many years to surface, and there are rarely any initial symptoms, just like cancer. Service providers and mobile phone manufacturers should provide research funds to tertiary and biomedical/biophysics research institutes worldwide to conduct research related to the effects of radio frequency radiation emitted by mobile phones in humans as a result of increased global use of mobile phones.

At least two hours and 30 min of moderate aerobic activity per week should be recommended as a therapy for Men with low testosterone levels, ageing males and men whose occupation is sedentary. Swimming at least three times a week over a long period of time can lead to an increase in male fertility.

CONCLUSION

The findings of this study indicated that Short term exposure of male wistar rats to mobile phone radiation (6 h/day \times 30 days at 1.6 w/kg specific absorption rates) lead to a statistical non-significant decrease in serum testosterone levels and testicular weight. Microscopic examination of the rat testis exposed to mobile phone radiation showed alterations in the seminiferous tubules of the testis, Inhibition of spermatogenesis, degeneration of Leydig cells, dilation and congestion of intertubular blood vessels. Exercise (>3 times a week and >30 min each session or >90 min a week) lead to a statistical non-significant increase in testosterone levels and testicular weight. Microscopic examination of the rat testis subjected to exercise showed full spermatogenic activity of the seminiferous epithelium cycle represented by spermatogonia, primary spermatocytes, secondary spermatocytes and spermatids as well as nutritive Sertoli cells was observed.

DECLARATIONS

Acknowledgement

Special thanks to Prof. Ed Nwobodo, Dr. Vincent Igbokwe, the academic and non-academic staff of the Department of

Human Physiology Nnamdi Azikiwe University for their contributions towards this project.

Funding

This study was funded by Mr. Okechukwu Chidiebere Emmanuel who picked interest in the study.

Availability of data and materials

All datasets, on which the conclusions of the manuscript rely on, are presented in the paper.

Author's contribution

Okechukwu Chidiebere Emmanuel designed the study plan, interpreted the data, did the final edition of the manuscript, helped in performing the experiments, gathered and collected the relevant data, wrote the manuscript draft, analyzed the data, interpreted the results of the experiments. The author read and approved the final manuscript.

Ethics approval and consent to participate

This study was approved by the Department of Human Physiology faculty of Basic Medical Science Nnamdi Azikiwe University, Nnewi Campus Anambra State Nigeria.

Consent for publication

The individual had signed the consent form for conducting this research project and use the obtained data in relevant publications.

Competing interest

The authors declared that he have no competing interests.

REFERENCES

- Guo YP, Li EZ, Zhang YJ, Wang AL (2017) Aerobic exercise improves spermatogenesis of male rats: Results of iTRAQ-based proteomic analysis of the testis tissue. *Zhonghua Nan Ke Xue* 23: 776-781.
- Baker JR, Bemben MG, Anderson MA, Bemben DA (2006) Effects on age on testosterone responses to resistance exercise and musculoskeletal variables in men. *J Strength Cond Res* 20: 874-881.
- Bell GJ, Syrotuik D, Martin TP, Burnham R, Quinney HA (2000) Effect of concurrent strength and endurance training on skeletal muscle properties and hormone concentrations in humans. *Eur J Appl Physiol* 81: 418-427.
- Dutra Goncalves G, Antunes Vieira N, Rodrigues Vieira H, Dias Valerio A, Eloisa Munhoz de Lion Siervo G, et al. (2017) Role of resistance physical exercise in preventing testicular damage caused by chronic ethanol consumption in UChB rats. *Microsc Res Tech* 80: 378-386.
- Brownlee KK, Moore AW, Hackney AC (2005) Relationship between circulating cortisol and testosterone: Influence of physical exercise. *J Sports Sci Med* 4: 76-83.
- Cadore EL, Brentano MA, Lhullier FLR, Krue LFM (2008a) Factors concerned with the testosterone and cortisol response to strength training. *Rev Bras Med Esporte* 14: 74-78.
- Cadore EL, Lhullier FLR, Brentano MA, Silva EM, Ambrosini MB, et al. (2008b) Hormonal responses to resistance exercise in long-term trained and untrained middle-aged men. *J Strength Cond Res* 22: 1617-1624.
- Cadore EL, Pinto RS, Lhullier FLR, Correa CS, Alberton CL, et al. (2010). Physiological effects of concurrent training in elderly men. *Int J Sports Med* 31: 689-697.
- Durand JR, Castracane VD, Hollander DB, Trynieck JL, Bamman MM, et al. (2003) Hormonal responses from concentric and eccentric muscle contractions during heavy resistance/power strength training in middle-aged and older men. *Med Sci Sports Exerc* 35: 937-943.
- Oyewopo AO, Olaniyi SK, Oyewopo CI, Jimoh AT (2017) Radiofrequency electromagnetic radiation from cell phone causes defective testicular function in male Wistar rats. *Andrologia* 49.
- Hu Y, Asano K, Mizuno K, Usuki S, Kawamura Y (1999) Serum testosterone responses to continuous and intermittent exercise training in male rats. *Int J Sports Med* 20: 12-16.
- Aminollah B, Maryam O, Amin T, Seyedeh MJ (2015) Low frequency electromagnetic fields long-term exposure effects on testicular histology, sperm quality and testosterone levels of male rats. *Asian Pac J Reprod* 4: 195-200.
- Cetkin M, Kizilkan N, Demirel C, Bozdog Z, Erkilic S, et al. (2017) Quantitative changes in testicular structure and function in rat exposed to mobile phone radiation. *Andrologia* 49.
- Oh JJ, Byun SS, Lee SE, Choe G, Hong SK (2018) Effect of electromagnetic waves from mobile phones on spermatogenesis in the era of 4G-LTE. *Biomed Res Int* 2018: 1-8.
- Forgacs Z, Somosy Z, Kubinyi G, Bakos J, Hudak A, et al. (2006). Effect of whole-body 1800 MHz GSM-like microwave exposure on testicular steroidogenesis and histology in mice. *Reprod Toxicol* 22: 111-117.
- Kesari KK, Behari J (2010) Microwave exposure affecting reproductive system in male rats. *Appl Biochem Biotechnol* 162: 416-428.

17. Kesari KK, Behari J (2012). Evidence for mobile phone radiation exposure effects on reproductive pattern of male rats: Role of ROS. *Electromagn Biol Med* 31: 213-222.
18. Kesari KK, Kumar S, Behari J (2011) Effects of radiofrequency electromagnetic wave exposure from cellular phones on the reproductive pattern in male Wistar rats. *Appl Biochem Biotechnol* 164: 546-559.
19. Kumar S, Behari J, Sisodia R (2013) Influence of electromagnetic Fields on reproductive system of male rats. *Int J Radiat Biol* 89: 147-154.
20. Meo SA, Al-Drees AM, Husain S (2010) Effect of mobile phone on serum testosterone in Wistar Albino rats. *Saudi Med J* 31: 869-873.
21. Ozguner M, Koyu A, Cesur G, Ural M, Ozguner F, et al. (2005) Biological and morphological effects on the reproductive organ of rats after exposure to electromagnetic field. *Saudi Med J* 26: 405-410.
22. Salama N, Kishimoto T, Kanayama HO (2010) Effects of exposure to a mobile phone on testicular function and structure in adult rabbit. *Int J Androl* 33: 88-94.