

## Effect of Magnetic Resonance Image Slice Thickness on Target Volume Determination in Radiotherapy

Mehmet Sinan Karabey<sup>1\*</sup>, Ayşegül Ünal Karabey<sup>2</sup>, Burcu Alparslan<sup>2</sup>, Eda Yirmibeşoğlu Erkal<sup>2</sup> and Görkem Aksu<sup>2</sup>

<sup>1</sup>Department of Radiation Oncology, VM Medical Park Kocaeli Hospital, Turkey

<sup>2</sup>Department of Radiation Oncology, Kocaeli University, Turkey

Received June 29, 2020; Accepted July 27, 2020; Published August 25, 2020

### ABSTRACT

To investigate the effect of slice thickness of magnetic resonance (MR) images to be used for fusion by computerized tomography (CT) in small target volumes planned for stereotactic radiotherapy (SRT).

**Materials & Methods:** MR images of 2- and 6-mm slice thickness were obtained using MR phantom. CT images obtained with a 2 mm slice thickness and AC MR phantom images were fused to determine target volumes. The volumes determined in 2 mm CT, 2 mm MR and 6 mm MR image fusions are 15.45 cc, 15.95cc, and 19.15 cc. Retrospectively, stereotactic radiotherapy treatment, 2-6mm slice MR images were fused and target volumes were compared. The mean tumor volume obtained in 2 mm thickness MR images is 5.02 cc and the tumor volume determined in fusion with 6mm thickness MR images is 5.27 cc.

**Conclusion:** The same slice thickness of CT and MR images used for planning in small target volumes in SRT planning is more appropriate in terms of maintaining healthy tissue and determining more accurate target volume.

**Keywords:** Small target volume, MR slice thickness, Planning tomography, SRT planning

### REVIEW

Computed tomography (CT) is the most widely used contouring and calculation tool in radiotherapy planning. The tomography provides information about the geometry of the region to be irradiated and the tissue electron density. With CT information, dose distribution can be calculated on the patient. CT data is converted to electron density per unit volume. This electron density information is used to calculate the dose to be used in radiotherapy [1,2].

Small density differences between target volume and soft tissues may create uncertainties in target volume determination.

Magnetic resonance imaging (MRI) is an important radiological imaging method used to show soft tissue lesions such as brain metastases, and in radiotherapy it is used to show the size, volume, shape and location of the target lesion. T1-weighted images are superior in anatomy and T2-weighted images are superior in indicating possible pathology [3].

The aim of the treatment of brain metastases is palliation. Long-term survival is expected in some patient groups. It is possible to treat the diseased area locally without damaging

the healthy tissues. Stereotactic radiotherapy is a form of treatment in which a high dose of X-ray is usually delivered to the small volume of the diseased area within strict accuracy. Complications in normal tissue can also occur with treatment transfer [4]. The goal of stereotactic radiotherapy for brain tumors is to fully treat the target tumor and not to damage healthy tissue. Therefore, it is important to clearly identify the diseased area [5].

Image fusion is the process of combining relevant information from the image series into a single image. Fusion is an important mechanism that ensures better quality of information in the image set. With image fusion, the target

**Corresponding author:** Mehmet Sinan Karabey, Department of Radiation Oncology, VM Medikal Park Kocaeli Hospital, Tel: +905552705165; E-mail: msinankarabey@yahoo.com

**Citation:** Karabey MS, Karabey AU, Alparslan B, Erkal EY & Aksu G. (2020) Effect of Magnetic Resonance Image Slice Thickness on Target Volume Determination in Radiotherapy. J Blood Transfusions Dis, 3(3): 168-172.

**Copyright:** ©2020 Karabey MS, Karabey AU, Alparslan B, Erkal EY & Aksu G. This is an open-access article distributed under the terms of the Creative Commons Attribution License, which permits unrestricted use, distribution, and reproduction in any medium, provided the original author and source are credited.

volume can be taken into a single modality. Different tissues can be determined more clearly using different imaging algorithms [6]. This is an important tool in determining the target volume position and size. Two different devices that capture images to be fused may use different algorithms [7,8].

In the studies, it was observed that the target tissue volume determined by using only CT images could not be determined exactly and the target tissue did not receive the therapeutic dose completely. Therefore, the margin to be determined for the planned target volume (PTV) is important [9,10].

The aim of this study was to determine the volume differences that would be caused by the use of MR images of different cross-sectional thickness in the fusion images that were created when determining target volumes in patients undergoing SRT for brain metastasis and to compare them with phantom images.

**MATERIAL & METHODS**

This study was approved by the institutional review committee of Kocaeli University.

**Phantom**

It is made of acrylic plastic, glass, silicone. Ferromagnetic materials were removed. It is 20.4 cm in diameter and 16.5 cm in length. There are 11 mm thickness resolution components. The width between the halls is 1.1 mm, 1 mm and 0.9 mm (Figure 1) [11]. Target volumes were determined on the phantom (Figure 2).



Figure 1. ACR MR Phantom.

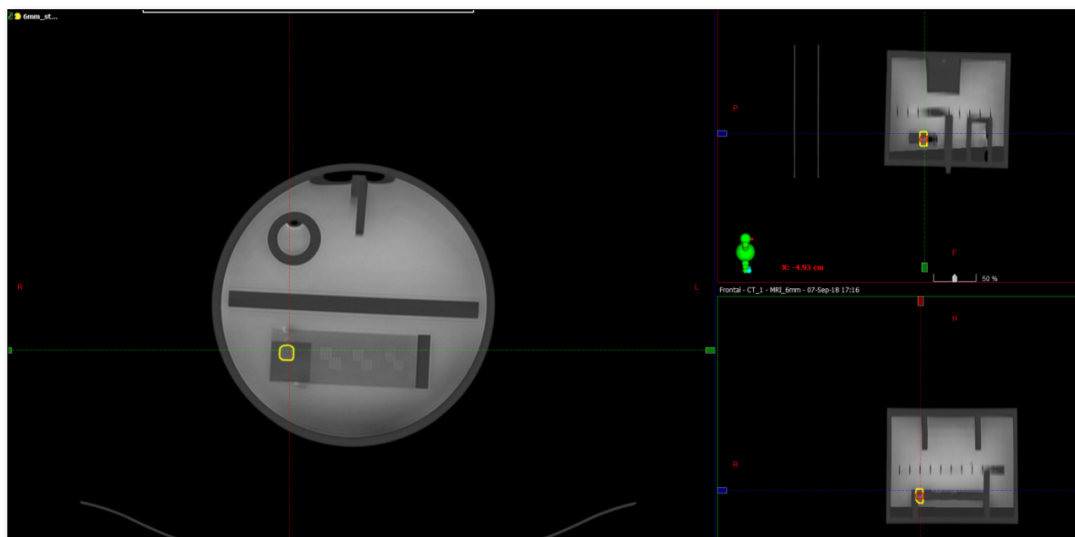


Figure 2. Deliniation of target volume on Phantom.

**MR Imaging**

MR scans were performed on Philips achieva 3.0T (TX) -DS (Philips Healthcare, Best, Netherlands). T1W contrast series were used for radiotherapy target volume determination. T2 weighted turbo spin echo axial series and T1 weighted inverse completion sagittal series were used. Scanning widths were determined as Fov 23cm AP, RL 23cm, FH 13.7. The gap between sections was set to 0 cm.

The patients included in the study had MR images of both 2 mm and 6 mm cross-sectional thickness. All images were transferred to Eclipse V13.6 treatment planning station.

**Image Fusion**

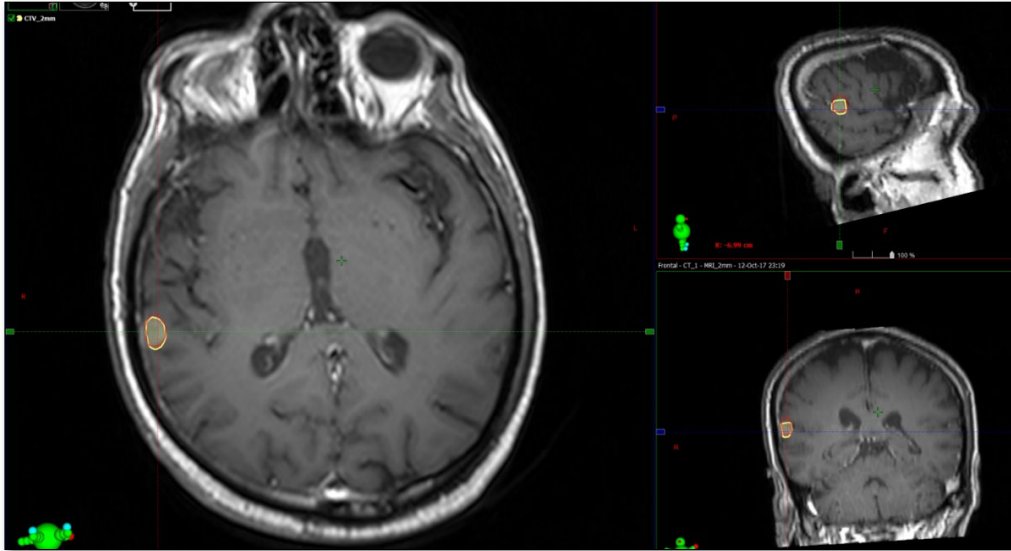
Simulation was performed with Siemens Somatom Definition (Siemens Healthcare, Erlangen, Germany) AS CT device with a cross-sectional thickness of 2 mm. All patients were immobilized with thermoplastic mask. CT and MR images were transferred to Eclipse 13.6 treatment planning system (TPS, Varian Medical Systems, Palo Alto CA). The images were combined with the automatic image registrar (Rigid registrations algorithm, V13.16).

**Determination of target volume**

The target volumes were determined on the MR image by combining MRI and CT images by the radiation oncologist (Figure 3). Ten target volumes from four different patients

were plotted on 2 mm and 6 mm fusion MR images separately. The data were analyzed by paired student t test.

The target volumes obtained are shown in **Table 1** and **Table 2**.



**Figure 3.** Determination of target volume on patient.

**Table 1.** Target volumes plotted on mr images with 2 mm and 6 mm cross-sectional spacing in ACRmr phantom.

Hedef Hacim	BT 2 mm(cc)	MR 2 mm(cc)	MR 6 mm(cc)
Big1	15,8	17,6	19,8
big2	44,4	44,4	53,5
Srt1	0,8	0,8	1,9
str2	0,8	1	1,4

**Table 2.** Target volumes determined on MR images with 2 mm-6 mm cross-sectional thickness.

Ctv	MR 2 mm(cc)	MR 6 mm(cc)
Ctv1	0,58	0,72
Ctv2	3,19	3,5
Ctv3	4,58	4,71
Ctv4	32,34	32,25
Ctv5	0,43	0,52
Ctv6	0,57	0,71
Ctv7	1,5	2,4
Ctv8	1,4	1,9
Ctv9	0,6	0,7

## RESULTS

In our study, we obtained MR images of MR phantom with 2 mm and 6 mm cross-sectional thickness. We compared CT images with 2 mm cross-sectional thickness to 4 different volumes. We evaluated 10 different target volumes from 4 patient imaging. We evaluated the 2 mm and 6 mm cross-sectional MR images and the target volumes obtained from 2 mm cross-sectional CT images volumetricly (**Table 1**).

In the obtained phantom data, there was no significant difference between the target volumes created by CT images with 2 mm cross-sectional thickness and the target volumes created by MR images with 2 mm and 6 mm cross-sectional thickness ( $p=0.17-0.08$ ). There was no significant difference between CTVs created from MR images of 6 mm and 2 mm slice thickness ( $p>0.05$ ). Target volumes determined by rigid fusion with MR images were evaluated (**Table 2**). There was a significant difference between the fusion images created with MR images with a cross-sectional thickness of 2 mm and 6 mm ( $p=0.018$ ).

## DISCUSSION

In this study, we aimed to investigate the effect of cross-sectional thickness of magnetic resonance (MR) images to be used for fusion by computerized tomography (CT) in small target volumes planned for stereotactic radiotherapy. Kenet et al. [12] in their multicenter study, they obtained MRI and CT images of the brain with a cross-sectional thickness of 2 and 2.5 mm and compared image fusion with CTV. They found that there was an error even between fusions and this error was significant in automatic registrations. They thought that it was difficult to prove the effect of MR and CT cross-sectional thickness on the accuracy of registrations, that the differences obtained were systematic and would not alter the results of the registrations, and that these uncertainties should be taken into account when determining PTV. On the other hand, Noda et al. [13] emphasize that if the cross-sectional thickness of the fusion CT and MR images is thin (0.6 mm), the target volumes are very close to each other. As the section thickness increases, the difference between the volumes increases [13]. Wendy et al. [14] examined the target volume change in the fusion of CT scans with T2-weighted MR of the same cross-sectional thickness. They found that the target volumes drawn by MR were smaller than CT. MRI is also an imaging method that minimizes inter-user contour change. Therefore, MR has an important role in target volume determination [14]. Schmidt et al. [15] stated that only the target volume contours drawn on CT images were smaller than the contours drawn only according to MR and this was due to the determination of the edematous region as the target volume in T2-weighted MRI. In the study performed by Tanak et al. [16] on prostate patients, they performed target volume determination on CT images of equivalent cross-sectional thickness with MR. In the present study, target volumes drawn using MR were found to be smaller than CT

images. They recommended MR-CT fusion, especially in small volumes.

## CONCLUSION

In patients undergoing brain stereotactic radiotherapy, target volume determination is important to prevent high doses of x-rays to the tumor and to preserve healthy tissues. In the irradiation of small volume lesions, the difference in volume caused by the cross-sectional thickness of CT and MR images to be fused was significant ( $p=0.018$ ). This difference decreases in large volume lesions. The same cross-sectional thickness of the MR and CT images used for fusion, especially in small volume irradiation in stereotactic radiotherapy, would be appropriate for the preservation of healthy tissues and for more accurate target volume determination. It is recommended that MR cross-section thicknesses obtained by planning tomography for the determination of the target volume determined based on the data obtained by fusion be the same for more accurate target volume determination. The number of samples should be increased in order to reach a final judgment.

## REFERENCES

- Villeirs GM, Verstraete KL, De Neve WF, De Meerleer GO (2005) Magnetic resonance imaging anatomy of the prostate and periprostatic area: A guide for radiotherapists. *Radiother Oncol* 76: 99-106.
- Jerry V, Battista J, Rider WD, Dyk JV (1980) Computed tomography for radiotherapy planning. *Int J Rad Oncol Biol Phys* 6: 99-107.
- Villeirs GM, Verstraete KL, De Neve WJ, De Meerleer GO (2007) Magnetic resonance imaging (MRI) anatomy of the prostate and application of MRI in radiotherapy planning. *Eur J Radiol* 63: 361-368.
- Nieder C, Anca L, Laurie G, Gaspar E (2014) Stereotactic radiosurgery (SRS) for brain metastases: A systematic review. *Rad Oncol* 9: 155.
- Işın A, Direkoğlu C, Şah M (2016) Review of MRI-based brain tumor image segmentation using deep learning methods. *Proc Comp Sci* 102: 317-324.
- Sahu DK, Parsai MP (2012) Different Image Fusion Techniques-A Critical Review. *IJMER* 2: 4298-4301.
- Wong A, Bishop W (2008) Efficient least squares fusion of MRI and CT images using a phase congruency model. *Patt Recogn Lett* 29: 173-180.
- Lin JS, Fuentes XDT, Chandler XA, Prabhu XSS, Weinberg XJS, et al. (2017) Schellingerhout. Performance Assessment for Brain MR Imaging Registration Methods. *AJNR* 38: 973-980.
- Fiorentino AR, Caivano P, Pedicini V, Fusco (2013) Clinical target volume definition for glioblastoma radiotherapy planning: Magnetic resonance imaging and

computed tomography. *Clin Transl Oncol* 15: 754-758.

10. Bagri PK, Kapoor A, Singh D, Singhal MK, Narayan S, et al. (2015) Addition of magnetic resonance imaging to computed tomography-based three-dimensional conformal radiotherapy planning for postoperative treatment of astrocytomas: Changes in tumor volume and isocenter shift. *South Asian J Cancer* 4: 18-20.
11. Clarke GD (1987) Overview of the MRI accreditation phantom. *MRI phantoms & QA testing*.
12. Ulin K, Urie MM, Cherlow JM (2010) Results of a multi-institutional benchmark test for cranial CT/MR image registration. *Int J Rad Oncol Biol Phys* 77: 1584-1589.
13. Noda C (2016) Toshiyuki Takahashi, Hisaya Sato, Yasuhiro Inose, Kyoichi Kato, Yasuo Nakazawa. Volumetry of the Liver: Effect of measurement using fusion images. *Arts Sci* 63: 763.
14. Wendy L (2007) Prostate volume contouring: A 3D analysis of segmentation using 3DTRUS, CT and MRI. *Int J Rad Oncol Biol Phys* 67: 1238-1247.
15. Schmidt MA, Payne GS (2015) Radiotherapy planning using MRI. *Phys Med Biol* 60: 323-361.
16. Tanaka H, Hayashi S, Ohtakara K, Hoshi H, Iida T (2011) Usefulness of CT-MRI fusion in radiotherapy planning for localized prostate cancer. *J Rad* 52: 782-788.