

## Intra-Articular Clodronate for Inflammatory Phase of Knee Osteoarthritis

Martin-Martin Luis Severino\*, De Lorenzo Chiara<sup>§</sup>, Ciocchi Giulia, Fabrizio Fabrizia Paola, Sperti Patrizia, Malizia Severino and Terracina David

\*Department of Internal Medicine, "S. Eugenio" Hospital (Rome-Italy), School of Medicine and Surgery, University of Rome "Tor Vergata" (Rome-Italy)

Received: January 25, 2020; Accepted February 12, 2020; Published July 26, 2020

### ABSTRACT

Knee osteoarthritis is one of the most prevalent musculoskeletal diseases affecting the elderly. Because it is characterized by the progressive degeneration of synovial joint structure, it causes pain, loss of motion and physical disability, thus impairing quality of life.

The purposes of symptomatic treatment of OA of the knee are to control joint pain and to improve joint function. The well-known pharmacological approach for symptomatic treatment includes oral administration of paracetamol, NSAIDs and opioids, but these therapies expose patients to risk of adverse events.

Here we present the therapeutic effects of intra articular clodronate in four patients with knee osteoarthritis. All patients showed an important improvement in pain VAS (mean 8.6 pre-therapy vs. 3.5 post-therapy). In addition, there has been a marked improvement in the signs of inflammation of the treated joints: Hyperthermia and swelling. Our therapeutic proposal would be to precede the injections of hyaluronic acid by 3-4 injections with intra-articular clodronate in order to exploit the exclusive anti-inflammatory effect of this bisphosphonate and thus reduce the amount of pro-inflammatory cytokines and of metalloproteases within the joint.

### INTRODUCTION

Osteoarthritis (OA) is considered to be the most common form of arthritis that results in structural and functional failure of synovial joints [1,2]. The current paradigm holds that OA is a disease of the entire joint, involving not only the degradation of articular cartilage but also an important subchondral bone reaction and alteration of other joint structures, including the synovial membrane, meniscus, capsule, ligaments and periarticular muscle. The clinical features of OA include joint pain with activity, transient stiffness in the morning or after rest, restricted motion, joint crepitus, periarticular tenderness, bony swelling and functional disability. The knee is regarded as one of the most common joints frequently affected by OA.

The purposes of symptomatic treatment of OA of the knee are to control joint pain and to improve joint function. The well-known pharmacological approach for symptomatic treatment includes oral administration of paracetamol, NSAIDs, opioids and intra-articular corticosteroid injections [3,4]. However, NSAIDs should be used with caution in patients with peptic ulcer disease, renal insufficiency, or cardiovascular risk [5,6]. Additionally, whereas opioids can be used for pain relief when NSAIDs have failed, their advantageous effects are outweighed by increased risk of adverse events and therefore should not be prescribed

routinely [7]. Intra-articular corticosteroid injections should be considered in patients who do not respond satisfactorily to the aforementioned treatments as well as in patients with acute exacerbations of pain and signs of local inflammation [8].

Macrophages might play a role in the development and progression of osteoarthritis (OA). Once activated, macrophages can produce large quantities of growth factors, enzymes and proinflammatory cytokines. It has previously been shown that macrophages enhance osteophyte growth in animal models of OA [9, 10]. Furthermore, it is possible that macrophages play a role in the maintenance and progression of the disease by their contribution to synovial fibrosis, cartilage catabolism and maintenance of an inflammatory

**Corresponding author:** Dr. Luis Severino Martin-Martin, Department of Internal Medicine, "S. Eugenio" Hospital (Rome -Italy), School of Medicine and Surgery, University of Rome "Tor Vergata" (Rome-Italy), Tel: 00393356200493; E-mail: severino.martin@gmail.com

**Citation:** Luis Severino MM, Chiara De L, Giulia C, Paola FF & Patrizia S, et al., (2020) Intra-Articular Clodronate for Inflammatory Phase of Knee Osteoarthritis. *J Rheumatol Res*, 2(2): 128-132.

**Copyright:** ©2020 Luis Severino MM, Chiara De L, Giulia C, Paola FF & Patrizia S, et al. This is an open-access article distributed under the terms of the Creative Commons Attribution License, which permits unrestricted use, distribution, and reproduction in any medium, provided the original author and source are credited.

state in the joint [11] by production of growth factors [12], enzymes [13] and cytokines, respectively [14,15].

Agents that suppress bone turnover, including bisphosphonates, have been associated with fewer subchondral bony lesions, as visualized by MRI, in patients with OA [16]. In several studies clodronate-laden liposomes were used for macrophage depletion. Clodronate-laden liposomes are selectively ingested by phagocytosing cells. After uptake, the clodronate is released, and subsequently, the cell undergoes apoptosis [17]. Seven days after injection of clodronate-laden liposomes, optimal depletion of macrophages is established [18]. Recently Rossini et al. [19] indicates that intra-articular clodronate provides symptomatic and functional improvements at least as good as those obtained with hyaluronic acid.

Here we present the therapeutic effects of intraarticular clodronate in four patients with knee osteoarthritis.

**PATIENTS AND METHODS**

Four patients never subjected to hyaluronic acid infiltrations (2 men and 2 women, men aged 68 years) were recruited. All of them showed a clinical picture of acute knee osteoarthritis, with severe pain, effusion and impaired function. Patients had undergone a knee MRI, which showed inflammation of subchondral bone and the typical “bone marrow lesions”.

Considering the clinical and radiological analogy with algodystrophy, we decided to treat patients with clodronate, but the intensity of pain reported by patients (mean VAS

pain 8.6) prompted us to use clodronate by intra-articular route of administration. Obtained the informed consent of the patients and given the excellent tolerability of this route of administration, as reported by previous studies [19], we adopted the following therapeutic scheme: Clodronate 25 mg intra-articular every week for 3 weeks; patients who still had a VAS of pain of more than 5 at week 7 underwent further administration of intra-articular Clodronate 25 mg.

All patients underwent a careful clinical examination before each single infiltration (weeks 1, 2 and 3) and at the last control visit (week 11). In order to identify any allergic reactions and/or signs of intra-periarticular infection they performed blood chemistry tests at week 1 and week 11 and performed an MRI of the infiltrated knee 11 weeks after the 1st infiltration with clodronate.

During the 11 weeks of the study, patients were asked not to modify therapy with NSAIDs and/or Paracetamol, which they were taking before starting infiltrative therapy with clodronate, without notifying their rheumatologist.

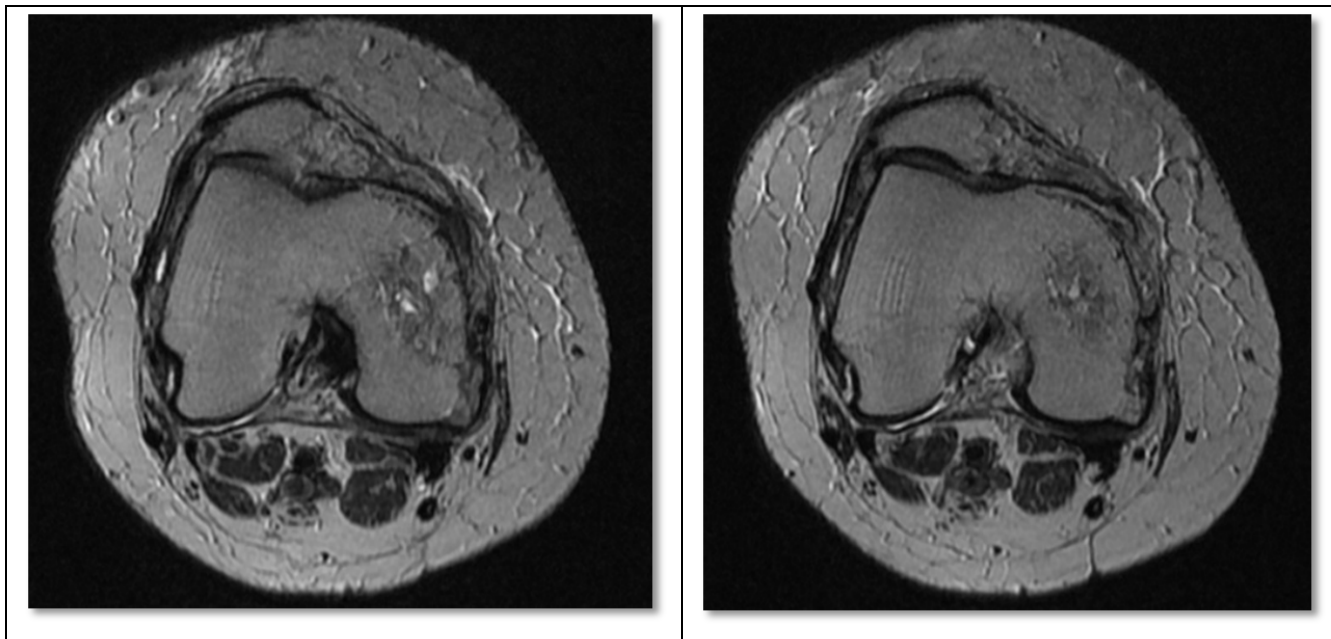
**RESULTS**

Of the four patients studied, only one needed further infiltration at week 11. The patient was a 69-year-old male, diabetic and obese.

All patients showed an important improvement in pain VAS (mean 8.6 pre-therapy vs 3.5 post-therapy; **Table 1**). In addition, there has been a marked improvement in the signs of inflammation of the treated joints: hyperthermia and swelling.

**Table 1.** Reduction of Pain VAS before and after intra articular clodronate therapy.

	VAS Pre-therapy	VAS post-therapy
<b>Patient 1</b>	8.4	3.3
<b>Patient 2</b>	8.2	3.2
<b>Patient 3</b>	8.7	3.7
<b>Patient 4</b>	9.1	3.8



**Figure 1.** Knee MRI before (left) and after (right) intraarticular clodronate therapy.

Patients did not report adverse events during the weeks of observation; joint and/or skin infections did not occur and liver and kidney function parameters did not change during the observation period. Two patients reported burning sensation during the infiltration, which resolved spontaneously after a few minutes, without requiring any medical intervention.

Three out of four patients showed a significant reduction in bone marrow edema encountered with MRI of the knee at the beginning of the observation (MRI knee of patient No. 2: Figure 1A before and Figure 1B after 11 weeks of observation). The fourth patient, for whom a 4th infiltration had become necessary at the 7th week, did not show important improvements in the radiological picture of bone marrow edema, although they presented a significant reduction in the pain VAS.

## DISCUSSION

Knee osteoarthritis is one of the most prevalent musculoskeletal diseases affecting the elderly. Because it is characterized by the progressive degeneration of synovial joint structure, it causes pain, loss of motion and physical disability, thus impairing quality of life. Current treatment strategies also aim to alleviate joint pain, reduce physical disability and limit the progression of joint damage [1,3]. In line with this concept, basic efforts to establish treatment guidelines often focus on treatment efficacy.

Furthermore, it is clear that multiple signaling molecules produced either by chondrocytes or by neighboring

fibroblasts or macrophages can also cause an activity response, as was recently shown by Blom and colleagues [20]. Cartilage disruption leads to leakage of large molecular complexes, such as collagens and proteoglycans, into the synovial fluid. MMP-3 is involved in the generation of severe cartilage damage in murine OA and synovial macrophages are crucial in early MMP-3 activity and appear to mediate MMP-3 production in synovium rather than cartilage [12].

In addition, clodronate plays an important role in the transmission of pain. Vesicular nucleotide transporter (VNUT/SLC17A9) carries ATP into secretory vesicles in a membrane potential  $Cl^-$ -dependent manner, is expressed in neurons at primary afferent nerve terminals and in the dorsal horn of the spinal cord and is responsible for vesicular storage and release of ATP. Experiments in VNUT knockout (KO) (VNUT $^{-/-}$ ) mice have revealed that VNUT in spinal dorsal horn neurons is involved in pain and that VNUT inhibition leads to improvement of pathological conditions with no significant changes in phenotype. Such findings suggest that VNUT inhibitors may be effective analgesic agents with few side effects, although therapeutic inhibitors of purinergic chemical transmission have yet to be developed. Clodronate was the strongest VNUT inhibitor among the bisphosphonates [21].

Numerous studies have found that clodronate inhibits the production of several pro-inflammatory mediators [22], inhibits the collagenase activity of MMP-1 [23] and reduces in vitro macrophage production of IL-1 $\beta$ , TNF  $\alpha$  and NO [24]. The physiopathogenetic mechanisms described so

far could explain the clear reduction in pain, swelling and hyperthermia that our patients treated with intra-articular clodronate presented; symptoms all started and worsened by the cytokines produced by macrophages.

There is no doubt the positive effect of intra-articular hyaluronic acid therapy on the integrity of the cartilage layer, but in patients in whom an inflammatory clinical picture prevails, the effect of intra-articular hyaluronic acid is reduced or requires a greater number of intra-articular injections. Evidently a high concentration of pro-inflammatory cytokines and metalloproteases increases the rate of degradation of the hyaluronic acid administered, reducing or even frustrating the therapeutic effect.

## CONCLUSION

Then, in patients with major joint inflammation, our therapeutic proposal would be to precede the injections of hyaluronic acid by 3-4 injections with intra-articular clodronate in order to exploit the exclusive anti-inflammatory effect of this bisphosphonate and thus reduce the amount of pro-inflammatory cytokines and of metalloproteases within the joint. In this way, a longer stability of hyaluronic acid could also be obtained, with greater permanence in the joint cavity and therefore greater therapeutic efficacy with significantly reduced costs compared to other therapies [25].

The experience of other authors [26] would seem to confirm our proposal for therapy, but further studies with a wider range of cases would be needed to confirm the goodness of our results.

## REFERENCES

1. Creamer P, Hochberg MC (1997) Osteoarthritis. *The Lancet* 350: 503-508.
2. Nuki G (1999) Osteoarthritis: A problem of joint failure. *Zeitschrift für Rheumatologie* 58: 142-147.
3. Hunter DJ, Felson DT (2006) Osteoarthritis. *BMJ* 332: 639-642.
4. BobaczK (2013) Pharmacologic treatment of hand-knee-and hip osteoarthritis. *Wien Med Wochenschr* 163: 236-242.
5. O'Neil CK, Hanlon JT, Marcum ZA (2012) Adverse effects of analgesics commonly used by older adults with osteoarthritis: Focus on non-opioid and opioid analgesics. *Am J Geriatr Pharmacother* 10: 331-342.
6. Trelle S, Reichenbach S, Wandel S (2011) Cardiovascular safety of non-steroidal anti-inflammatory drugs: Network metaanalysis. *BMJ* 342: 154.
7. Nuesch E, Rutjes AW, Husni E, Welch V, Juni P (2009) Oral or transdermal opioids for osteoarthritis of the knee or hip. *Cochrane Database Syst Rev* 17.
8. Bellamy N, Campbell J, Robinson V, Gee T, Bourne R, et al. (2005) Intra articular corticosteroid for treatment of osteoarthritis of the knee. *Cochrane Database Syst Rev* 19.
9. Blom AB, van Lent PL, Holthuysen AE, van der Kraan PM, Roth J, et al. (2004) Synovial lining macrophages mediate osteophyte formation during experimental osteoarthritis. *Osteoarthritis Cartilage* 12: 627-635.
10. Van Lent PL, Blom AB, van der Kraan P, Holthuysen AE, Vitters E, et al. (2004) Crucial role of synovial lining macrophages in the promotion of transforming growth factor-mediated osteophyte formation. *Arthritis Rheum* 50: 103-111.
11. Bondeson J, Wainwright SD, Lauder S, Amos N, Hughes CE (2006) The role of synovial macrophages and macrophage-produced cytokines in driving aggrecanases, matrix metalloproteinases and other destructive and inflammatory responses in osteoarthritis. *Arthritis Res Ther* 8: R187.
12. Davidson ENB, Vitters EL, Mooren FM, Oliver N, van den Berg WB, et al. (2006) Connective tissue growth factor/CCN2 overexpression in mouse synovial lining results in transient fibrosis and cartilage damage. *Arthritis Rheum* 54: 1653-1661.
13. Blom AB, van Lent PL, Libregts S, Holthuysen AE, van der Kraan PM, et al. (2007) Crucial role of macrophages in matrix metalloproteinase-mediated cartilage destruction during experimental osteoarthritis: Involvement of matrix metalloproteinase 3. *Arthritis Rheum* 56: 147-157.
14. Haynes MK, Hume EL, Smith JB (2002) Phenotypic characterization of inflammatory cells from osteoarthritic synovium and synovial fluids. *Clin Immunol* 105: 315-325.
15. Sakkas LI, Johanson NA, Scanzello CR, Platsoucas CD (1998) Interleukin-12 is expressed by infiltrating macrophages and synovial lining cells in rheumatoid arthritis and osteoarthritis. *Cell Immunol* 188: 105-110.
16. Carbone LD, Nevitt MC, Wildy K (2004) The relationship of antiresorptive drug use to structural findings and symptoms of knee osteoarthritis. *Arthritis Rheum* 50: 3516-3525.
17. Rooijen NV, Sanders A (1994) Liposome mediated depletion of macrophages: Mechanism of action, preparation of liposomes and applications. *J Immunol Methods* 174: 83-93.

18. Lent PLV, van den Bersselaar L, van den Hoek AE, van de Ende M, Dijkstra CD, et al. (1993) Reversible depletion of synovial lining cells after intra-articular treatment with liposome-encapsulated dichloromethylene diphosphonate. *Rheumatol Int* 13: 21-30.
19. Rossini M, Viapiana O, Ramonda R (2009) Intra-articular clodronate for the treatment of knee osteoarthritis: Dose ranging study vs hyaluronic acid. *Rheumatology (Oxford)* 48: 773-778.
20. Blom AB, Brockbank SM, van Lent PL, van Beuningen HM, Geurts J, et al. (2009) Involvement of the Wnt signaling pathway in experimental and human osteoarthritis: Prominent role of Wnt-induced signaling protein1. *Arthritis Rheum* 60: 501-512.
21. Maruyama K, Takayama Y, Sugisawa E, Nomura M, Akira S (2018) The ATP Transporter VNUT mediates induction of Dectin-1-Triggered Candida Nociception. *iScience* 6: 306-318.
22. Teronen O, Konttinen YT, Lindqvist C, Salo T, Ingman T, et al. (1997) Inhibition of matrix metalloproteinase-1 by dichloromethylene bisphosphonate (clodronate). *Calcif Tissue Int* 61: 59-61.
23. Makkonen N, Salminen A, Rogers MJ, Frith JC, Urtti A, et al. (1999) Contrasting effects of alendronate and clodronate on RAW 264 macrophages: The role of a bisphosphonate metabolite. *Eur J Pharm Sci* 8: 109-118.
24. Corrado A, Cantatore FP (2005) The bisphosphonates: Chemical characteristics, skeletal biological effects and extra skeletal effects. *Reumatismo* 57: 142-153.
25. Kristjansson B, Honsawek S (2014) Current perspectives in mesenchymal stem cell therapies for osteoarthritis. *Stem Cells Int* 2014: 1-13.
26. Palmieri B, Rottigni V, Iannitti T (2013) Preliminary study of highly cross-linked hyaluronic acid-based combination therapy for management of knee osteoarthritis-related pain. *Drug Des Devel Ther* 7: 7-12.