

Management Challenges in Rare Congenital Scalp Arteriovenous Malformation: A Case Report

Monika Hooda¹, Nitin Yadav², Brijesh Kumar^{1*}, Priyanka Shokeen¹ and Bhawna Singhal¹

¹Department of Pediatrics, Indira Gandhi Hospital, Dwarka, New Delhi, India

²Department of Radiodiagnosis, Janakpuri Super Specialty Hospital, Janakpuri, New Delhi, India.

Received April 18, 2024; Revised April 22, 2024; Accepted April 23, 2024

ABSTRACT

An extremely rare case of congenital scalp arteriovenous malformation (AVM) was diagnosed at Indira Gandhi Hospital, Dwarka in early infancy. Managing such cases is challenging due to their unpredictable course and concerns regarding possible associated intracranial communications. Selective angiography is essential for accurate diagnosis. The nature and future course of scalp AVM remains unclear, highlighting its unique and elusive characteristics. Our case underscores the importance of early detection, differentiation from common soft tissue tumors like hemangioma, and ruling out serious underlying vascular malformations. It underscores the need for vigilant monitoring and careful follow-up to optimize patient outcomes and alleviate parental concerns. This report sheds light on the complexities of managing congenital scalp AVM.

Keywords: Congenital, Scalp arteriovenous malformation, Intracranial communication, Selective angiography, Early detection, Vascular malformations, Vigilant monitoring, Comprehensive care

INTRODUCTION

Congenital scalp arteriovenous malformations (AVMs) in neonates and early infancy are rare vascular anomalies characterized by abnormal connections between arteries and veins [1]. These lesions present unique challenges due to their complex vascular anatomy and despite their rarity, require careful clinical evaluation and management to prevent potential complications and rule out possible associated intracranial communications.

These lesions like in this infant are often mistaken for other common soft tissue tumors like dermoid cyst and hemangiomas as birthmarks. While some lesions remain indolent or grow slowly, others exhibit aggressive growth patterns during adolescence. The precise course of these lesions remains uncertain, highlighting the need for further research in this area.

Management strategies may include careful watch, surgical intervention, endovascular embolization, or a combination of both depending on various factors such as lesion size, location, and associated symptoms [2]. Being present superficially against hard bony surface makes them prone to severe bleeding following blunt head trauma.

In this case report, we present an infant with a scalp AVM, emphasizing the clinical presentation and highlight the challenges associated with their diagnosis. Increased

awareness of these vascular anomalies and their potential complications is essential for prompt and effective management in pediatric patients.

CASE PRESENTATION

A two-and-a-half-month-old male infant presented with a small scalp swelling located on the right side above the right ear, in the prominent parietal region. The swelling was noticed by the parents twenty days after birth and was characterized by a slight increase in size without pain or tenderness on palpation. There was no history of trauma during delivery or afterward, and the infant had an unremarkable perinatal course following regular antenatal care. He was born via normal vaginal delivery, first order, with a birth weight of 2.58 kg and was exclusively breastfed, achieving normal growth and development. Family history

Corresponding author: Brijesh Kumar, MBBS, DCH, MD, CMO(SAG), Department of Pediatrics, Indira Gandhi Hospital, Dwarka, New Delhi, India, Tel: 9868008494; E-mail: drbk1959@gmail.com

Citation: Hooda M, Yadav N, Kumar B, Shokeen P & Singhal B. (2024) Management Challenges in Rare Congenital Scalp Arteriovenous Malformation: A Case Report. Int J Surg Invasive Procedures, 7(1): 252-260.

Copyright: ©2024 Hooda M, Yadav N, Kumar B, Shokeen P & Singhal B. This is an open-access article distributed under the terms of the Creative Commons Attribution License, which permits unrestricted use, distribution, and reproduction in any medium, provided the original author and source are credited.

was negative for significant diseases. The parents were concerned about the potential impact of the swelling on the

underlying brain, its nature, future course, and its impact on the infant's future well-being (**Figure 1**).

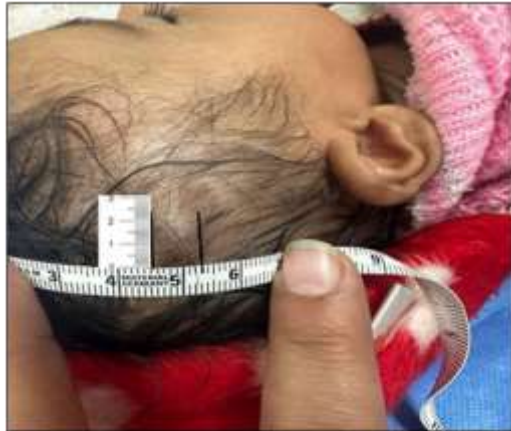

Figure 1. A small scalp swelling located on the right side above the right ear, in the prominent parietal region.

On examination, the swelling was well-demarcated, approximately 24mm × 8mm in size, slightly raised and globular shape. The overlying skin appeared normal in color, with no signs of ulceration. The swelling was soft, mobile, not adherent to underlying structure, non-tender and pulsatile, without audible bruits. Vital signs were within normal limits, and systemic examination revealed no abnormalities.

INVESTIGATIONS

Further evaluation was pursued to address concerns of intracranial extension/association, prompting scheduling of an MR Angiogram. Results revealed a prominent extracranial enhancing curvilinear vascular structure in the right parietal region, fed by the superficial temporal artery, with no intracranial extension (**Figures 2a-2c**).

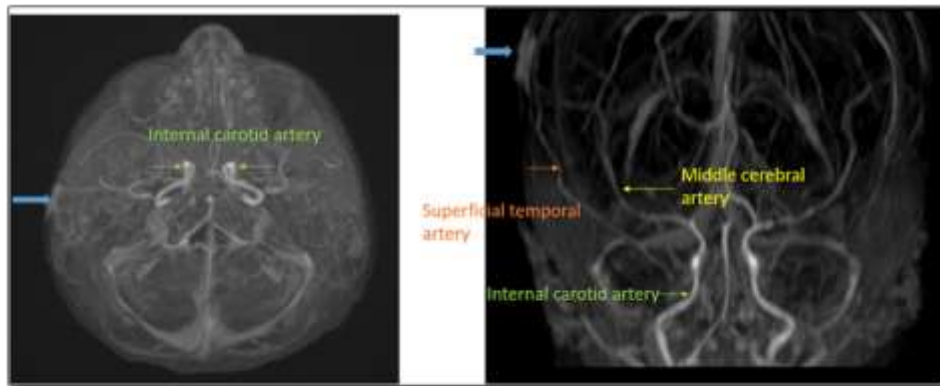


Figure 2a. 3D TOF angiography MIP axial and coronal images showing tuft of vessels in scalp on right side.

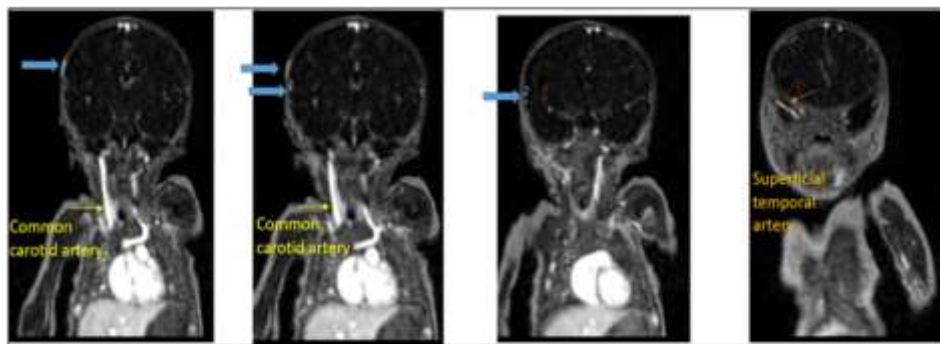


Figure 2b. Sequential T1 post contrast angiography images showing enhancing vessels within scalp swelling on right side, draining into superficial branches of external carotid artery.

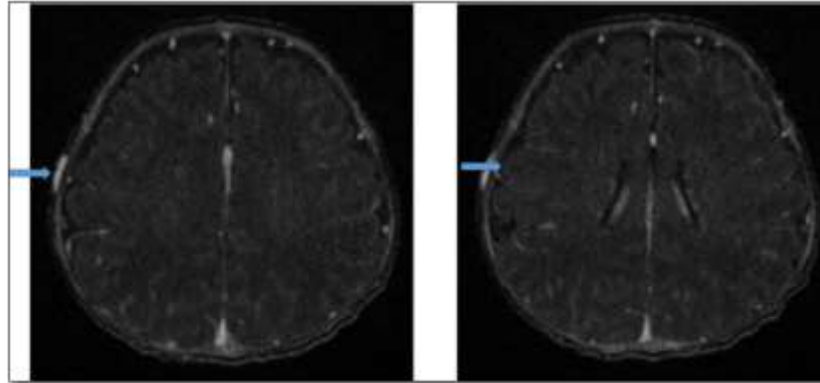


Figure 2c. TOF MR Angiography Axial images showing hyper intense tuft of vessels in scalp on right side.

To confirm its arterial origin, Doppler Ultrasound was conducted. The imaging revealed a hypoechoic lesion measuring 8*3 mm, with Doppler imaging indicating prominent arterial and venous channels within the lesion, along with demonstrable flow. Notably, aliasing between

arterial and venous channels within the lesion suggested an AVM. Additionally, the arterial and venous channels appeared to drain into the scalp vein, confirming the diagnosis of a scalp AVM (**Figure 3a-3e**).

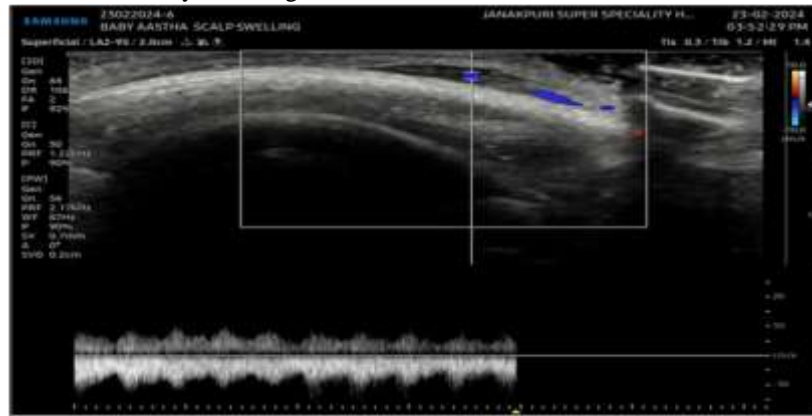


Figure 3a. Vascular channel within the lesion demonstrates pulsatile venous flow on color Doppler.

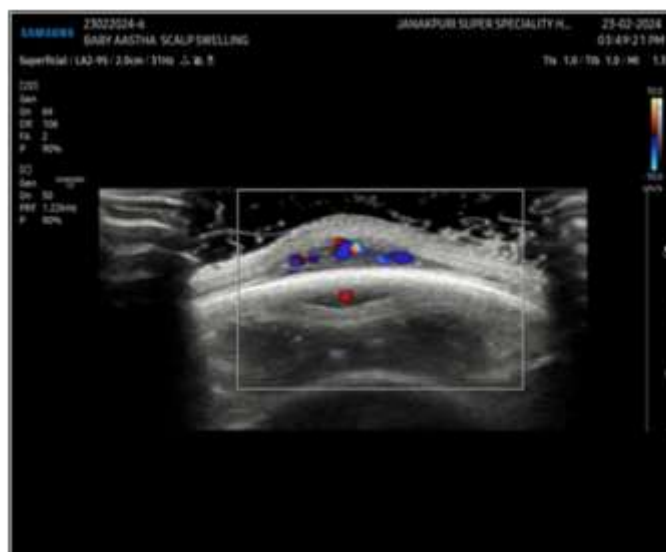

Figure 3b. Site of aliasing in vascular channels within the lesion suggestive of AVF.

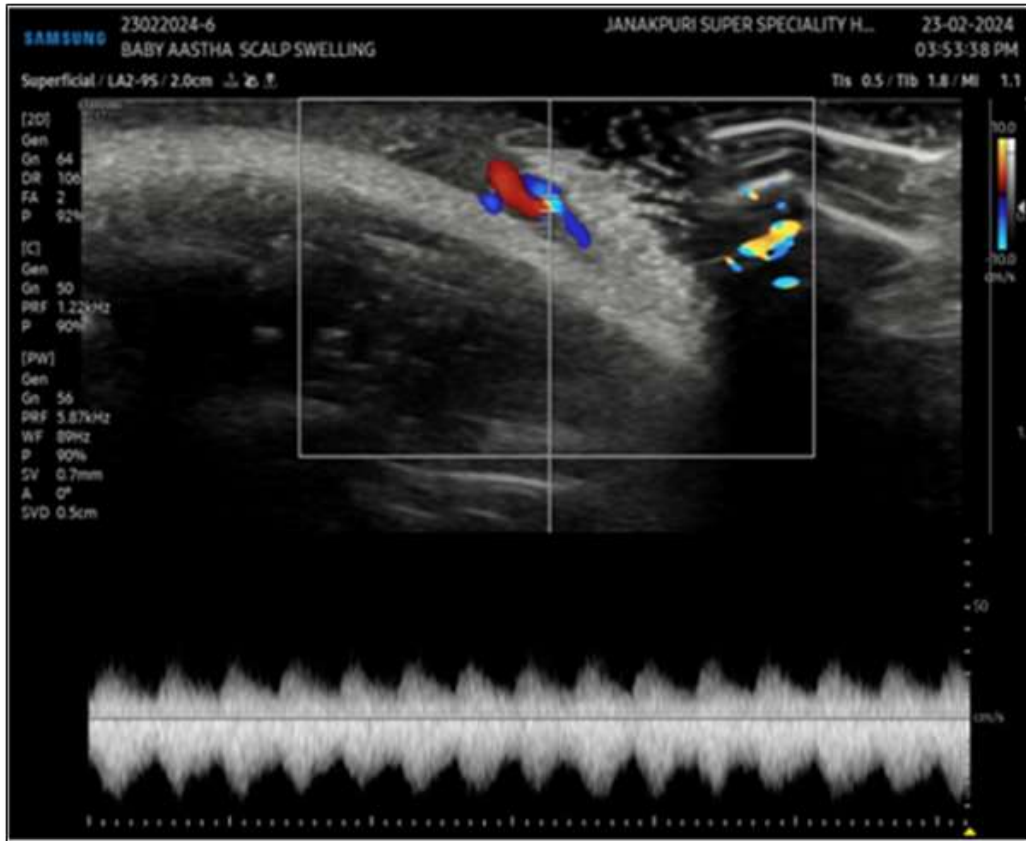


Figure 3c. Demonstration of flow across the site of aliasing within the lesion.

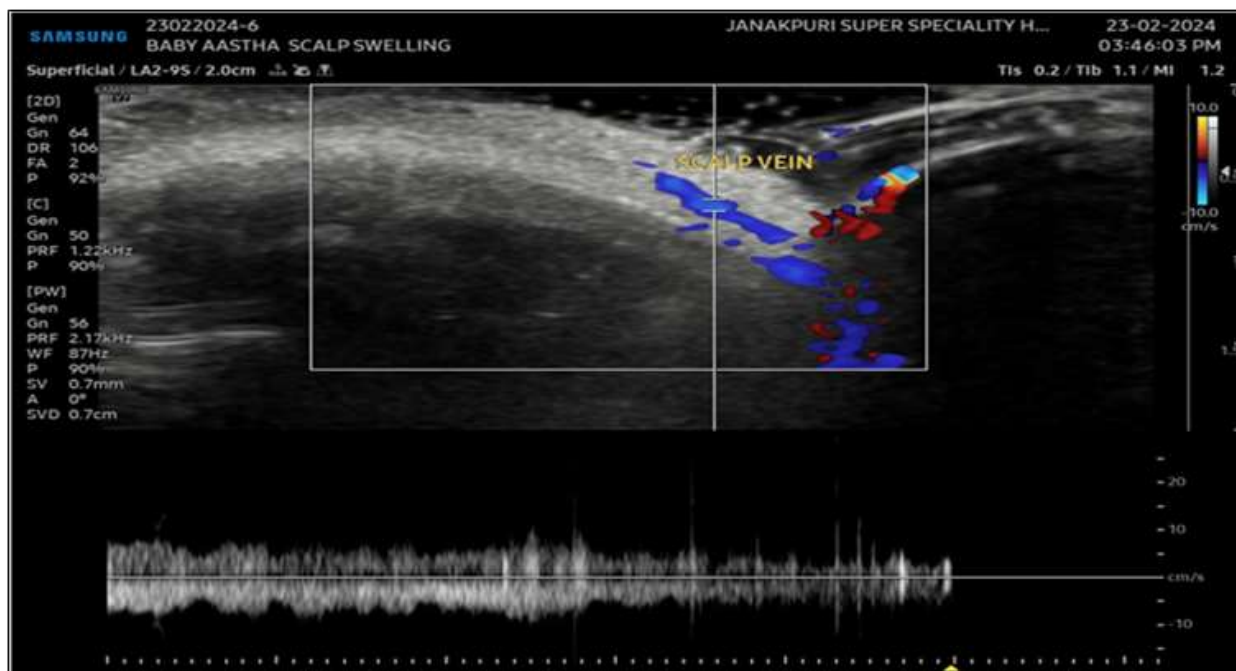


Figure 3d. Drainage of the lesion in a superficial scalp vein.

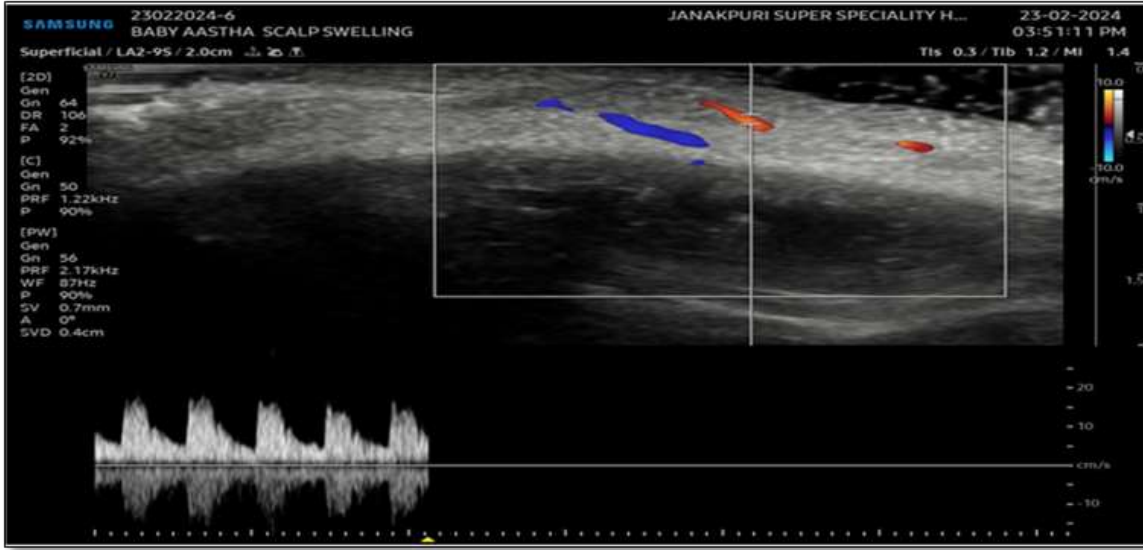


Figure 3e. Arterial supply to the lesion from a superficial scalp artery.

Given these findings, a decision was made for careful watch and vigilant monitoring, with instructions to avoid trauma. Subsequent follow-up assessments showed no increase in the size of the swelling, leading to the decision to continue with careful watch and vigilant monitoring.

DISCUSSION

Congenital Scalp Arteriovenous malformations (AVMs) are characterized by absent capillary beds, resulting in direct shunting of blood from arteries to veins through a fistula or nidus [3-5] (Figure 4).



Figure 4. Pictorial representation of AV malformation.

Scalp arteriovenous fistulas (AVMs) present unique challenges in both diagnosis and management due to their rarity and varied clinical presentations. Clinical manifestations may include small innocuous soft tissue swelling as in this infant. Progressive lesion may present with disfigurement, tissue destruction, pain, and bleeding.

Scalp arteriovenous fistulas (AVMs) and related vascular anomalies must be distinguished from other conditions presenting with scalp lesions. A few important differential diagnoses to consider include [6].

Dermoid Cyst

Dermoid cysts are benign inclusion cysts resulting from trapped skin elements beneath the scalp. They typically present as painless, firm, non-mobile lumps and may grow slowly over time. Dermoid cysts can be differentiated from AVFs based on imaging characteristics and absence of pulsations or hemodynamic changes (Figure 5).

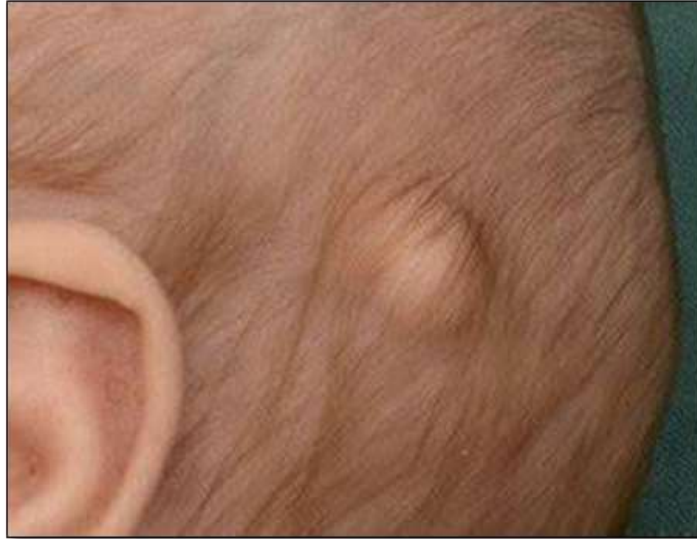

Figure 5. Dermoid cyst.

Hemangioma

Small hemangiomas are common vascular growths in infants and may involve the scalp. They often present as rapidly growing lesions in the first few weeks of life and then resolve spontaneously. Unlike AVMs, hemangiomas do not

typically present with pulsatile masses or significant shunting of blood flow. Imaging studies and clinical evaluation can aid in distinguishing between hemangiomas and AVFs (Figure 6).

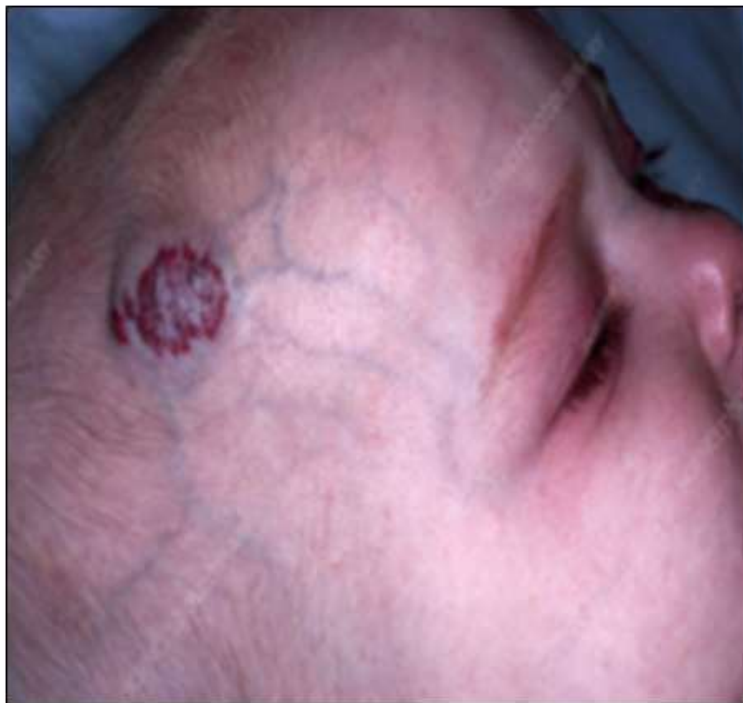

Figure 6. Hemangioma.

Another important consideration in the differential diagnosis of scalp lesions is the possibility of a delayed subaponeurotic fluid collection. This condition typically occurs following

trauma to the scalp, such as during childbirth, and involves the accumulation of blood and fluid beneath the scalp's aponeurosis layer (Figure 7).

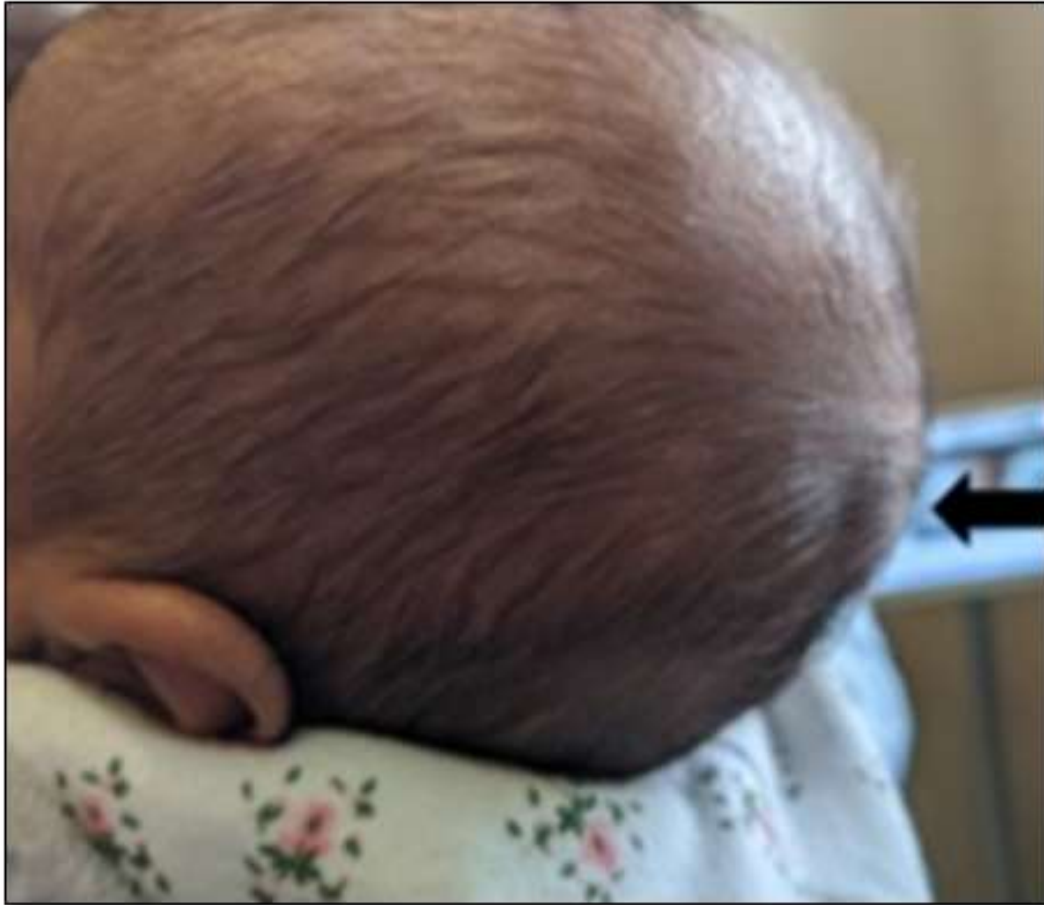

Figure 7. Subaponeurotic fluid collection.

Indeed, careful palpation of soft tissue swellings on the scalp is crucial in narrowing down the differential diagnosis, particularly when considering arteriovenous malformations (AVMs). While pulsations may be present in AVMs, they can sometimes be subtle and easily missed if not thoroughly evaluated. It is essential to note that pulsations may be absent or difficult to appreciate in certain cases, emphasizing the need for a comprehensive evaluation that includes other clinical findings and diagnostic modalities. Identifying pulsations on palpation can be challenging, particularly in cases where the lesion is small or deep-seated. In such instances, additional diagnostic tools such as imaging studies (ultrasound, MRI, Angiography) may be supportive; however, Angiography (CT/MR Angiography) and DSA is essential if there is plan for intervention in terms of surgery / embolization.

Imaging modalities such as ultrasound and MRI are pivotal in confirming the diagnosis, delineating vascular anatomy, and assessing the extent of involvement. In our case, the absence of intracranial communication signifies an isolated extracranial AVF, reducing the risk of intracranial hemorrhage. Doppler examination and MRI are crucial for

diagnosis and assessment, while cerebral angiography remains the gold standard [7]. Angiography is essential for diagnosis, while management involves a multidisciplinary approach, considering cosmetic concerns, prevention of bleeding, and symptom relief. Surgical excision remains the mainstay treatment, with careful attention to complete ligation of feeding arteries to prevent recurrence.

Diagnosis and management of Scalp Arteriovenous Fistulas (AVMs) require careful consideration of differential diagnoses and an understanding of the anatomical and functional aspects of the superficial temporal artery (STA) and its associated venous drainage.

The STA and STV are common vessels involved in scalp AVMs, STA, a major external carotid artery branch, supplies blood to the scalp via various branches, including the middle temporal artery [8]. Venous drainage occurs through superficial veins, including the superficial temporal vein (STV), draining into the external jugular vein. In scalp AVFs, abnormal arteriovenous connections lead to increased blood flow and venous pressure, causing vein dilatation and visible pulsations (**Figure 8**).

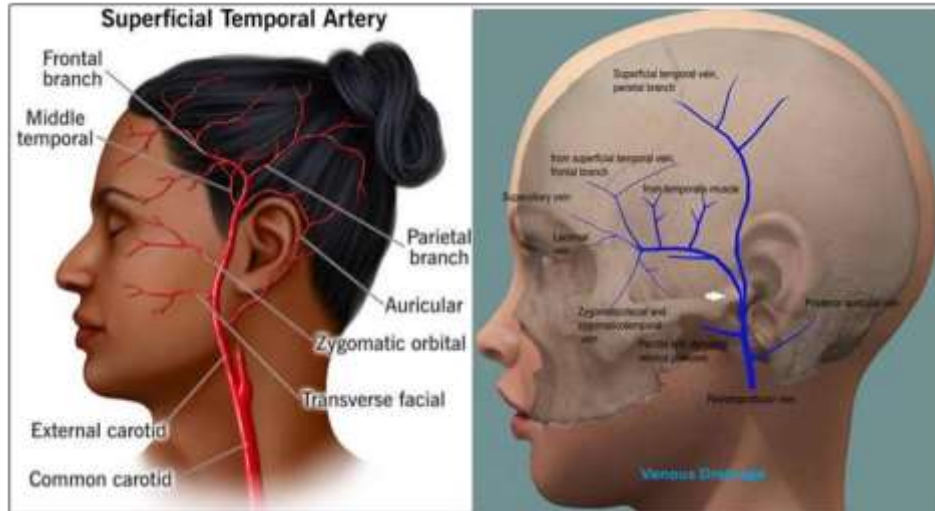


Figure 8. Pictorial representation of external carotid artery and branches and external carotid vein and tributaries.

In scalp AVFs, careful evaluation of STA and venous drainage is pivotal. Imaging modalities aid in delineating anatomy, guiding interventions targeting feeder arteries, including STA branches. Surgical or endovascular interventions aim to disrupt abnormal connections while preserving surrounding vasculature. Management strategies vary based on lesion characteristics and interdisciplinary collaboration, emphasizing the importance of tailored approaches for optimal outcomes.

The STA is indeed a major arterial supply to the scalp and may contribute to the blood flow in many scalp AVMs [8]. Its branches, including the frontal and parietal branches, can be implicated in feeding these lesions. Similarly, the STV is a significant vein in the scalp and is often involved in draining blood from these malformations.

However, scalp AVMs can also receive blood supply from other arteries, such as the occipital artery, posterior auricular artery, or branches of the internal carotid artery. Additionally, venous drainage can occur through various routes, including other superficial scalp veins and sometimes communicating veins connecting with deeper venous structures.

Therefore, while the STA and STV play crucial roles in many cases of scalp AVMs, it's essential to recognize that the arterial feeders and venous drainage patterns can vary widely among different patients and lesions. A comprehensive evaluation, including imaging studies like angiography, is necessary to assess the specific vascular anatomy of each individual case and guide appropriate management strategies. Congenital AVMs can have diverse arterial feeders and venous drainage patterns depending on individual variations and anatomical factors.

While the STA and STV are frequently implicated in scalp AVMs, it's crucial to recognize the potential variability in

the vascular anatomy of these lesions. A comprehensive evaluation, often including imaging studies such as angiography, is necessary to assess the specific arterial feeders and venous drainage patterns in each case. This individualized approach ensures accurate diagnosis and guides appropriate treatment strategies tailored to the patient's unique vascular anatomy.

Surgical or endovascular interventions targeting the feeder arteries, including branches of the STA, aim to disrupt the abnormal arteriovenous connections and restore normal vascular dynamics. Preservation of the surrounding vasculature, including the STA and its branches, is crucial to prevent ischemic complications and ensure adequate perfusion of the scalp tissues.

In summary, the STA and its venous drainage play a pivotal role in the pathophysiology and management of scalp AVFs. Understanding their anatomy and function is essential in diagnosing, evaluating, and treating vascular abnormalities in this region, ultimately optimizing patient outcomes and minimizing complications.

Management strategies for scalp AVMs are multifaceted and dependent on factors such as lesion size, location, symptoms, and associated complications. Conservative management with close monitoring may suffice for small lesions without significant symptoms. However, intervention, including embolization or surgical excision, should be considered based on clinical judgment and interdisciplinary collaboration.

CONCLUSION

This case report underscores the significance of early detection, precise diagnosis, and vigilant monitoring in enhancing patient outcomes and addressing parental concerns. Through the utilization of imaging techniques

such as MR Angiogram and Doppler Ultrasound, the diagnosis of Congenital scalp AVM was confirmed; excluded intracranial extension, and initiated a plan of careful observation and vigilant monitoring.

Given the potential for mimicry with conditions like dermoid cysts and hemangiomas, accurate differential diagnosis of scalp lesions is paramount. Understanding the anatomical and functional aspects of arterial feeders, notably the superficial temporal artery (STA), and venous drainage patterns is crucial for guiding treatment strategies, whether through surgical excision or endovascular interventions.

While the trajectory of scalp AVMs remains uncertain, proactive monitoring and timely intervention, if necessary, are imperative in averting complications such as bleeding and tissue damage.

In summary, this case report adds to the existing literature on rare congenital scalp AVMs, highlighting the intricacies of diagnosis and management. By sharing our experience, we aim to foster comprehension, facilitate early intervention, and ultimately optimize care for pediatric patients grappling with rare vascular anomalies of the scalp.

REFERENCES

1. Jennifer JM, John BM (2005) Current management of hemangiomas and vascular malformation. *Clin Plasti Surg* 32: 99-116.
2. Richling B, Killer M, Al-Schameri AR, Ritter L, Agic R, et al. (2006) Therapy of brain arteriovenous malformations: Multimodality treatment from a balanced standpoint. *Neurosurgery* 59(suppl 3): S148-S157.
3. Halim AX, Johnston SC, Singh V, McCulloch CE, Bennett JP, et al. (2004) Longitudinal risk of intracranial hemorrhage in patients with arteriovenous malformation of the brain within a defined population. *Stroke* 35: 1697-1702.
4. Shovlin CL, Jackson JE, Bamford KB, Jenkins IH, Benjamin AR, et al. (2008) Primary determinants of ischemic stroke/brain abscess risks are independent of severity of pulmonary arteriovenous malformations in hereditary hemorrhagic telangiectasia. *Thorax* 63: 259-266.
5. Fleetwood IG, Steinberg GK (2002) Arteriovenous malformations. *Lancet* 359: 863-873.
6. <https://www.jaypeedigital.com/eReader/chapter/9789350909829/ch1>
7. Gaillard F, Ghannouchi H, Machang'a K (2024) Brain arteriovenous malformation. Accessed on: April 08, 2024. Reference article: Radiopaedia.org
8. Yonenaga K, Tohnai I, Mitsudo K, Mori Y, Saijo H, et al. (2011) Anatomical study of the external carotid

artery and its branches for administration of super selective intra-arterial chemotherapy via the superficial temporal artery. *Int J Clin Oncol* 16: 654-659.