

## Primary Umbilical Endometriosis Masquerading as a Painful Umbilical Nodule: A Case Report

Ningi AB<sup>1</sup> and Jabbo M<sup>2\*</sup>

<sup>1</sup>Department of Surgery, Abubakar Tafawa Balewa University Teaching Hospital Bauchi-Nigeria

<sup>2</sup>Department of Obstetrics and Gynaecology, Nigeria Airforce Referral Hospital, Bauchi-Nigeria.

Received September 24, 2022; Revised HSHPHU□□ Accepted HSHPHU□

### ABSTRACT

**Background:** Endometriosis is the presence of endometrial tissue outside the uterine cavity. Although the pelvis is the most common site of occurrence, extra pelvic areas like the umbilicus are also reported. Primary Umbilical Endometriosis is very rare; the reported incidence is 0.5-1% of all extra pelvic cases. It is often a second diagnosis, especially, in a non-bleeding endometriosis. The cyclical monthly pain that coincides with menstrual period often helps in establishing the clinical diagnosis.

**Case Report:** A 28-year old married lady presented at the Surgical Out-patient Unit of NARH Bauchi with 2-year history of recurrent umbilical pain. A dull aching, intermittent pain, worse during the menstrual period alleviated with non-steroidal analgesia. Three months ago, the patient noticed an umbilical nodule and no report of bleeding from it were obtained. An abdominal USS with a 5MHz probe indicated an umbilical soft tissue mass with benign features. The endometrial plate was grossly normal, an excisional biopsy was done and the histopathological analysis revealed an extra-uterine endometrial tissue with no malignant changes.

**Conclusion:** The clinical diagnosis of a cutaneous extra pelvic endometriosis is difficult, because, the potential differentials for such nodule are numerous. The presence of cyclical pain or bleeding concurrent with the menstrual flow should raise the index of suspicion. Histopathological diagnosis is often the final arbiter.

**Keywords:** Umbilical nodule, Cyclical pain, Extra pelvic endometriosis

### INTRODUCTION

A cutaneous Endometrioma in the Umbilicus was first reported by Villar in 1886 [1]. Because of this, is often referred to as the Villars's node [2]. Endometriosis is one of the biological quirks where an endometrial tissue is found growing outside the uterine cavity. It affects 10-15% of women, mainly, premenopausal [3]. It is mostly a benign lesion involving pelvic organs contiguous to the uterus. It is commonly found on the Ovaries, ovarian fossa, utero-sacral ligaments, pouch of Douglas and the Bladder [4]. Sometimes it is found as a cutaneous nodule in extra pelvic areas. The Villars's node is such an example [2]. The Umbilical Endometrioma is said to be responsible for 32% of Umbilical nodules, 30% are said to be metastatic sister Joseph's nodules, and the remaining are other benign lesions [5]. Umbilical endometriosis is very rare, constitutes about 0.5% to 1% of all diagnosed Endometrioma of extra genital sites [6]. Previous surgical scar is the most sited cause,

although it may exist as primary umbilical endometriosis [7,8].

Various theories were put forward to explain the aetiopathogenesis apart from an origin from a surgical scar, mostly, laparoscopic scar. These include the possibility of a trans-coelomic migration of endometrial cells during menstruation, coelomic metaplasia or hematogenous and lymphatic metastatic spread of endometrial cells [9].

The presence of a reddish-brown umbilical nodule with

**Corresponding author:** Jabbo Mubarak, Department of Obstetrics and Gynecology, Nigeria Air force Referral Hospital, Bauchi- Nigeria, Tel: +2348122292521; E-mail: Mub2000us@yahoo.com

**Citation:** Ningi AB & Jabbo M. (2022) Primary Umbilical Endometriosis Masquerading as a Painful Umbilical Nodule: A Case Report. Int J Surg Invasive Procedures, □

**Copyright:** ©2022 Ningi AB & Jabbo M. This is an open-access article distributed under the terms of the Creative Commons Attribution License, which permits unrestricted use, distribution, and reproduction in any medium, provided the original author and source are credited.

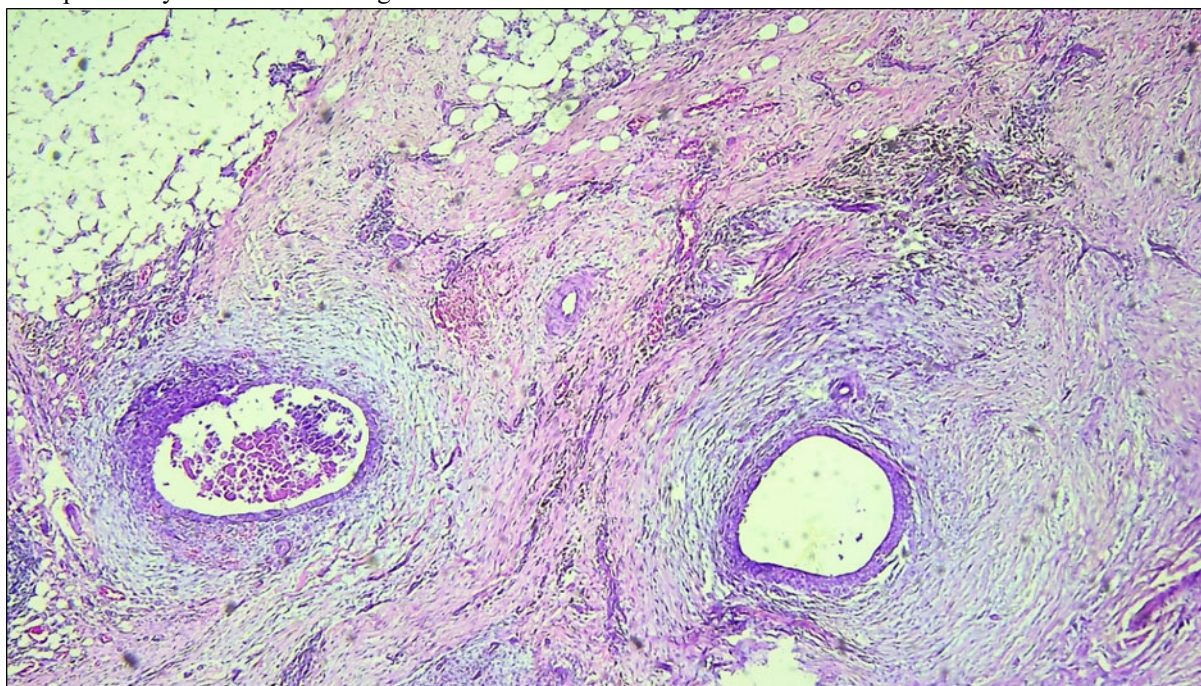
cyclical dull aching pain or bleeding during the menstrual period is the common presentation [10]. Clinical examination often reveals a firm-hard, ovoid umbilical nodule with well-defined edges. Endometriosis involving the colon, rectum, or the small intestine may result in colicky abdominal pain, abdominal distension, constipation, cyclical hematochezia or complete intestinal obstruction during the menstrual flow. If the endometriosis nodule is on the ureter the patient may present with cyclical, intermittent, colicky loin pain, hematuria or painful urination. Pulmonary endometriosis although infrequent, may result in cough, hemoptysis, chest pain or dyspnoea during menstruation [11]. Although diagnosis is clinical, an abdominal USS or even an abdominal CT scan can help. The definitive diagnosis is histopathological report of the excised umbilical nodule. We present a case of a primary umbilical endometriosis in a 28-year old lady who suffered a recurrent cyclical umbilical pain for two years, wasted a lot of money on drugs for pelvic inflammatory disease.

### CASE REPORT

The patient is a 28-year-old married woman who has given birth to one child 3 years ago; her last menstrual period was on 16<sup>th</sup> March, 2022. She presented at the Surgical Out-Patient unit with a 2-year history of recurrent umbilical pain. She was previously seen and managed as a case of

dysfunctional uterine bleeding characterized by both menorrhagia and dysmenorrhea of 2 months' duration. She was referred to us because of the appearance of a painful umbilical nodule. The umbilical swelling started as a peanut-sized swelling with cyclical dull aching pain that coincided with her menstrual flow. She also noticed a cyclical dark-bluish discoloration during the menstrual flow. There were no similar cutaneous nodules in other parts of the body. No history of bleeding from the umbilical nodule was given, also no associated cyclical hematuria, hematochezia, catamenial hemoptysis or catamenial seizure. There was no antecedent history of endometrial instrumentation or pelvic surgery.

Physical examination revealed a dark-brown, ovoid shaped mass, tender, smooth, firm too hard, measures 4\*2 cm in dimension, with well-defined margins. It is entirely extra-peritoneal. Other parts of abdominal and pelvic examination were insignificant. An abdominal USS with a 5MHz probe indicated an umbilical soft tissue mass with benign features with no visceral or nodal enlargements. A pelvic scan showed a grossly normal endometrial plate, absence of leiomyomata and normal adnexa. An excisional biopsy was done and the histopathological analysis revealed an extra-uterine endometrial tissue with no malignant changes (Figure 1).



**Figure 1.** Histologic sections of umbilical nodule showing endometrial glands (arrows) within a fibrotic stroma. Areas of hemosiderin pigment (circled area) deposits are also noted. (H&E x100).

### DISCUSSION

Any organ or tissue may be involved in extra-pelvic endometriosis. Endometriotic tissue has been found in the

Colon and Rectum causing cyclical per rectal bleed, in the bladder, the Lungs and the Brain, resulting in catamenial hematuria, hemoptysis and seizure [12]. Primary cutaneous endometriosis, otherwise called spontaneous, is the one that

developed denovo. A secondary endometriosis is said to follow iatrogenic or traumatic scar [13] a result of direct, iatrogenic, lymphatic or hematogenous spread from pelvic endometriosis [14] or a result of metaplasia [15]. Primary umbilical endometriosis is a rarity as noted earlier [1]. There is no consensus on its pathogenesis, as various theories are put forward to explain this bizarre phenomenon [12]. The Umbilicus is considered to be a physiologic scar, therefore, has tropism for endometriosis like other scar tissues [14]. This may be the case in our patient, because, no preceding history of pelvic surgery was obtained. The differentials for an umbilical nodule are numerous, the cyclical pain, variation in color or size that coincides with menstruation is often the only hint for a clinical diagnosis [16]. The index patient also presented with the monthly cyclical pain and the color and size variation. A constant pain in an umbilical Endometrioma has also been reported [16]. In the absence of pain, during pregnancy and menopause, establishing a clinical diagnosis may be difficult. It is therefore pertinent to keep in view other differentials such as: pyogenic granuloma, umbilical polyp, melanocytic nevus, seborrheic keratosis, epithelial inclusion cyst, desmoid tumor, hemangioma and granular cell tumor [17]. An incarcerated umbilical hernia, omphalitis, keloid and foreign body granuloma may also present as umbilical nodule [16]. As noted earlier, malignant lesions of the umbilical skin such as melanoma, squamous and basal cell carcinoma, and metastatic Mary Joseph's nodules from the gastrointestinal tract may also be found [5,17].

Although majority is diagnosed based on clinical suspicion, radiological assessment could improve the chance of making the right diagnosis. An ultrasound evidence of an umbilical hypoechoic mass with foci of hyperechoic regions and evidence of increased vascular flow on Doppler interrogation is very helpful [18]. An ultrasound scan can also help the surgeon to estimate the size of the nodule, involvement of the parietum, pelvic organs and other viscera like the colon [18]. In difficult cases an MRI may be done, especially if a pelvic endometriosis is suspected and to rule out transcoelomic spread of metastatic nodules from the gastrointestinal tract. The MRI features of an umbilical endometriosis reported are the presence of a homogeneous hypointense lesion on T1-weighted sequence with low signals on T2 weighting [19,20].

The rarity of umbilical endometriosis has made its treatment to be mainly dependent on the experience of the surgeon. Medical treatment has been tried in some patients, but no randomized controlled trial has been done to assess its efficacy [14,16]. The drugs commonly used include progesterone, nor-ethisterone, androgens like Danazol and Gonadotrophin Releasing Hormone analogue, such as Goserelin and Boserelin. The most consistent effect reported is the symptomatic relief of pain and reduction in the size of the nodule after medical treatment [17]. Surgery has so far remained the most promising treatment for umbilical

endometriosis [21]. The goal should be a complete resection with no recurrence, but, this is an uphill task in a disease with tropism for scar tissue like endometriosis. Surgical umbilical resection with or without repair of underlying fascia and peritoneum, or enucleation of the endometrial nodule with preservation of the umbilicus are mostly done. Total resection of umbilicus is however, preferred, as it carries low risk of recurrence [17].

## CONCLUSION

A spontaneous umbilical Endometrioma is rare, high index of suspicion is required regarding any umbilical nodule with cyclical symptoms, and the possibility of sinister differentials like metastatic adenocarcinomatous nodules should always be entertained.

## CONFLICT OF INTEREST

None

## REFERENCES

1. The WT, Vollen hoven B, Harris PI (2006) Umbilical endometriosis, a pathology that a gynecologist may encounter when inserting the Veres needle. *Fertil Steril* 86(6): 1764.e1-2.
2. Dorothy M, Timona O, Steve M, Felix O (2020) Umbilical endometriosis: A case series. *J Med Case Rep* 14: 142.
3. Eskenazi B, Warner ML (1997) Epidemiology of endometriosis. *Obstet Gynecol Clin North Am* 24(2): 235-258.
4. Audebert A, Petousis S, Margioulas-Siarkou C, Ravanos K, Prapas N, et al. (2018) Anatomic distribution of endometriosis: A reappraisal based on series of 1101 patients. *Eur J Obstet Gynecol Reprod Biol* 230: 36-40.
5. Giudice LC, Kao LC (2004) Endometriosis. *Lancet* 364: 1789-1799.
6. Mustafa TB, Mehmet AA, Fatima AK, Mehmet AÇ, Ahmet S (2017) Primary umbilical endometriosis: Menstruating from the umbilicus. *Turkderm-Turk Arch Dermatol Venereol* 51: 101-103.
7. Latcher JW (1953) Endometriosis of the umbilicus. *Am J Obstet Gynecol* 66: 161-168.
8. Mann LS, Clarke WR (1964) Endometriosis of the umbilicus. *IMJ III Med J* 125: 335-336.
9. Elias B, Adam E, Ziadeh H, Matta C (2017) Atypical clinical presentation of primary umbilical endometriosis. *Clin Surg* 2: 1635.
10. Dessy LA, Buccheri EM, Chiummariello S, Gagliardi DN, Onesti MG (2008) Umbilical endometriosis, our experience. *In vivo* 22: 811-815.

11. Fuminori T, Eriko H, Yukihiro A, Chihiro U, Keigo A, et al. (2016) Primary Umbilical Endometriosis: Unusual and Rare Clinical Presentation. Case Rep Obstet Gynecol 2016: 9302376.
12. Dridi D, Chiaffarino F, Parazzini F, Donati A, Buggio L, et al. (2022) Umbilical Endometriosis: A Systematic Literature Review and Pathogenic Theory Proposal. J Clin Med 11(4): 995.
13. Hirata T, Koga K, Kitade M, Fukuda S, Neriishi K, et al. (2020) A national Survey of Umbilical Endometriosis in Japan. J Minim Invasive Gynecol 27: 80-87.
14. Jaime TJ, Jaime TJ, Ormiga P, Leal F, Nogueira OM, et al. (2013) Umbilical endometriosis: Report of a case and its dermoscopic features. Anais brasileiros de dermatologia 88(1): 121-124.
15. Romera-Barba E, Ramón-Llión JC, Pérez AS, Navarro GI, Rueda-Pérez JM, et al. (2014) Endometriosis umbilical primaria. A propósito de 6casos. Rev Hispanoam Hernia 2: 105-110.
16. Seracettin E, Bedri Aras P, Semih H, Veli M (2016) Primary umbilical endometriosis: A painful swelling in the umbilicus concomitantly with menstruation. Int J Surg Case Rep 28: 78-80.
17. Boccara D, Runz AD, Marco O, Chaouat M, Mimoun M (2016) Primary Skin Umbilical Endometriosis: About One Case. J Clin Case Rep 6: 742.
18. Genovese G, Passoni E, Veraldi S, Nazzaro G (2018) Ultrasonographic findings in primary umbilical endometriosis. A Bras Dermatol 93(2): 297-298.
19. Hartigan C, Holloway B (2005) MR imaging features of endometriosis at the umbilicus. Br J Radiol 78(932): 755-757.
20. Yu CY, Perez-Reyes M, Brown JJ, Borrello JA (1994) MR appearance of umbilical endometriosis. J Comput Assist Tomogr 18(2): 269-271.
21. Datta S, Basu R (2021) Spontaneous Primary Umbilical Endometriosis Preceding Severe Pelvic Endometriosis: A Case Report. J South Asian Feder Obst Gynae 13(5): 350-351.