

A Rare Causatum of Aneurysm Surgery

Mahesh Kumar, Vidhi Shah, Prithviraj Udaya* and Kowsalya Akkayasamy

*Department of Neuro-Ophthalmology, Aravind Eye Hospital, Madurai, India.

Received June 12, 2019; Accepted June 17, 2019; Published December 05, 2019

ABSTRACT

Oculomotor nerve palsies (ONP) are commonly observed in lieu of intracranial aneurysms or subsequent to aneurysm surgeries. A 31 year old gentleman with no neurological deficits prior to an aneurysm surgery done 5 months ago, presented with drooping of the right upper lid. Preoperative neuroimaging had revealed a basilar artery tip aneurysm with mild vasospasm of P1 segment of the right posterior cerebral artery. Examination of right eye revealed a complete ptosis with a mid-dilated non-reacting pupil and limitation of elevation, depression and adduction. He also exhibited left hemiparesis and weakness of left half of the face with forehead spared. The myriad of features is plausibly due to an “exaggerated vasospasm” of the thalamo perforators compromising the blood supply to the cerebral peduncle. We report a rare case of oculomotor nerve palsy with concomitant brainstem involvement post aneurysm surgery.

Keywords: Distal basilar artery aneurysm, Post aneurysm surgery, Hemiparesis, Facial palsy, Oculomotor nerve palsy

INTRODUCTION

Oculomotor nerve palsies (ONP) are commonly observed in lieu of intracranial aneurysms or subsequent to aneurysm surgeries. We report a rare case of a third nerve palsy in conjunction with a contralateral seventh nerve palsy and hemiparesis in a young man post aneurysm surgery.

CASE REPORT

A 31 year old gentleman with hemorrhoids since childhood was rushed to the emergency room five months ago with intense headache and an episode of hematemesis. Ultrasonography of the abdomen was normal. Neuroimaging (**Figure 1**) had revealed a basilar artery tip aneurysm with “mild vasospasm” of P1 segment of the right posterior cerebral artery. A week later, an inadvertent intraoperative aneurysm rupture had necessitated the use of “forced” temporary clipping. Consequently, he was ventilator-dependent in the immediate postoperative period. On regaining consciousness, he reported inability to open the right eye, asymmetry of the mouth with weakness of the left arm and leg.

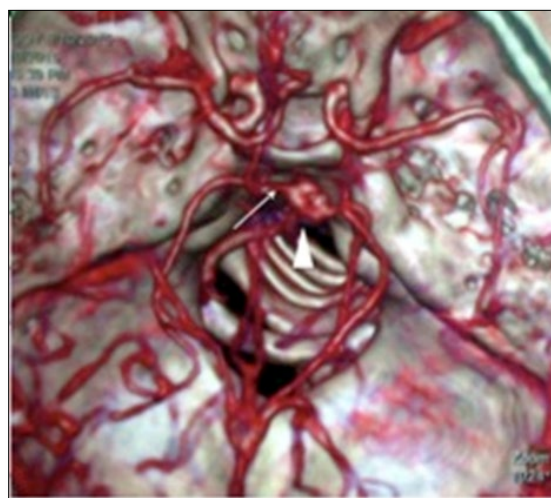

Figure 1. CT-angiography detected a bilobed saccular aneurysm (arrowhead) originating from the basilar artery tip and P1 junction coursing upwards, measuring 0.70×0.45 cm with mild vasospasm of the P1 segment of right posterior cerebral artery (arrow).

Corresponding author: Prithviraj Udaya, Department Of Neuro-Ophthalmology, Aravind Eye Hospital, Madurai, India, E-mail: uprithviraj@gmail.com

Citation: Kumar M, Shah V, Udaya P & Akkayasamy K. (2019) A Rare Causatum of Aneurysm Surgery. *Ophthalmol Clin Res*, 2(3): 89-91.

Copyright: ©2019 Kumar M, Shah V, Udaya P & Akkayasamy K. This is an open-access article distributed under the terms of the Creative Commons Attribution License, which permits unrestricted use, distribution, and reproduction in any medium, provided the original author and source are credited.

Currently, his best corrected visual acuity was 20/40, right eye and 20/20, left eye. A bony depression noted in the right fronto-parietal region corresponded to the site of surgery. There was complete ptosis of the right upper lid (**Figure 2**) and 15 degrees exotropia in primary gaze with limitation of elevation, depression and adduction (**Figure 3**). The pupil was mid-dilated and fixed. Features suggestive of a left upper motor neuron (UMN) facial palsy were, preserved forehead creases (**Figure 2**), weakness of the orbicularis oculi and buccinator with minimal lagophthalmos in addition to the angle of the mouth deviated to the right (**Figure 4**). Remaining cranial nerves were intact. Diplopia and Hess charting verified a right third nerve palsy. An observation of right complete pupil involving ONP with left UMN facial palsy and left hemiparesis, status post basilar artery aneurysm clipping was made.

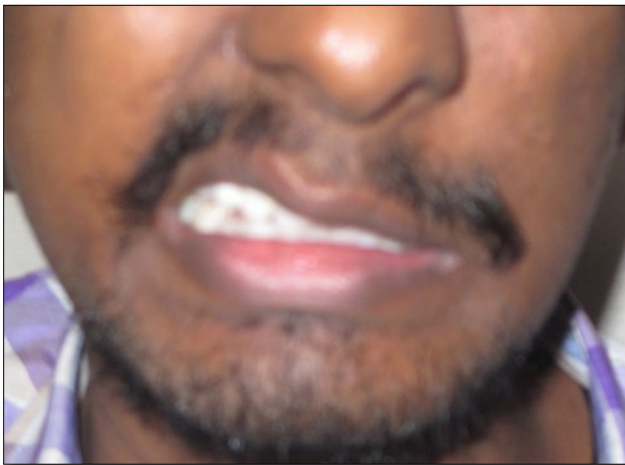


Figure 2. Right complete ptosis is present with intact left forehead creases; Right frontoparietal bony defect corresponding to the site of craniotomy.

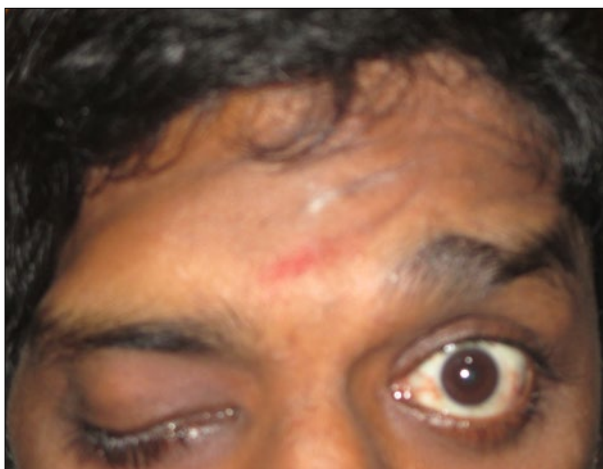

Figure 3. Limited right eye movements in all directions except abduction. The right lid is held open with finger.

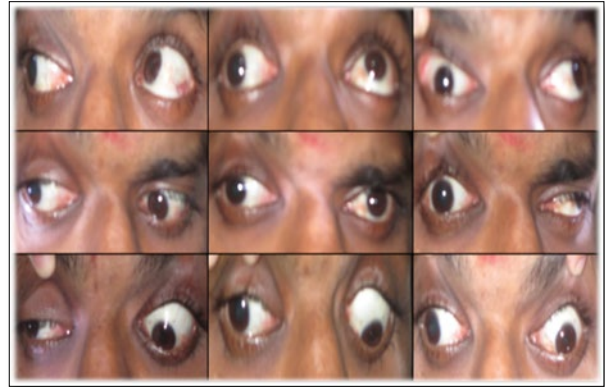

Figure 4. Loss of left nasolabial folds with deviation of angle of the mouth to the right indicating left buccinator weakness.

DISCUSSION

Basilar artery (BA) aneurysms account for 3-8% of intracranial aneurysms [1] and are the most common aneurysms in the posterior fossa [2]. The incidence of ONP post BA aneurysm clipping is estimated to be 25-80% [3-7] the risk factors [3,4,8,9] being: 1) Large aneurysms (>10 mm) 2) Younger age 3) Poor Hunt and Hess grade 4) Temporary arterial occlusion 5) Poor Glasgow outcome scale score 6) Posterior projection of distal aneurysm. In accordance with the risk factors, younger age and temporary clipping predisposed our patient to ONP following surgery; however he also exhibited contralateral facial weakness and hemiparesis. Exhaustive literature search divulged two reports, one by Cruciger et al. [5] who stated 29% cases developing ONP with hemiparesis post BA aneurysm surgery and one case of superior Foville syndrome after clipping of basilar bifurcation aneurysm [10]. Therefore, the concurrent involvement of oculomotor nerve, facial nerve and corticospinal tract post aneurysm surgery is unusual.

The possible mechanism for the course of events could be intraoperative vasospasm [6,11,12], mechanical damage [3,4] or vascular injury [5] attributable to the narrow surgical corridor in younger patients, increasing the manipulation of the surrounding neurovascular structures [5,6]. In our case, "exaggerated vasospasm" is plausibly the cause, augmenting a pre-existent "mild vasospasm" of the P1 segment of posterior cerebral artery (thalamo perforators) in the absence of any neurological deficits. The "exaggerated vasospasm" in the midst of surgery, brought on by temporary clipping for an inadvertent aneurysm rupture, probably critically compromised the blood supply to the cerebral peduncle resulting in ischemia of the oculomotor nerve, corticobulbar and corticospinal tracts that caused the myriad of features. However, the definitive cause could not be ascertained as ventilator-dependency is a relative contraindication for CT angiography.

Numerous studies [3,5,6] have reported excellent recovery rates for isolated ONPs, with complete recovery occurring within 3 to 6 months. However, the recovery in our patient was incomplete due to a concomitant brainstem involvement.

To summarise, encountering ONPs post aneurysm surgeries is common, albeit the recovery is incomplete when multiple cranial nerves are affected. The parallelism between hemorrhoids and basilar artery aneurysm in our case was significant of an inherent vessel wall weakness [13]. It is highly recommended to screen patients with hemorrhoids for aneurysms elsewhere.

REFERENCES

1. Pia HW (1979) Classification of vertebro-basilar aneurysms. *Acta Neurochir (Wien)* 47: 3-30.
2. Giffin NJ, Goadsby PJ (2001) Basilar artery aneurysm with autonomic features: An interesting pathophysiological problem. *J Neurol Neurosurg Psychiatry* 71: 805-808.
3. Al-Khayat H, Al-Khayat H, White J, Manner D, Samson D (2005) Upper basilar artery aneurysms: Oculomotor outcomes in 163 cases. *J Neurosurg* 102: 482-488.
4. Horikoshi T, Nukui H, Yagishita T, Nishigaya K, Fukasawa I, et al. (1999) Oculomotor nerve palsy after surgery for upper basilar artery aneurysms. *Neurosurgery* 44: 705-710.
5. Cruciger MP, Hoyt WF, Wilson CB (1981) Peripheral and midbrain oculomotor palsies from operations for basilar bifurcation aneurysm in a series of 31 cases. *Surg Neurol* 15: 215-216.
6. Sharma M, Ahmed O, Ambekar S, Sonig A, Nanda A (2014) Factors predicting the oculomotor nerve palsy following surgical clipping of distal vertebrobasilar aneurysms: A single-institution experience. *J Neurol Surg B Skull Base* 75: 261-267.
7. Redekop GJ, Durity FA, Woodhurst WB (1997) Management-related morbidity in unselected aneurysms of the upper basilar artery. *J Neurosurg* 87: 836-842.
8. Lozier AP, Kim GH, Sciacca RR, Connolly ES Jr, Solomon RA (2004) Microsurgical treatment of basilar apex aneurysms: Perioperative and long-term clinical outcome. *Neurosurgery* 54: 286-296.
9. Samson D, Batjer HH, Kopitnik TA Jr (1999) Current results of the surgical management of aneurysms of the basilar apex. *Neurosurgery* 44: 697-702.
10. Takase M, Saeki N, Oka N, Satoh A, Otaki M, et al. (1981) Superior Foville syndrome after clipping of basilar bifurcation aneurysm - Case report (author's transl). *No Shinkei Geka* 9: 343-347.
11. Goto K, Imai H, Nakazato O, Tsuda T, Okajima T (1993) Inferior branch palsy of the oculomotor nerve following clipping of basilar apex aneurysm. *Rinsho Shinkeigaku* 33: 203-206.
12. Kudo T (1986) Postoperative oculomotor palsy due to vasospasm in a patient with a ruptured internal carotid artery aneurysm: A case report. *Neurosurgery* 19: 274-277.
13. Miller NR, Newman NJ (1998) Aneurysms. In: Walsh and Hoyt's clinical neuroophthalmology. 5th Edn. Baltimore: Williams & Wilkins.