

Dexamethasone Intravitreal Implant for Diabetic Macular Edema in Previously Treated Patients

Albert J. Augustin*

*Department of Ophthalmology, Staedtisches Klinikum Karlsruhe, Karlsruhe, Germany

Received March 20, 2018; Accepted April 2, 2018; Published June 17, 2018

REVIEW

Diabetic macular edema (DME) is a vision-threatening disease that is estimated to affect 21 million individuals worldwide [1]. The etiology of DME is multifactorial, involving vascular endothelial growth factor (VEGF) production as well as inflammatory processes [2]. As recently as 2010, the only approved treatment for DME was focal/grid laser photocoagulation of leaking microaneurysms and areas of retinal thickening to decrease the risk of further vision loss. However, laser photocoagulation is a destructive procedure, and potential complications include the development of scotomas related to focal laser burns. There was a need for new DME treatments that would restore lost vision, as well as reduce the retinal fluid accumulation that causes vision loss.

Dexamethasone intravitreal implant 0.7 mg (DEX; Ozurdex, Allergan plc, Dublin, Ireland) was developed to treat ocular posterior segment diseases that have an inflammatory component. The sustained-release implant contains 0.7 mg dexamethasone embedded in a biodegradable polymer matrix of poly D, L lactide-co-glycolide. Dexamethasone is released slowly over a period of months as the implant matrix is hydrolyzed to lactic acid and glycolic acid, which are subsequently metabolized to carbon dioxide and water. A preloaded, single-use 22-gauge applicator is used to insert the implant into the vitreous through the pars plana.

DEX was evaluated for the treatment of DME in the 3-year MEAD global registration study involving 1048 patients in 22 countries [3]. Adult patients with DME, best-corrected visual acuity (BCVA) between 20/50 and 20/200, and central retinal thickness (CRT) ≥ 300 μm on optical coherence tomography were enrolled and randomly assigned in a 1:1:1 ratio to treatment in the study eye with DEX 0.7 mg, DEX 0.35 mg, or sham procedure. For the sham procedure, a needleless applicator was pressed against the conjunctiva. Study treatment was administered at baseline, and patients who met eligibility criteria could be administered repeat treatment no more often than every 6 months, for a maximum of 7 administrations over the 3-year

period. Patients were followed for 3 years (or 39 months for patients who were treated at month 36). Patients who required rescue therapy were exited from the study before receiving the rescue treatment.

In the total study population, DEX 0.7 mg and 0.35 mg were significantly more effective than sham procedure in improving BCVA and decreasing edema, as measured by a decrease in CRT. Both DEX 0.7 mg and DEX 0.35 mg met the primary endpoint: the percentage of patients with ≥ 15 -letter improvement in BCVA from baseline at study end (with missing values imputed using the last observation carried forward) was 22.2% in the DEX 0.7 mg group and 18.4% in the DEX 0.35 mg group compared with 12.0% in the sham group ($P \leq 0.018$). The mean average improvement in BCVA over the course of the study, measured with an area-under-the-curve approach, was also greater in the DEX 0.7 mg group (+3.5 letters) and the DEX 0.35 mg group (+3.6 letters) compared with the sham group (+2.0 letters) ($P \leq 0.023$), and the mean average reduction in CRT from baseline over the course of the study was greater in the DEX 0.7 mg group (-111.6 μm) and the DEX 0.35 mg group (-107.9 μm) compared with the sham group (-41.9 μm) ($P < 0.001$).

The safety profile of DEX in the MEAD study was better than the reported safety profile of other intraocular corticosteroid sustained-release implants [4]. The most common adverse effects, as expected, were steroid-related increases in (intraocular pressure) IOP and cataract.

Corresponding author: Albert J. Augustin, MD, Department of Ophthalmology, Staedtisches Klinikum Karlsruhe, Moltkestrasse 90, 76133 Karlsruhe, Germany, Tel: +49 7219 742001; Fax: +49 7219 742001; Email: albertjaugustin@googlemail.com

Citation: Augustin A J. (2018) Dexamethasone Intravitreal Implant for Diabetic Macular Edema in Previously Treated Patients. *Ophthalmol Clin Res*, 1(1): 9-12.

Copyright: ©2018 Augustin A J. This is an open-access article distributed under the terms of the Creative Commons Attribution License, which permits unrestricted use, distribution, and reproduction in any medium, provided the original author and source are credited.

The frequency of IOP increases did not increase with repeated DEX treatment [5], and the IOP increases were usually managed with topical medication. Only 1 (0.3%) patient in each DEX group required glaucoma incisional surgery for a corticosteroid-induced IOP increase [3]. Cataract-related adverse events were reported in the majority of phakic eyes in the DEX treatment groups, and vision loss occurred after these events. However, vision improved and treatment benefit was restored after cataract surgery, which was performed in 59.2%, 52.3%, and 7.2% of study eyes that were phakic at baseline in the DEX 0.7 mg, DEX 0.35 mg, and sham groups, respectively. In eyes with a cataract adverse event that underwent cataract surgery, the mean average change in BCVA from baseline, from the time of surgery to study end, was +4.3, +4.7, and +1.7 letters in the DEX 0.7 mg, DEX 0.35 mg, and sham groups, respectively. In eyes that were pseudophakic at baseline, the mean average change in BCVA from baseline during the study was +6.5, +5.9, and +1.7 letters, respectively.

The results of the MEAD study showed that in the total study population, an average of only 4 or 5 injections of DEX implant 0.7 or 0.35 mg over 3 years provided long-term improvement in vision and macular edema in patients with DME. These results led to regulatory agency approval of DEX 0.7 mg for treatment of DME. Subsequently, subgroup analysis using MEAD study data from patients in the DEX 0.7 mg group and the sham group was performed to evaluate the effects of DEX 0.7 mg (marketed dose) treatment in patients with DME that had been previously treated with laser or medical therapy [6]. Approximately 70% of patients in the DEX 0.7 mg group had been previously treated for DME in the study eye. Among these patients, 231 (93.5%) had received laser, 58 (23.5%) had received intravitreal steroid (triamcinolone acetonide), and 25 (10.1%) had received intravitreal anti-VEGF therapy.

The primary efficacy and safety analyses that had been performed for the total MEAD study population were repeated for previously treated patients in the DEX 0.7 mg and sham groups. The efficacy results in previously treated patients [6] were similar to those in the total study population. The percentage of previously treated patients with ≥ 15 -letter improvement in BCVA from baseline at study end was 21.5% in the DEX group compared with 11.1% in the sham group ($P=0.002$), mean average improvement in BCVA over the course of the study was +3.2 letters in the DEX group compared with +1.5 letters in the sham group ($P=0.024$), and mean average reduction in CRT from baseline over the course of the study was 126 μm in the DEX group compared with 39 μm in the sham group ($P<0.001$). In additional subgroup analysis, DEX demonstrated benefit of treatment in patients previously treated with laser, steroid, or anti-VEGF (**Figure 1**), as well as in patients previously treated with at least two of these modes of therapy.

The safety profile of DEX was also similar in the total study population and the subgroup of previously treated patients. Among previously treated patients, cataract-related adverse events were reported in 70.3% of patients in the DEX 0.7 mg group who had phakic lens status at baseline. Cataract-related adverse events led to vision loss in these patients, but vision gains were restored after cataract surgery (**Figure 2**).

Intravitreal anti-VEGF therapy has become the standard first-line treatment for center-involved DME. However, a significant number of patients have a suboptimal response to anti-VEGF therapy even when monthly injections are administered [7]. Additional treatment options are needed when anti-VEGF therapy fails to normalize retinal thickness and improve vision. DEX demonstrated efficacy in patients previously treated with anti-VEGF in the MEAD study, but the sample size was small, because the study began in 2004, before anti-VEGF was widely used for treatment of DME. Furthermore, in clinical practice, DEX may be administered more frequently than the minimum 6-month interval used in the MEAD study, and this potentially may improve outcomes. Following regulatory agency approval of DEX for treatment of DME, at least 12 studies have investigated DEX effectiveness in patients with DME refractory to anti-VEGF therapy. A recent meta-analysis of results from these studies reported robust (multiple-line) improvement in visual acuity after DEX treatment in patients with DME resistant to anti-VEGF therapy [8]. Based on evidence from the MEAD subgroup analysis, subsequent studies of DEX use in patients previously treated with anti-VEGF, and their clinical experience, an expert panel of retinal specialists recently developed guidelines for DME management that recommend DEX treatment in patients with DME that responds inadequately to anti-VEGF [9].

In summary, subgroup analysis of the MEAD study [6] showed that patients with DME previously treated with laser, intravitreal anti-VEGF, intravitreal triamcinolone acetonide, or a combination of these therapies had significantly improved BCVA and CRT following DEX treatment. The safety profile of DEX in previously treated patients was acceptable and similar to its safety profile in the total MEAD study population. Subsequent studies have confirmed the benefit of DEX treatment in patients with DME refractory to anti-VEGF therapy. DEX demonstrates efficacy and safety in patients with DME previously treated with other therapy and is an excellent treatment option for patients with a suboptimal response to anti-VEGF therapy.

ACKNOWLEDGMENTS

Financial disclosure: Albert J. Augustin has received research support and speaker fees from Allergan.

Medical writing support, funded by Allergan, was provided by Kate Ivins, PhD, Evidence Scientific Solutions, Philadelphia, PA, USA.

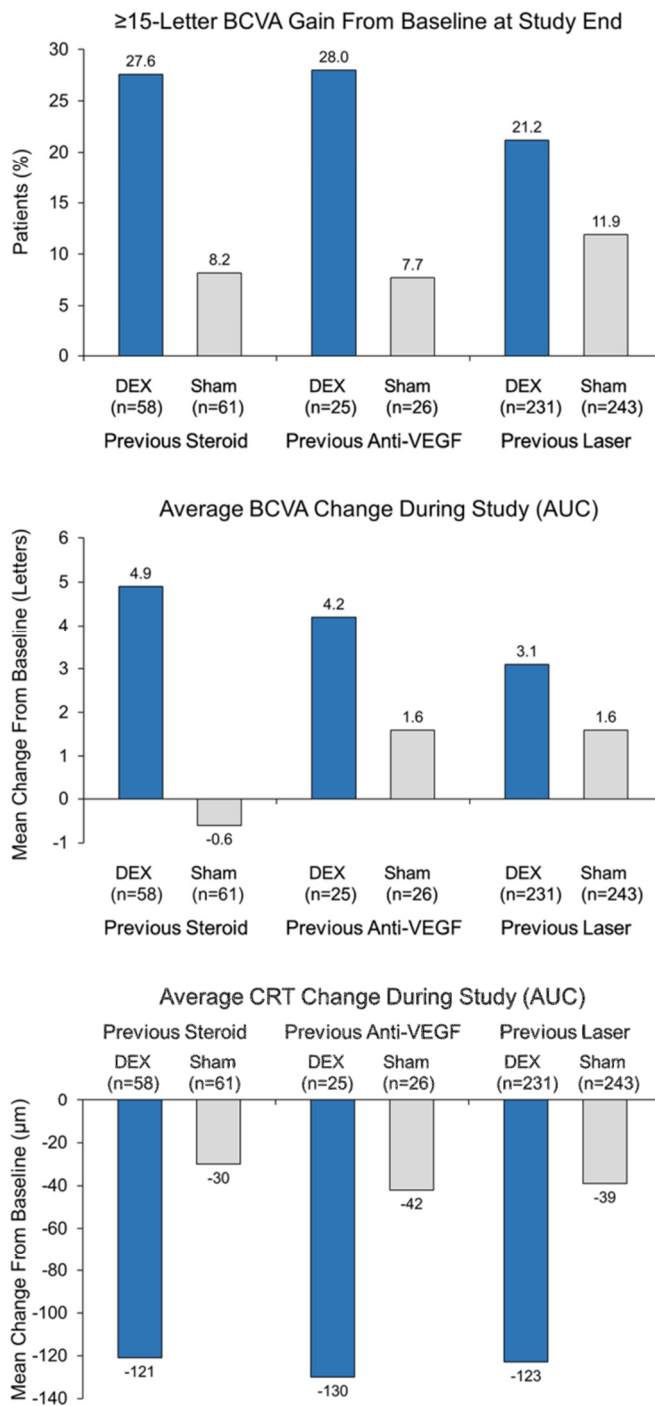


Figure 1. Efficacy outcomes in subgroups of patients previously treated with corticosteroid, anti-VEGF, and laser in the MEAD registration study of DEX for treatment of DME. [6] Analysis of percentage of patients with ≥ 15 -letter BCVA gain used last observation carried forward for missing values. Analysis of average BCVA and CRT change from baseline used observed values and an area-under-the-curve (AUC) approach. BCVA = best-corrected visual acuity; CRT = central retinal thickness; DEX = dexamethasone intravitreal implant 0.7 mg; VEGF = vascular endothelial growth factor.

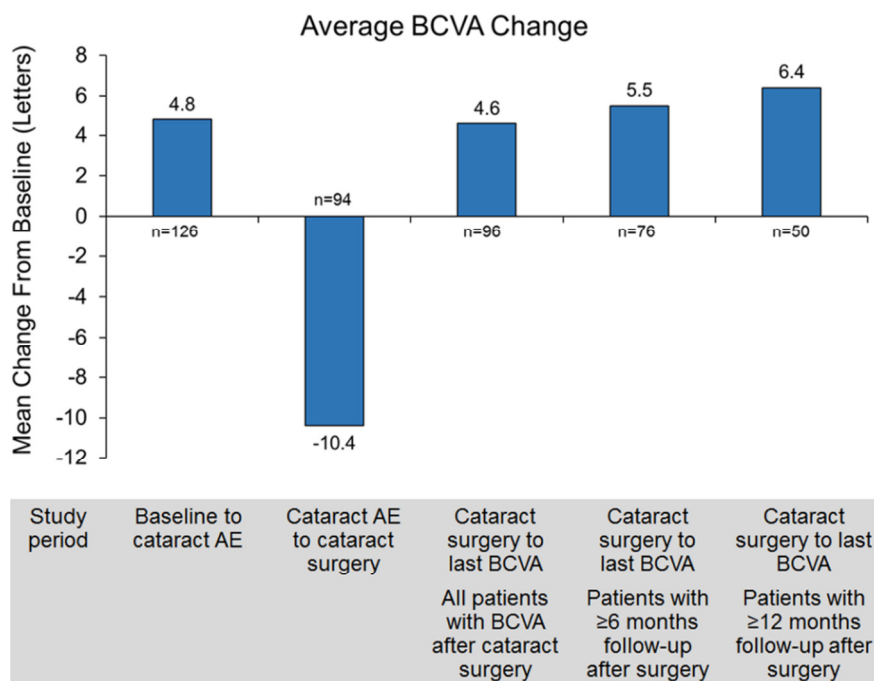


Figure 2. Mean average change from baseline BCVA before and after cataract surgery in previously treated patients with cataract-related adverse events in the DEX group of the MEAD study. Reproduced from Augustin et al [6] under the terms of the Creative Commons Attribution 4.0 International License (<http://creativecommons.org/licenses/by/4.0/>). AE = adverse event; BCVA = best-corrected visual acuity; DEX = dexamethasone intravitreal implant 0.7 mg.

REFERENCES

1. Yau JW, Rogers SL, Kawasaki R, Lamoureux EL, Kowalski JW, et al.; Meta-Analysis for Eye Disease (META-EYE) Study Group (2012) Global prevalence and major risk factors of diabetic retinopathy. *Diabetes Care* 35: 556-564.
2. Ehrlich R, Harris A, Ciulla TA, Kheradiya N, Winston DM, et al. (2010) Diabetic macular oedema: physical, physiological and molecular factors contribute to this pathological process. *Acta Ophthalmol* 88: 279-291.
3. Boyer DS, Yoon YH, Belfort R Jr, Bandello F, Maturi RK, et al. (2014) Three-year, randomized, sham-controlled trial of dexamethasone intravitreal implant in patients with diabetic macular edema. *Ophthalmology* 121: 1904-1914.
4. Whitcup SM, Cidlowski JA, Csaky KG, Ambati J (2018) Pharmacology of corticosteroids for diabetic macular edema. *Invest Ophthalmol Vis Sci* 59: 1-12.
5. Maturi RK, Pollack A, Uy HS, Varano M, Gomes AM, et al. (2016) Intraocular pressure in patients with diabetic macular edema treated with dexamethasone intravitreal implant in the 3-year MEAD study. *Retina* 36: 1143-1152.
6. Augustin AJ, Kuppermann BD, Lanzetta P, Loewenstein A, Li XY, et al. (2015) Dexamethasone intravitreal implant in previously treated patients with diabetic macular edema: subgroup analysis of the MEAD study. *BMC Ophthalmol* 15: 150.
7. Gonzalez VH, Campbell J, Holekamp NM, Kiss S, Loewenstein A, et al. (2016) Early and long-term responses to anti-vascular endothelial growth factor therapy in diabetic macular edema: analysis of protocol I data. *Am J Ophthalmol* 172: 72-79.
8. Khan Z, Kuriakose RK, Khan M, Chin EK, Almeida DR (2017) Efficacy of the intravitreal sustained-release dexamethasone implant for diabetic macular edema refractory to anti-vascular endothelial growth factor therapy: meta-analysis and clinical implications. *Ophthalmic Surg Lasers Imaging Retina* 48: 160-166.
9. Regillo CD, Callanan DG, Do DV, Fine HF, Holekamp NM, et al. (2017) Use of corticosteroids in the treatment of patients with diabetic macular edema who have a suboptimal response to anti-VEGF: recommendations of an expert panel. *Ophthalmic Surg Lasers Imaging Retina* 48: 291-301.