

Corneal Opacities after Wearing Colored Soft Contact Lenses

Tatsuya Mimura^{1*}, Hidetaka Noma² Emiko Watanabe,¹ Masato Ochi,¹ Atsushi Mizota¹

¹Department of Ophthalmology, Teikyo University School of Medicine, Tokyo 173-8605, Japan.

² Department of Ophthalmology, Hachioji Medical Center, Tokyo Medical University, Tokyo 193-0998, Japan.

Received February 7, 2018; Accepted February 12, 2018; Published June 15, 2018

INTRODUCTION

Colored contact lenses are used to change the appearance of the eyes and are very popular. Some colored contact lenses have a series of tiny colored dots printed on the lenses. Although this is not necessarily problematic, incorrect use of colored contact lenses may cause ocular damage [1, 2]. We report a patient with multiple corneal opacities after wearing colored contact lenses.

CASE REPORT

A 38-year-old man has used plain 2-weekly disposable soft contact lenses (SCLs) for 15 years. He subsequently changed to green-colored monthly disposable SCLs. One day, after he had been wearing the colored SCLs for about 12 hours, he noticed a burning sensation and blurred vision in both eyes. Therefore, he stopped wearing the colored SCLs.

Blurred vision of the left eye improved within 1 day, but blurred vision and irritation of the right eye persisted. He presented to our hospital three days after he had stopped wearing the colored SCLs. On examination, the best-corrected visual acuity was 20/40 for the right eye and 20/20 for the left eye. The right eye had green superficial corneal opacities forming a honeycomb reticular pattern (**Figure 1A, B**). The patient was treated by instillation of balanced salt solution eye drops every three hours. After one week, his symptoms subsided and there was complete resolution of the corneal opacities (**Figure 1C**). Visual acuity was 20/20 for both eyes.

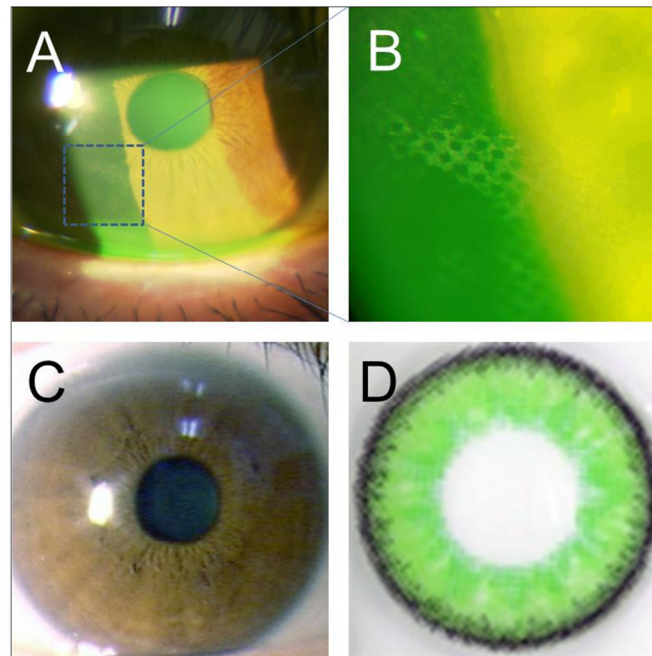


Figure 1. The patient's right eye before and after treatment, and the patient's colored SCL. Images of the corneal opacities caused by wearing the SCL (A, B). The corneal opacities have resolved after 1 week (C). The colored SCL (D).

Colored SCLs are also called ‘decorative’, ‘costume’, or ‘fashion’ SCLs. Our patient purchased his colored SCLs cheaply on the internet (Figure 1D). Various low-cost colored SCLs, including poor quality lenses, can be obtained easily on the internet. Some of these SCLs have patterns printed on the lenses with water-soluble dyes. Sale of colored SCLs should be strictly controlled by legal regulations.

ACKNOWLEDGEMENT

Declared none.

CONFLICT OF INTEREST

Declared none.

PROPRIETARY INTEREST

The authors do not have any proprietary interest in this manuscript.

GRANTS AND FUNDS

This work was supported in part by a Grant-in-Aid for Scientific Research from the Ministry of Education, Culture, Sports, Science.

Corresponding author: Tatsuya Mimura, MD, Ph.D, Department of Ophthalmology, Teikyo University School of Medicine, 2-11-1 Kaga, Itabashi-ku, Tokyo, 173-8605 Japan. Phone: +81-3-3964-1211, Fax: +81-3-3964-1402, E-mail: mimurat-ky@umin.ac.jp

Citation: Mimura T, Noma H, Watanabe E, Ochi M & Mizota A. (2018) Corneal Opacities after Wearing Colored Soft Contact Lenses. *Ophthalmol Clin Res*, 1(1): 1-2.

Copyright: ©2018 Mimura T, Noma H, Watanabe E, Ochi M & Mizota A. This is an open-access article distributed under the terms of the Creative Commons Attribution License, which permits unrestricted use, distribution, and reproduction in any medium, provided the original author and source are credited.

References

1. Singh S, Satani D, Patel A, Vhankade R. Colored cosmetic contact lenses: an unsafe trend in the younger generation. *Cornea* 2012 Jul;31(7):777-779.
2. Rah MJ, Schafer J, Zhang L, Chan O, Roy L, et al. A meta-analysis of studies on cosmetically tinted soft contact lenses. *Clin Ophthalmol* 2013;7:2037-2042.