

Macular Hole

Upma Awasthi* and Rohini Grover

*CL Gupta Eye Institute, India.

Received July 31, 2019; Accepted August 20, 2019; Published April 08, 2020

ABSTRACT

Since described as early as 1869 by Knapp, macular hole has been an entity of great interest for various investigators. This resulted in continuous revolutions in the underlying pathogenesis and its management. Recently OCT has emerged as most important imaging modality for prognostication and planning of surgical intervention. Most popular surgical intervention to treat macular hole is pars plana Vitrectomy with internal limiting membrane peeling with gas tamponade. This review article is focused on clinical features, pathogenesis, roles of newer imaging tools in the management of macular holes and different surgical approaches.

Keywords: Macula hole, Gas tamponade, ILM peeling, Brilliant blue G

Abbreviations: MH: Macular Hole; ERM: Epiretinal Membrane; CME: Cystoid Macular Edema; RD: Retinal Detachment; CNVM: Choroidal Neovascular Membrane; FTMH: Full Thickness Macular Hole; SD-OCT: Spectral Domain-Optical Coherence Tomography; FFA: Fundus Fluorescein Angiography; LMH: Lamellar Macular Holes; HFF: Hole Form Factor; FAF: Fundus Autofluorescence; LF: Melanin lipofuscin; RPE: Retinal Pigment Epithelium; OPL: Outer Photoreceptor Layer; MPH: Macular Pseudoholes; FP: Foveal Pseudocysts; VMT: Vitreomacular Traction; ILM: Internal Limiting Membrane; BBG: Brilliant Blue G; PFCL: Perfluorocarbon Liquid; FDP: Face Down Posturing; SANFL: Swelling of the Arcuate Retinal Nerve fiber Layer; DONFL: Dissociated Optic Nerve fiber Layer

INTRODUCTION

Macular hole (MH) represents a partial or full thickness defect or dehiscence in the central retina at the umbo [1]. The prevalence rate of MH in India has been found to be 0.17% [2]. With the better understanding of pathogenesis and improvement in vitreoretinal surgical technique and instrumentation, excellent visual outcomes can be achieved.

CAUSES

Primary cause of MH in majority of cases is idiopathic. Trauma is among the most common secondary cause of macular hole. Apart from trauma, other conditions that can secondarily lead to MH are epiretinal membrane (ERM), cystoid macular edema (CME), retinal detachment (RD), proliferative diabetic retinopathy, severe hypertensive retinopathy, choroidal neovascular membrane (CNVM), juxta foveal telangiectasia, retinoschisis, lightening, photic retinopathy (electrocution, welding, accidental Nd-YAG laser) [3-6].

CLINICAL FEATURES

Idiopathic MH usually occurs in the sixth to seventh decade and women are affected more often than men; reported ratio is 2-3:1 [3]. There is no proven theory for female preponderance but recently study done with SD-OCT has

shown that females have significantly thinner central foveal thickness [7]. There is 3-29% risk of fellow eye getting affected with MH [8].

SYMPTOMS

Patients with smaller MH may have no symptoms and are diagnosed on routine ophthalmoscopic evaluation. Symptomatic patients usually complain of blurred vision and metamorphopsia. Those with larger holes will have scotoma or a defect in central vision.

SIGNS

Visual acuity of the affected eye may vary according to the size, duration, location and associated sub retinal cuff of fluid. In smaller holes it may vary from 20/25-20/40 while in larger holes it may be 20/80 to 20/400.

Corresponding author: Upma Awasthi, Vitreo-Retina Consultant, CL Gupta Eye Institute, India, Tel: 9910447258; E-mail: upma.awasthi2@gmail.com

Citation: Awasthi U & Grover R. (2020) Macular Hole. Ophthalmol Clin Res, 3(1): 124-130.

Copyright: ©2020 Awasthi U & Grover R. This is an open-access article distributed under the terms of the Creative Commons Attribution License, which permits unrestricted use, distribution, and reproduction in any medium, provided the original author and source are credited.

Amsler Grid is of great value in which the patient appreciates the bending/ waviness of lines and scotomas. On fundus examination, macular hole can be seen as well-defined excavation at the macula and choroidal reflex can be seen through it. In some cases, few yellowish deposits can be seen at the base of the hole suggestive of lipofuscin-laden macrophages. Additionally, surrounding sub retinal fluid can be appreciated, if present.

The Watzke-Allen test can be done on slit lamp and with direct ophthalmoscope. Herein, a thin narrow vertical beam of light is projected onto the macula and the patient is asked to perceive the light carefully and is asked to draw it on a paper. In a full thickness macular hole (FTMH), the line drawn is broken. Narrowing or thinning is suggestive of small MH, partial thickness MH or other differential diagnosis. A simple test using Maddox rod also reveals broken line suggestive of FTMH.

The laser aiming beam test is performed with 50 µm spot size laser-aiming beam. Test is considered positive when the patient fails to detect the aiming beam placed within the lesion but is able to detect it when placed onto normal retina. This test is useful in detection of small MH where Watzke-Allen sign is negative.

Table 1. The International vitreomacular traction study classification system for vitreomacular adhesion, traction and macular hole.

Vitreomacular adhesion	Size: focal (≤ 1500 µm) or broad (>1500 µm) Isolated or concurrent
VMT	Size: focal (≤ 1500 µm) or broad (>1500 µm) Isolated or concurrent
Full-thickness macular hole	Size: small (<250 µm), medium (>250 µm and ≤ 400 µm) or large (>400 µm) Status of vitreous: With or without VMT Cause: primary or secondary

OCT BASED PROGNOSIS

Various parameters as measured by OCT: base diameter, defect depth, central foveal thickness and perifoveal thickness help to prognosticate the subtypes of LMH. Hole form factor (HFF): It is defined as the ratio of the sum of the lengths of the two sides of macular hole to the base diameter. HFF between 0.9-1 has been correlated with better anatomical and functional outcome after surgery whereas HFF less than 0.5 are found to have poor prognosis (Figure 1) [12].

INVESTIGATIONS

Fundus fluorescein angiography (FFA)

FFA reveals transmitted fluorescence due to window defect at the area MH. FFA may also be helpful in prognostication; if done prior to surgery to look for the perfusion status of macula and anatomy of foveal avascular zone (FAZ).

Optical coherence tomography (OCT)

Only 28% of lamellar macular holes(LMH) diagnosed on OCT examination were detected clinically on fundus examination [9] On the basis of changes noted on OCT, International Vitreomacular Traction Study Group proposed a new classification system of MH (Table 1) [10]. This classification is of clinical importance because it determines the management and prognosis of macular holes. With the advent of ultra-high resolution OCT, LMH has been described as any of the following (1) an irregular foveal contour; (2) a break in the inner fovea; (3) separation of the inner from the outer foveal retinal layers, leading to an intraretinal split; (4) absence of a full thickness foveal defect with intact photoreceptors posterior to the area of foveal dehiscence [11].

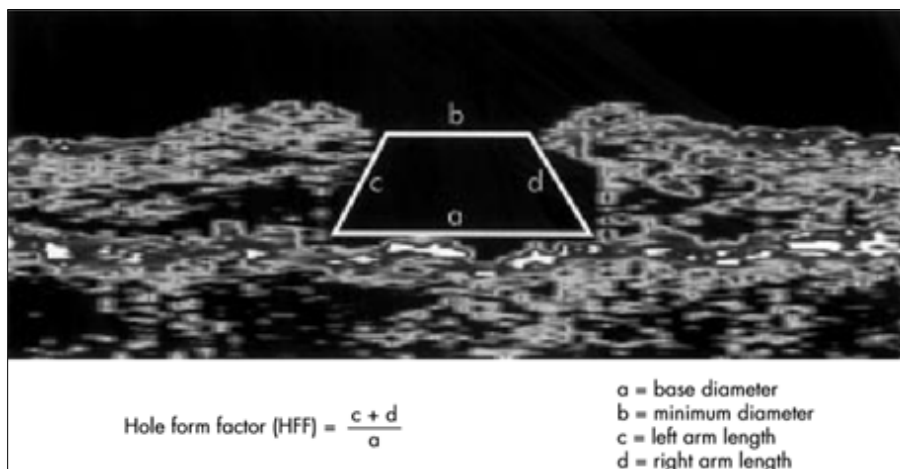


Figure 1. Hole form factor calculation for macular hole with raster OCT scan.

It also delineates presence and type of ERM that can decrease success rates if not dealt during surgery. Intraretinal cystic spaces shown in OCT are also considered as good prognostic factor.

FUNDUS AUTO FLUORESCENCE (FAF)

Increased FAF signal at the base of MH has been attributed to the presence of melanolipofuscin (LF) or changes in the metabolic activity of the retinal pigment epithelium (RPE).

Decreased FAF signal, suggesting the absent or degenerating RPE cells with reduced LF granule content [13]. Thus increased auto fluorescence is a good prognostic factor.

PATHOGENESIS

The pathogenesis is incompletely understood [14]. A number of theories have been put forward to explain the pathogenesis [15] (**Table 2**).

Table 2. Various proposed theories for macular hole formation.

Author	Year	Theory
Knapp	1869	Macular hole due to ocular trauma
Noyes	1871	Full thickness defect in retinal tissue due to trauma
Fuchs and Coats	1901, 1907	Cystoid degeneration
Lister	1924	Antero-posterior traction
Morgan and Schatz	1986	Involitional thinning and vascular theory
Gass	1995	Tangential traction forces
Tornambe	2003	Hydration theory

The major milestone in understanding of pathogenesis of MH was classification by Gass [1]. Green proposed that chronic low-grade traction due to ocular rotation stimulates cellular proliferation of Muller cells, astrocytes and RPE realigning vitreous fibres and redirecting the fractional force in tangential direction [16].

Studies done with OCT has showed that the initial stage of MH formation starts as a triangular elevation of outer photoreceptor layer(OPL) and its detachment from RPE due to fractional forces. The traction on the fovea occurring prior to anatomic changes to the fovea has been referred to as Stage 0 and may resolve without progression in 40-50% of

patients [17]. Ezra published an OCT documented study suggesting that failure of normal age-related separation of cortical vitreous from posterior pole as a result of an abnormally tenacious attachment to the fovea leads to MH formation [18].

DIFFERENTIAL DIAGNOSIS

The varied presentation of lamellar macular defect may mimic a MH. Lamellar macular defects were categorized into three different subtypes based on their OCT appearance: LMH, macular pseudo holes (MPH) and foveal pseudo cysts (FP) [19].

Lamellar holes have thin fovea resulting from avulsion of inner layer of macula.

A macular pseudo hole results from the centripetal contraction of an ERM that subsequently leads to verticalisation of the foveal slopes and a sharply punched out defect [20].

FP is described as a precursor to MH or LMH formation due to direct vitreomacular traction (VMT) [9] ERM can also result in avulsion forces leading to the formation of pseudo cyst [21].

It has been found that MPH have smaller diameter and thicker central foveal tissue, therefore they have better visual acuity than LMH and FP whereas both LMH and FP are shown to have deeper and wider intraretinal split and also thin central foveal tissue [19].

MANAGEMENT

FTMH were once considered untreatable and surgery was indicated once extensive RD occurred [22,23]. In 1991, Kelly and Wendel first demonstrated a surgical procedure to close idiopathic MH with good functional outcome [24]. Later several adjuncts like TGF- β , autologous platelet concentrate, bovine thrombus, laser barrage, etc. [25,26], currently indications of surgery are as follows:

- A. On the basis of macular hole staging and pre-op visual acuity.
 1. FTMH with stage II and above.
 2. Patients with stage III and IV with visual acuity of 6/18 or below: these patients readily gain 2 or more line improvement after surgery.
 3. Stage II macular holes with visual acuity ranges from 6/12 to 6/18 (20/40-20/60).
 4. Patients with visual acuity of >6/12 presenting with minimum symptoms like metamorphopsia and smaller hole size rarely requires surgery. Freeman et al observed spontaneous regression in 4% of all cases. Therefore, these patients can be followed up [27].
- B. As per imaging modalities.

OCT based parameters and FAF are important to prognosticate and to plan the surgery.

SURGICAL OBJECTIVE OF MACULAR HOLE SURGERY

Surgical objective of MH surgery is twofold; first to relieve tractional forces; second to activate reparative healing mechanism [28,29].

Surgical technique

Pars Plana Vitrectomy with internal limiting membrane (ILM) peel with fluid gas exchange (FGE) is the accepted technique. Earlier, 20G system and currently 27G, 25G and 23G systems have been employed [30]. Brilliant blue G (BBG) dye is used at concentration of 0.25 mg/ml for staining ILM. This dye does not stain ERM thus after removal of ERM, dye should be re-injected to look for residual ILM. This method is called as double staining and ensures complete removal of ILM [31]. Lifting of ILM has been a challenge as well as traumatic to retina [32]. Newer instruments like silicone tipped cannula; diamond duster and finesse flex loop have made ILM peeling convenient and less traumatic.

Recently many techniques have been proposed for large and refractory MH; fovea sparing ILM, free flap, inverted ILM flap with and without PFCL, cabbage technique [33-37]. All these techniques aim at stuffing macular hole with ILM. This is postulated that this ILM will serve as scaffold for retinal tissue to grow upon. There are various reports that these flaps get dislocated with fluid current and during fluid air exchange. Autologous retinal transplant has also been used to plug macular hole also provides scaffold and plugs macular hole [38].

To peel or not to peel

Studies favoring ILM peeling state that peeling removes the template upon which the glial cells proliferate. Also, it removes the tangential traction. ILM peeling serves to increase MH edge mobility and reduce MH diameter [29].

Studies which do not advocate ILM peeling postulated that removal of ILM injures the Müller cell footplates and trigger reparative gliosis [32].

ILM peeling has shown higher rate (92%) of primary closure of MH as compared with eyes undergoing MH repair without ILM peeling (82%). Late reopening of hole was also found to be higher in no ILM peeling group when compared with ILM peeling group (7% vs. 0.6 %) [39].

To posture or not to posture is still a controversial issue. Studies have reported strict face down posturing (FDP) for at least a week (24). It is thought to aid hole closure due to the buoyant force of intraocular gas bubble [40]. The gas bubble keeps the edges of macular hole dry and provides scaffold for glial cell proliferation [38,41]. Also surface tension is constant around the bubble's interface with the retina as long as volume of gas is 2/3rd to 3/4th of vitreous cavity [42].

But successful hole closure without FDP as reported in Tornamby Pilot study supports the approach avoiding FDP [43]. Various other studies favored no FDP or a minimum of one day FDP and showed 90% anatomical and functional success rate [44,45].

Endotamponading agents

In original description of macular hole surgery, use of non-expandable gas of SF₆ with 1 week FDP was indicated [23]. In patients who require long-term tamponade, cannot maintain positioning or have to travel by air, silicone oil can be opted. But its removal requires another surgery and also anatomical closure is found to be only 65% as compared with C3F₈ gas which has 91% success rate [46]. C3F₈ and densiron 68 share advantage of having longer effect and both do not require positioning. Densiron-68 is a mixture of silicone oil and amphiphilic perfluorohexyloctane, which facilitates better contact with the retina compared with standard silicone oil [47]. Vitrectomy and air tamponade combined with 1-3 day facedown positioning produced an excellent rate of macular hole closure [42,48].

Types of macular hole closure

On the basis of postoperative OCT findings, closed macular holes have been classified into two groups:

Type 1: MH is closed without foveal defect of the neurosensory retina.

Type 2: Foveal defect of the neurosensory retina persists postoperatively although the whole rim of the MH is attached to the underlying RPE with flattening of the cuff [49].

Complications of surgery

1. Swelling of the arcuate retinal nerve fiber layer (SANFL): The SANFL does not appear to impact the final BCVA and can be expected to disappear in about 3 months [50]. There are two hypotheses regarding the cause of SANFL [51]. The first hypothesis is that surgical forceps cause direct damage to the retina when grasping the ILM while the second is that ILM peeling causes damage to the Müller cell endplates that are attached to the ILM [51].

Dissociated optic nerve fiber layer (DONFL), which is similar to the SANFL is observed as small, spindle-shaped splitting adjacent nerve fiber bundles on SDOCT [52] Not all patients who undergo ILM peeling will present with the DONFL postoperatively, and there have been no significant differences observed between eyes with and those without the DONFL with respect to BCVA or macular sensitivity. The reason for DONFL presentation is also unclear, although some authors speculated that the DONFL is caused by irregularly distributed Müller cells following ILM peeling in regions that show a higher density of nerve fiber bundles in the RNFL.

2. Retinal breaks: The incidence of retinal break formation during macular hole surgery is 5.5% [53].
3. Retinal detachment.

4. Gas cataract: The cataract progression following macular hole surgery is found to be 64% within first year. Therefore these days it is advocated to undergo combined macular hole and cataract surgery. Lens extraction also allows a more complete Vitrectomy [54].

CONCLUSION

Macular hole can be caused by several factors. Not all macular holes need surgical intervention. OCT has redefined the macular hole and its prognostication. Also with the invention of MIVS, surgical techniques and functional outcomes has been improved dramatically.

REFERENCES

1. Gass JD (1995) Reappraisal of biomicroscopic classification of stages of development of a macular hole. *Am J Ophthalmol* 119: 752-759.
2. Sen P, Bhargava A, Vijaya L, George R (2008) Prevalence of idiopathic macular hole in adult rural and urban south Indian population. *Clin Exp Ophthalmol* 36: 257-260.
3. Aaberg TM (1970) Macular holes: A review. *Surv Ophthalmol* 15: 139-162.
4. Brown GC (1988) Macular hole following rhegmatogenous retinal detachment repair. *Arch Ophthalmol* 106: 765-766.
5. Cohen SM, Gass JDM (1994) Macular hole following severe hypertensive retinopathy. *Arch Ophthalmol* 112: 878-879.
6. Flynn HW (1994) Macular hole surgery in patients with proliferative diabetic retinopathy. *Arch Ophthalmol* 112: 877-878.
7. Wagner-Schuman M, Dubis AM, Nordgren RN (2011) Race- and sex-related differences in retinal thickness and foveal pit morphology. *Invest Ophthalmol Vis Sci* 52: 625-634.
8. Bronstein MA, Trempe CL, Freeman HM (1981) Fellow of eyes with macular holes. *Am J Ophthalmol* 92: 757-7561.
9. Haouchine B, Massin P, Gaudric A (2001) Foveal pseudocyst as the first step in macular hole formation: A prospective study by optical coherence tomography. *Ophthalmology* 108: 15-22.
10. Duker JS, Kaiser PK, Binder S, de Smet MD, Gaudric, et al. (2013) The International Vitreomacular Traction Study Group classification of vitreomacular adhesion, traction and macular hole. *Ophthalmology* 120: 2611-2619.
11. Witkin AJ, Ko TH, Fujimoto JG, Schuman JS, Bauml CR, et al. (2006) Redefining lamellar holes and the vitreomacular interface: An ultrahigh-resolution optical

- coherence tomography study. *Ophthalmology* 113: 388-397.
12. Ullrich S, Haritoglou C, Gass C, Schaumberger M, Ulbig MW, et al. (2002) Macular hole size as a prognostic factor in macular hole surgery. *Br J Ophthalmol* 86: 390-393.
 13. Schmitz-Valckenberg S, Fleckenstein M, Scholl HP, Holz FG (2009) Fundus auto fluorescence and progression of age-related macular degeneration. *Surv Ophthalmol* 54: 96-117.
 14. Kakehashi A, Schepens CL, Trempe CL (1996) Vitreomacular observations II. Data on the pathogenesis of idiopathic macular breaks. *Graefes Arch Clin Exp Ophthalmol* 234: 425-433.
 15. Smiddy WE, Flynn HW Jr (2004) Pathogenesis of macular holes and therapeutic implications. *Am J Ophthalmol* 137: 525-537.
 16. Green WR (2006) The macular hole. *Histopathological studies. Arch Ophthalmol* 124: 317-321.
 17. Michalewska Z, Michalewski J, Sikorski BL, Kałuzny JJ, Wojtkowski M, et al. (2009) A study of macular hole formation by serial spectral optical coherence tomography. *Clin Exp Ophthalmol* 37: 373-383.
 18. Ezra E (2001) Idiopathic full thickness macular hole: Natural history and pathogenesis. *Br J Ophthalmol* 85: 102-109.
 19. Chen JC, Lee LR (2008) Clinical spectrum of lamellar macular defects including pseudo holes and pseudo cysts defined by optical coherence tomography. *Br J Ophthalmol* 92: 1342-1346.
 20. Allen AW, Gass JD (1976) Contraction of a perifoveal epiretinal membrane simulating a macular hole. *Am J Ophthalmol* 82: 684-689.
 21. Haouchine B, Massin P, Tadayoni R, Erginay A, Gaudric A (2004) Diagnosis of macular pseudoholes and lamellar macular holes by optical coherence tomography. *Am J Ophthalmol* 138: 732-739.
 22. Gass JDM (1997) Vitreofoveal separation and lamellar hole formation. In: Gass JDM, editor. *Stereoscopic atlas of macular diseases: diagnosis and treatment*. 4th Edn. St Louis: CV Mosby, pp: 926-927.
 23. Margherio RR, Schepens CL (1972) Macular holes II. Management. *Am J Ophthalmol* 74: 233-240.
 24. Kelly NE, Wendel RT (1991) Vitreous surgery for idiopathic macular holes. *Arch Ophthalmol* 109: 654-659.
 25. Min WK, Lee JH, Ham DI (1999) Macular hole surgery in conjunction with endolaser photocoagulation. *Am J Ophthalmol* 127: 306-311.
 26. Schocket SS, Lakhanpal V, Miao XP (1987) Treatment of macular holes with the argon laser. *Trans Am Ophthalmol Soc* 85: 159-175.
 27. Freeman WR, Azen SP, Kim JW, el-Haig W, Mishell DR, et al. (1997) Vitrectomy for the treatment of full-thickness stage 3 or 4 macular holes - Results of a multicentred randomized clinical trial. *Arch Ophthalmol* 115: 11-21.
 28. Smiddy WE, Feuer W, Cordahi G (2001) Internal limiting membrane peeling in macular hole surgery. *Ophthalmology* 108: 1471-1478.
 29. Brooks HL Jr (2000) Macular hole surgery with and without internal limiting membrane peeling. *Ophthalmology* 107: 1939-1948.
 30. Rizzo S, Belting C, Creasti F, Genovesi-Ebert F (2007) Sutureless 25-gauge vitrectomy for idiopathic macular hole repair. *Graefes Arch Clin Exp Ophthalmol* 245: 1437-1440.
 31. Shimada H, Nakashizuka H, Hattori T, Mori R, Mizutani Y, et al. (2009) Double staining with brilliant blue G and double peeling for epiretinal membranes. *Ophthalmology* 116: 1370-1376.
 32. Almony A, Nudleman E, Shah GK, Blinder KJ, Elliott DB, et al. (2012) Techniques, rationale and outcomes of internal limiting membrane peeling. *Retina* 32: 877-891.
 33. Shimada N, Sugamoto Y, Ogawa M, Takase H, Ohno-Matsui K (2012) Fovea-sparing internal limiting membrane peeling for myopic traction maculopathy. *Am J Ophthalmol* 154: 693-701.
 34. Morizane Y, Shiraga F, Kimura S, Hosokawa M, Shiode Y, et al. (2014) Autologous transplantation of the internal limiting membrane for refractory macular holes. *Am J Ophthalmol* 157: 861-869.e1.
 35. Michalewska Z, Michalewski J, Adelman RA, Nawrocki J (2010) Inverted internal limiting membrane flap technique for large macular holes. *Ophthalmology* 117: 2018-2025.
 36. Shin MK, Park KH, Park SW, Byon IS, Lee JE, et al. (2014) Perfluoro-n-octane-assisted single-layered inverted internal limiting membrane flap technique for macular hole surgery. *Retina* 34: 1905-1910.
 37. Aurora A, Seth A, Sanduja N (2017) Cabbage leaf inverted flap ILM peeling for macular hole: A novel technique. *Ophthalmic Surg Lasers Imaging Retina* 48: 830-832.
 38. Grewal DS, Mahmoud TH (2016) Autologous neurosensory retinal free flap for closure of refractory myopic macular holes. *JAMA Ophthalmol* 134: 229-230.

39. Kumagai K, Furukawa M, Ogino N, Uemura A, Demizu S, et al. (2004) Vitreous surgery with and without internal limiting membrane peeling for macular hole repair. *Retina* 24: 721-727.
40. Isomae T, Sato Y, Shimada H (2002) Shortening the duration of prone positioning after macular hole surgery-Comparison between 1 week and 1 day prone positioning. *Jpn J Ophthalmol* 46: 84-88.
41. Dhawahir-Scala FE, Maino A, Saha K, Mokashi AA, McLauchlan R, et al. (2008) To posture or not to posture after macular hole surgery. *Retina* 28: 60-65.
42. Thompson JT, Smiddy WE, Glaser BM, Sjaarda RN, Flynn HW Jr (1996) Intraocular tamponade duration and success of macular hole surgery. *Retina* 16: 373-382.
43. Tornambe PE, Poliner LS, Grote K (1997) Macular hole surgery without face-down posturing. A pilot study. *Retina* 17: 179-185.
44. Madreperla SA, Geiger GL, Funata M, de la Cruz Z, Green WR (1994) Clinicopathologic correlation of macular hole treated by cortical vitreous peeling and gas tamponade. *Ophthalmology* 101: 682-686.
45. Simcock PR, Scalia S (2018) Phacovitrectomy without prone posture for full thickness macular holes. *Br J Ophthalmol*; 85: 1316-1319.
46. Lai JC, Stinnett SS, McCuen BW (2003) Comparison of silicone oil versus gas tamponade in the treatment of idiopathic full thickness macular hole. *Ophthalmology* 110: 1170-1174.
47. Lappas A, Heinrich Foerster AM, Kirchhof B (2009) Use of heavy silicone oil Densiron-68 in the treatment of persistent macular holes. *Acta Ophthalmol* 87: 866-870.
48. Eckardt C, Eckert T, Eckardt U, Porkert U, Gesser C (2008) Macular hole surgery with air tamponade and optical coherence tomography-based duration of facedown positioning. *Retina* 28: 1087-1096.
49. Kang SW, Ahn K, Ham DI (2003) Types of macular hole closure and their clinical implications. *Br J Ophthalmol* 87: 1015-1019.
50. Pichi F, Lembo A, Morara M, Veronese C, Alkabes M, et al. (2014) Early and late inner retinal changes after inner limiting membrane peeling. *Int Ophthalmol* 34: 437-446.
51. Clark A, Balducci N, Pichi F (2012) Swelling of the arcuate nerve fiber layer after internal limiting membrane peeling. *Retina* 32: 1608-1613.
52. Spaide RF (2102) Dissociated optic nerve fiber layer appearance after internal limiting membrane removal is inner retinal dimpling. *Retina* 32: 1719-1726.
53. Sjaarda RN, Glaser BM, Thompson JT (1995) Distribution of iatrogenic retinal break in macular hole surgery. *Ophthalmology* 102: 1387-1392.
54. Duker JS, Wendel R, Patel AC (1994) Late re-opening of macular holes after initially successful treatment with vitreous surgery. *Ophthalmology* 101: 1373-1378.