

A Case of Oblique Occipital Sinus and Superior Sagittal Sinus Early Duplication and Fenestration Surgical Implications

Monique Boukobza*, Carsten Ehmer and Jean-Pierre Laissy

*Department of Radiology, Assistance Publique-Hôpitaux de Paris, Bichat Hospital, 75018, Paris, France.

Received March 21, 2018; Accepted April 19, 2018; Published August 28, 2018

ABSTRACT

Many anatomical variations of the confluence of sinuses and of occipital sinus (OS) have been reported. We observed in a 26 year old woman the left limb of a prematurely divided superior sagittal sinus (SSS) draining into an oblique occipital sinus (OOS).

The OOS drained with a bilateral distal sigmoid sinus (SiS). The right limb of the SSS drained laterally into the right transverse sinus (TS); the straight sinus (SS) drained also into the right TS. The left TS was very hypoplastic. A fenestration was present at the right limb of the SSS. The reported case shows an unusual venous sinus variant of split SSS associated with an OOS.

Occurrence of this variation indicates the need of examination of venous sinus anatomy for preoperative evaluation of supra and infra-tentorial surgery and especially in case of anterior/posterioropetrosal as well as pre/retro sigmoid, occipital and pineal approaches and for cases in which occipital screw fixation is necessary.

Keywords: Occipital sinus, Oblique occipital sinus, Superior sagittal sinus duplication, Dural venous sinuses, Superior sagittal sinus fenestration.

INTRODUCTION

Many anatomical variations of the confluence of the sinuses (torcular herophili) and of the occipital sinus have been described by angiographic studies, CT-venography and MR-venography and various patterns and classifications have been reported [1-5]. Variation of the dural venous sinuses may result in inadequate neuroradiological interpretation or complications during surgical procedures. Knowledge of this possible anatomical variation is essential to prevent surgical complication.

We report concomitant venous sinuses variations in an unusual configuration, including oblique occipital sinus (OOS) and superior sagittal sinus (SSS) duplication and fenestration.

CASE

A 26 year old woman (16th week of pregnancy) without past medical history, presented with persistent headache since 3 days. Neurological and general physical examinations were normal. Examination of the fundi, blood tests and CSF were unremarkable (CSF opening pressure: 10 cm H₂O).

To exclude cerebral venous thrombosis (CVT), a MRI examination was done subsequently (1.5T, GE Medical System). MRI excluded intracranial lesion and intracranial hyper or hypotension. MR-Venography (MRV) without exogeneous contrast (*inhance technique*: The 3D-sequence Inhance Inflow-IR (IFIR) is a technique that combines sequence ASL (arterial spin labeling) with SSFP (steady state free precession) [6] did not reveal any stenosis or thrombosis of venous structures but revealed rather unusual pattern of venous sinuses variations.

Corresponding author: Dr. Monique Boukobza. Department of Radiology, Assistance Publique-Hôpitaux de Paris, Bichat Hospital, 46 rue Henri Huchard, 75018, Paris, France, Tel: +33 6 24 65 29 32; Fax: + 33 1 40 25 83 05; E-mail: m.boukobza@orange.fr

Citation: Boukobza M, Ehmer C & Laissy JP. (2018) A Case of Oblique Occipital Sinus and Superior Sagittal Sinus Early Duplication and Fenestration Surgical Implications. J Neurosurg Imaging Techniques, 3(2): 180-183.

Copyright: ©2018 Boukobza M, Ehmer C & Laissy JP. This is an open-access article distributed under the terms of the Creative Commons Attribution License, which permits unrestricted use, distribution, and reproduction in any medium, provided the original author and source are credited.

The SSS presented a very high division and duplicated, bifurcating into 2 co-dominant SSS. The right SSS presented a fenestration and the left SSS, coursing along the midline, drained into a large OOS. The OOS drained with a bilateral distal sigmoid sinus (SiS) (**Figures 1a-1c**).

The straight sinus (SS) emptied laterally into the right transverse segment (RTS) of the lateral sinus (LS) while the

right SSS drained into the same sinus more externally (**Figures 1a-1d**). Furthermore, the left transverse sinus (LTS) was markedly hypoplastic. The left sigmoid sinus was well-formed but was non-dominant, compared to the opposite sinus. The right SSS presented a fenestration (**Figures 1a-1d**).

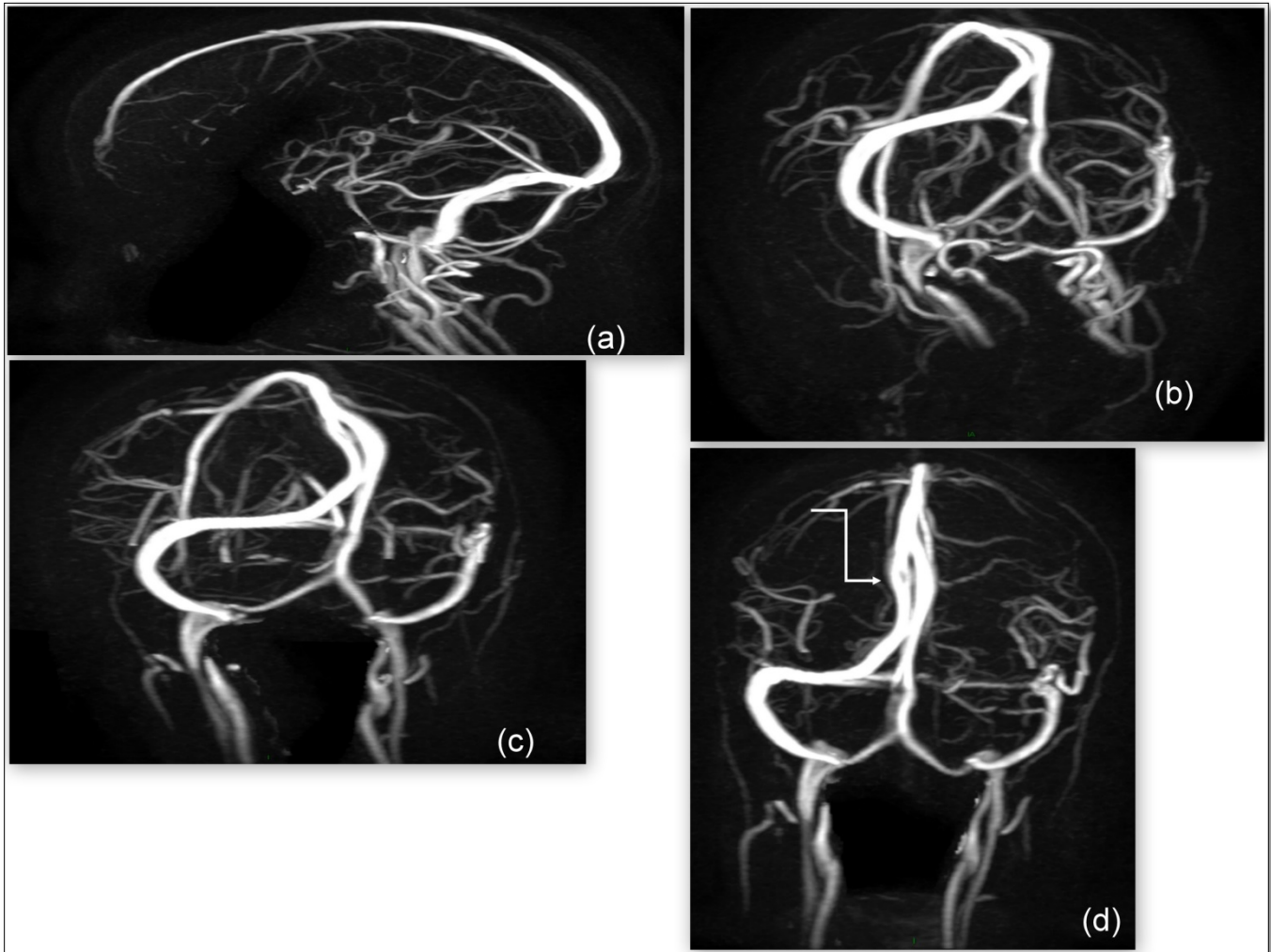


Figure 1. MR-venography: (a) Sagittal projection shows the OOS and its two branches. (b-d) The left co-dominant branch of the early duplicated superior sagittal sinus courses medially and drains into the oblique occipital sinus (b). The oblique occipital sinus drains bilaterally into the distal sigmoid sinus/jugular bulb (b-d). The right branch of superior sagittal sinus drains laterally into the right transverse sinus. The left transverse sinus is hypoplastic (b-d). The straight sinus drains into the right transverse sinus (c). Arrow indicates the fenestration of the right branch of superior sagittal sinus (d).

DISCUSSION

The OS usually communicates with the confluence of sinuses cranially and with the vertebral venous plexus or the marginal sinus at the foramen magnum. There is a wide variation of the OS. An OS draining into a Si S has been termed the OOS [7]. The prevalence of the OOS is low: 2.3% in the recent study of Shin [8].

Many variations of the course of the OOS have been described [1-5,8].

The OOS has been recently classified into 3 types, depending on hypoplasia or aplasia of lateral sinus [8]. The OOS may drain either bilaterally, in a hypoplastic TS on one side (9.7%) or in a hypoplastic TS on both sides (4.9%).

In the current case, the OOS drained bilaterally. The left LS were non-dominant with a transversal hypoplastic segment.

In this case, the OOS corresponds to the type IICa as defined by Shin [8]. Nonetheless, the unusual feature in our case consists in an OOS coursing along with the left limb of a prematurely divided SSS.

The association in a young woman with an uneventful pregnancy and without history of migraine or headaches and TS diameter reduction would have been able to evoke the diagnosis of idiopathic intracranial hypertension (IIH). However, the presence of normal intracranial pressure (CSF opening pressure: 10 cm H₂O) and the absence of MRI indirect signs of IIH (empty sellae, flattening of posterior sclera, prominence of peri-optic nerve CSF) must not lead to a false positive diagnosis of IIH and to inappropriate investigations as invasive manometry to determine the sinus pressure gradient. When a sinus stenosis with a pressure gradient from pre- to post-stenosis is documented, venous sinus stenting should be required [9-11].

Futhermore, authors [1-8,13] assumed to large persistent OOS a possible role of compensatory pathway in cases of hypoplastic TS and/or SiS. In the current case, the LTS was strikingly hypoplastic but the left SiS had a normal lumen.

Finally, when a high division of the SSS occurs, firstly, the right and left limbs usually drain into the same side TS, when dominant flow exists from both the SSS, secondly the SS may drain into the left or the right TS. In the reported case, the SS drains into the right TS, and the left TS is very hypoplastic. This SS drainage configuration is similar to the type IIC of the Torcular herophili classification described by Gökçe [5]. It has also been reported than in case of high division of the SSS, the straight sinus may drain into the OS [2].

The particularity of our case is the pattern of left SSS limb draining into the OOS which is very “unusual”. Occurrence of this pattern indicates the need of preoperative venous radiological evaluation of sinus anatomy to avoid either a direct or a remote brain infarction during supra and infratentorial surgery and especially in case of anterior/posterior petrosal as well as pre/retrosigmoid, occipital and pineal approaches [14-16] and in case of surgical procedures of the occipital area as occipital screw fixation [17].

CONCLUSION

An unusual venous sinus configuration of split SSS associated with OOS is reported.

Neurosurgeons and neuroradiologists should be aware of such rare aspect of the venous sinuses variant. Careful examination of venous anatomy seems essential for the diagnosis of vascular pathologies and for supra and infratentorial surgery and especially in case of anterior/posterior petrosal as well as pre/retrosigmoid, occipital and pineal approaches and for cases in which occipital screw fixation is necessary.

ACKNOWLEDGEMENT

The authors express special thanks to Dr Salvatore Chibbaro for his support.

REFERENCES

1. Dora F, Zileli T (1980) Common variations of the lateral and occipital sinuses at the confluens sinuum. *Neuroradiology* 20: 23-27.
2. Curé JK, Van Tassel P, Smith MT (1994) Normal and variant anatomy of the dural sinuses. *Semin Ultrasound CT MR* 15: 499-519.
3. Kobayashi K, Suzuki M, Ueda F, Matsui O (2006) Anatomical study of the occipital sinus using contrast-enhanced magnetic resonance venography. *Neuroradiology* 48: 373-379.
4. Tubbs RS, Ammar K, Liechty P, Wellons JC, et al. (2006) The marginal sinus. *J Neurosurg* 104: 429-431.
5. Gökçe E, Pınarbaşı T, Acu B, Fırat MM, Erkorkmaz Ü (2014) Torcular Herophili classification and evaluation of dural venous sinus variations using digital subtraction angiography and magnetic resonance venographies. *Surg Radiol Anat* 36: 527-536.
6. LópezGarcía JA, Perez Brito CN, Gonzalez Garcia I, Valles Gonzalez H, Diaz Romero JF (2013) Non-enhanced MR Angiography: 3D Inhance Inflow IR. Technique and its clinical applications. Presented at ECR 2013/C-0111.
7. Lang J (1991) The floor of the posterior cranial fossa. In: clinical anatomy of the posterior cranial fossa and its foramina. Thieme, NY.
8. Shin HS, Choi DS, Baek HJ, Choi HC, Choi HY, et al. (2016) The oblique occipital sinus: anatomical study using bone subtraction 3D CT venography. *Surg Radiol Anat* 39: 619-628.
9. Albuquerque FC, Dashti SR, Hu YC, Newman CB, Tebeb M, et al. (2011) Intracranial venous sinus stenting for benign intracranial hypertension: Clinical indications, technique and preliminary results. *World Neurosurg* 75: 648-652.
10. Bidot S, Saindane AM, Peragallo JH, Bruce BB, Newman NJ, et al. (2015) Does bilateral transverse cerebral venous sinus stenosis exist in patients without increased intracranial pressure. *Neuroophthalmol* 35: 400-411.
11. Bidot S, Saindane AM, Peragallo JH, Bruce BB, Newman NJ, et al. (2015) Brain imaging in idiopathic intracranial hypertension. *J Neuroophthalmol* 35: 400-411.
12. Kelly LP, Saindane AM, Bruce BB, Ridha MA, Riggeal BD, et al (2013) Does bilateral transverse cerebral

venous sinus stenosis exist in patients without increased intracranial pressure? *Clin Neurol Neurosurg* 115: 1215-1219.

13. Kobayashi K, Matsui O, Suzuki M, Ueda F (2006) Anatomical study of the confluence of the sinuses with contrast-enhanced magnetic resonance venography. *Neuroradiology* 48: 307-311.
14. da Silva EB Jr, Leal AG, Milano JB, da Silva LF Jr, Clemente RS, et al. (2010). Image-guided surgical planning using anatomical landmarks in the retrosigmoid approach. *Acta Neurochir* 152: 905-910.
15. Raza SM, Quinones-Hinojosa A (2011) The extended retro sigmoid approach for neoplastic lesions in the posteriorfossa: Technique modification. *Neurosurg Rev* 34: 123-129.
16. Kizmazoglu C, Lee JH, Sade B (2017) Dominant occipital sinus complicating surgery of a fourth ventricular mass. *World Neurosurg* 97: 753.e17-753.e19.
17. Izeki M, Neo M, Fujibayashi S, Takemoto M, Otsuki B et al. (2013) Utility of the analysis of intracranial venous sinuses using preoperative computed tomography venography for safe occipital screw insertion. *Spine* 38: E1149-E1155.