

Anaesthetic Considerations in a Child with Macroglossia due to Lymphangioma - A Case Report

Mamta Bhardwaj*, Kiranpreet, Teena Aggarwal, Vasudha and Savita Saini

*Department of Anesthesiology and Critical Care, Pt. B.D. Sharma PGIMS at University of Health Sciences, Rohtak, Haryana, India.

Received May 06, 2019; Accepted May 31, 2019; Published August 08, 2019

INTRODUCTION

A child with diffusely enlarged tongue due to lymphangioma presents a unique challenge to the anesthesiologists. Anesthetic concerns include difficulty in mask ventilation, intubation, bleeding, extrinsic and intrinsic pressure on the airway causing distortion and enlarged upper. Anesthetic management is often challenging in such patients because of difficult mask ventilation and airway management. We report a case of lymphangioma of tongue leading to macroglossia in a child. Anesthetic concerns including airway management, alternative airway equipment and possible complications are discussed.

CASE REPORT

A 2 year old male child weighing 10 kg reported to pediatric surgery with generalized swelling of tongue. Parents noticed a pea sized swelling over tongue immediately after birth. They consulted some private physician and took some medicines but no response was observed. Increase in size of the swelling was insidious. Child was delivered at full term in a village hospital. There was no significant antenatal history. Parents gave a history of progressive difficulty in feeding the child but there was no breathing difficulty. Local examination revealed an enlarged tongue protruding and keeping the mouth permanently open (**Figures 1 and 2**). The oro-dental hygiene was poor with teeth impressions on the surface of tongue. Mouth opening, inter-incisor gap and Mallampatti grading could not be elicited due to the enlarged tongue. On palpation the tongue was non tender and firm in consistency. Patient had a swelling of 2 × 4 cm in right parotid region raising the ear lobe. No other congenital abnormalities were present. All routine investigations were within normal limits. Ultrasound showed hypertrophy of tongue with multiple cystic areas seen in parotid and submandibular gland. Magnetic resonance imaging revealed enlargement of tongue in anterior 2/3 region and hyper intensity on T2W and T1W images. It showed heterogeneous enhancement on CEMR. Lymphangiomas seen in bilateral parotid and submandibular glands with enlarged right parotid gland. Rest of the systemic

examination was normal. Child was pre-medicated with intranasal midazolam 0.5 mg 30 min prior to shifting to the operation theatre. On arrival to the operating room, routine monitors, including a pulse oximeter, non-invasive blood pressure cuff and electrocardiographic monitor were applied. Difficult airway cart, and tracheostomy set were arranged. Suture was kept ready. It was planned to pull the tongue with suture if obstruction occurred. Child was induced with sevoflurane 2-6% in increments using size 3 transparent facemask (**Figure 3**). We used bigger size face mask, i.e., size 3 to oxygenate and ventilate the patient, as we were unable to maintain proper seal with smaller mask because of large protruding tongue. It was difficult to assist ventilation in supine position so he was turned to right lateral position. Intravenous line was secured with 24 G cannula in right hand. Injection glycopyrrolate 50 µg and fentanyl 20 µg were given IV. After checking for ability to ventilate, check laryngoscopy done and succinylcholine 20 mg given IV. Child was successfully intubated orally with 4.5 mm uncuffed tube in a single attempt. Anesthesia was maintained with N₂O 67%, oxygen 33%, isoflurane 1% and atracurium. Injection paracetamol 150 mg IV, hydrocortisone 20 mg IV was given intraoperatively. The inverted V shaped anterior half of the tongue was removed. The tumor had large cystic spaces filled with lymph like fluid. After completion of surgery, trachea was extubated without any adverse event. The intra-operative and recovery period were uncomplicated and baby was shifted to the ward after being observed for 2 h in the recovery room. Child's

Corresponding author: Dr. Mamta Bhardwaj, Department of Anesthesiology and Critical Care, Pt. B.D. Sharma PGIMS at University of Health Sciences, Rohtak, Haryana, India, Tel: 0911262-266676; E-mail: drbmamta@gmail.com

Citation: Bhardwaj M, Kiranpreet, Aggarwal T, Vasudha & Saini S. (2019) Anaesthetic Considerations in a Child with Macroglossia due to Lymphangioma - A Case Report. Int J Anaesth Res, 2(2): 52-55.

Copyright: ©2019 Choubey N, Dwivedi PK, Jena R & Chopra A. This is an open-access article distributed under the terms of the Creative Commons Attribution License, which permits unrestricted use, distribution, and reproduction in any medium, provided the original author and source are credited.

stay in the hospital was uneventful and was discharged home after 5 days.

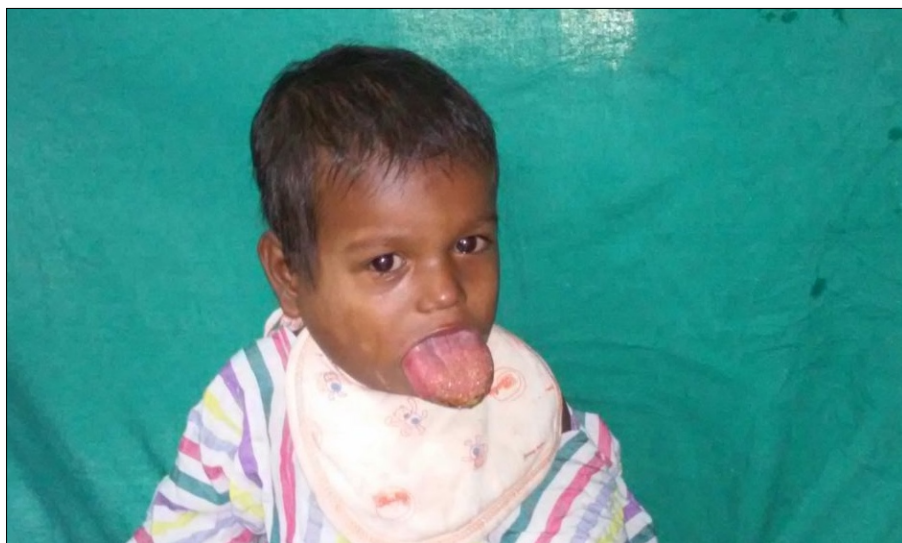

Figure 1. A child with lymphangioma of tongue.

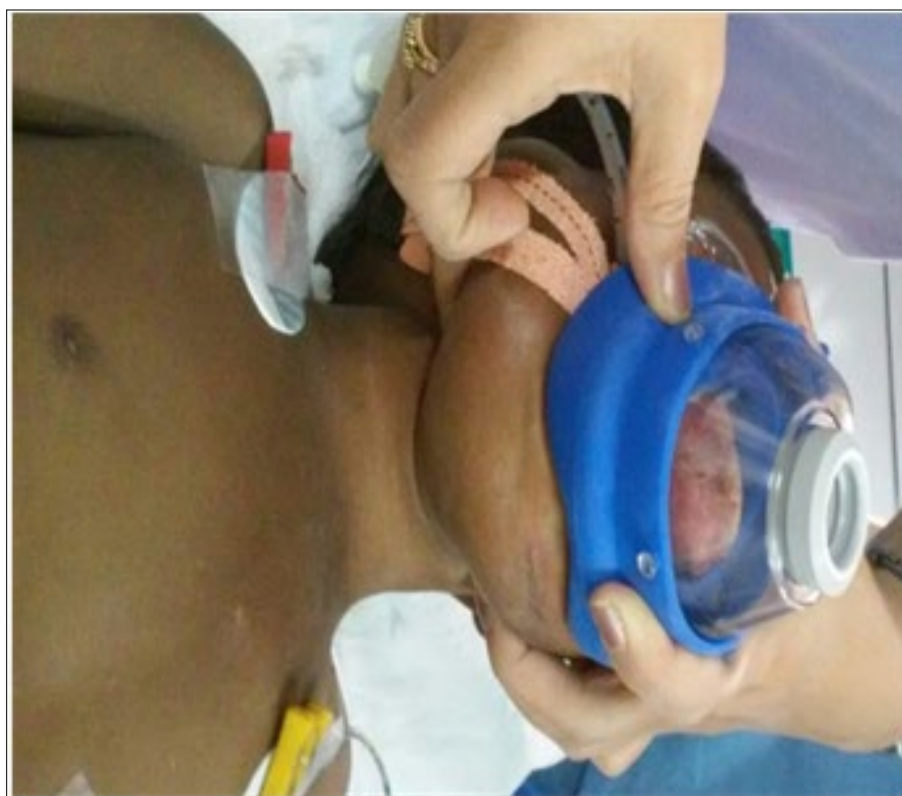

Figure 2. Mask ventilation with size 3 mask.

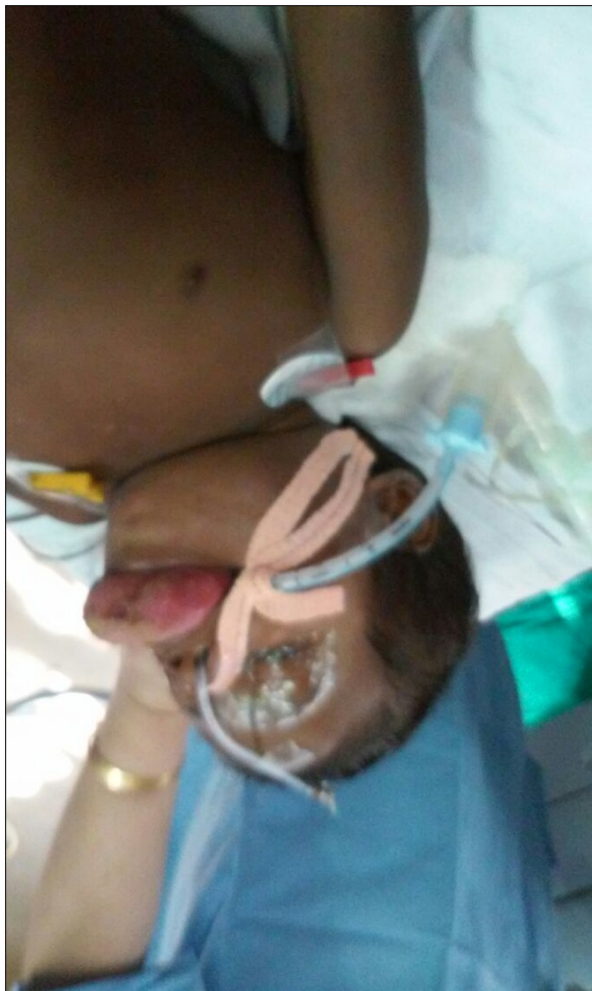


Figure 3. Child with ETT *in situ*.

DISCUSSION

Lymphangiomas are hamartomatous, congenital malformations of the lymphatics. They result from sequestration of lymphatic tissue that has retained its potential for growth and do not communicate with other lymphatic tissue [1]. Lymphangioma can be classified into four categories: Lymphangioma simplex (lymphangioma circumscriptum): composed of small, thin-walled lymphatics. Cavernous lymphangioma: comprised of dilated lymphatic vessels with surrounding adventitia. Cystic lymphangioma (cystic hygroma): consisting of huge, macroscopic lymphatic spaces with surrounding fibrovascular tissues and smooth muscles. Cervical lesions in a child can cause dysphagia and airway obstruction which is rare in adults [2].

The anterior two-thirds of the dorsal surface of tongue is the most common site for intra-oral lymphangiomas leading to macroglossia [3]. These patients tend to have speech disturbances, poor oral hygiene and bleeding from tongue associated with oral trauma [4]. In the present case, the

swelling was noticed since birth and reached the current size as appropriate treatment was not taken. Macroglossia resulted in lesions on the dorsal surface of tongue, improper phonation and poor oral hygiene.

Awake intubation may be a first option but is not easily performed in children since cooperation is quite essential. Adult fiber optic bronchoscopes (FOB) have an outer diameter of around 3.5-4.0 mm and thus can take realistically a size 4.0-4.5 mm endotracheal tube loaded onto them. Ultra-thin fiberoscopes have an outer diameter of 2.2 mm so a 2.5 mm endotracheal tube can be railroaded over them. The optical quality of these scopes is good but it has no suction channel and secretions have to be aspirated with a suction catheter [3]. Though an ideal technique, pediatric bronchoscopic intubation is time consuming and requires expertise, skill and expert assistance proper size of FOB, smooth inhalational induction, deep plane of anesthesia and maintenance of spontaneous ventilation [5]. We did not use fiberoptic bronchoscope in our case due to non-availability of appropriate size FOB at our setup.

Premedication and pre-oxygenation should be followed by inhalation with either halothane or sevoflurane in a spontaneously breathing patient. It is better to withhold muscle relaxants until the airway is secured. Use of a muscle relaxant during induction of anesthesia may result in a difficult to ventilate and difficult to intubate situation. Intubation should be performed under deep inhalational anesthesia. Intravenous versus inhalational induction should be discussed. Cooperation of the child and support of the parents will be a factor in the induction decision-making process. In our case we experienced difficulty in ventilating the child in supine position, but with larger mask and turning patient in right lateral position, we were able to ventilate the child.

The laryngeal mask airway in pediatric patients with difficult airway is an excellent aid and can be used as a conduit for intubation. Video laryngoscopes are new addition to airway armamentarium. A variety of video laryngoscopes like King Vision is available for use in pediatric difficult airway and is a good alternative to fiberoptic bronchoscope as a first choice.

Pediatric airway management poses unique challenges to the anesthesiologist. Anesthesia for the child with lymphangioma involving the oral cavity and oropharynx requires thorough preparation and vigilance. Knowledge of the disease and the affected airway structures will help the anesthesia provider prepare for the case by having the correct equipment and the safest plan for the anesthesia.

REFERENCES

1. Morley SE, Ramesar KC, Macleod DA (1999) Cystic hygroma in an adult: A case report. *J R Coll Surg Edinb* 44: 57-58.
2. Chappius IIP (1995) Current aspects of cystic lymphangioma in the neck. *Arch De Pediatre* 1: 186-92.
3. Tewari A, Munjal M, Kamakshi, Garg S, Sood D, et al. (2009) Anesthetic consideration in macroglossia due to lymphangioma of tongue: A case report. *Indian J Anesth* 53: 79-83
4. Guelmann M, Katz J (2003) Macroglossia combined with lymphangioma: A case report. *J Cli Pediatr Dent* 27: 167-170.
5. Pethkar TS, Malde AD (2011) Anaesthetic management of cystic hygroma of tongue in a child. *J Anaesth Clin Pharmacol* 27: 421-423.