

## Uncuffed Endotracheal Tube as Nasopharyngeal Airway in Pediatrics: A Twig for Drowning Boat

Rishabh Jaju, Narender Kalaria\*, Nikhil Kothari, Shilpa Goyal, Priyanka Sethi and Pooja Bihani

\*Department of Anesthesiology and Critical Care, All India Institute of Medical Sciences, Jodhpur, Rajasthan, India.

Received January 10, 2019; Accepted March 12, 2019; Published April 07, 2019

### ABSTRACT

Airway management during emergence from anesthesia is challenging in pediatric patients because of increased risk of airway obstruction. A two-year-old child with diagnosis of tethered cord scheduled for release of tethered cord. The surgery was done under general anesthesia using sevoflurane. The airway was secured with 4 mm microcuffed ETT. The intraoperative course was uneventful but after extubation, there was severe airway obstruction. Conventional airway maneuvers were tried but situation couldn't be managed. The oral airway was not an option as it could increase risk of laryngospasm and subsequent complications. So, we planned to use nasopharyngeal airway (NPA) to relieve obstruction but pediatric size NPA was not available. We used uncuffed ETT of 4 mm ID as a replacement of NPA and airway obstruction was relieved with this modified NPA. To conclude, we advocate the use of uncuffed ETT as substitute for nasopharyngeal airway especially in pediatric patients.

**Keywords:** Nasopharyngeal airway, Tethered cord, Laryngospasm

**Abbreviations:** ETT: Endotracheal Tube; NPA: Nasopharyngeal Airway; ID: Internal Diameter

### INTRODUCTION

The pediatric patients have a significant different anatomy and physiology with respect to adults. Airway management is challenging in pediatric patients because of increased risk of airway obstruction especially if it occurred during emergence. We report the utility of uncuffed endotracheal tube (ETT) as a replacement for nasopharyngeal airway (NPA) to relieve airway obstruction during anesthesia recovery. A written informed consent was obtained from father of the child for permission of expected publication.

### CASE PRESENTATION

A two year old child with diagnosis of tethered cord scheduled for tethered cord release. Preoperative evaluation of the child revealed left sided microtia and dermoid of eye. No other vertebral, mandibular or cardiac abnormalities were present. Preoperative airway examination couldn't be performed as child was un-cooperative but no obvious external airway deformity was noted. The child premedicated with oral midazolam in preoperative holding area under direct supervision. In the operation theatre, routine anesthesia monitors were attached and inhalation induction with sevoflurane was done while maintaining spontaneous ventilation. Then, intravenous line was secured with 24 gauge cannula on left hand. Intravenous fentanyl 20

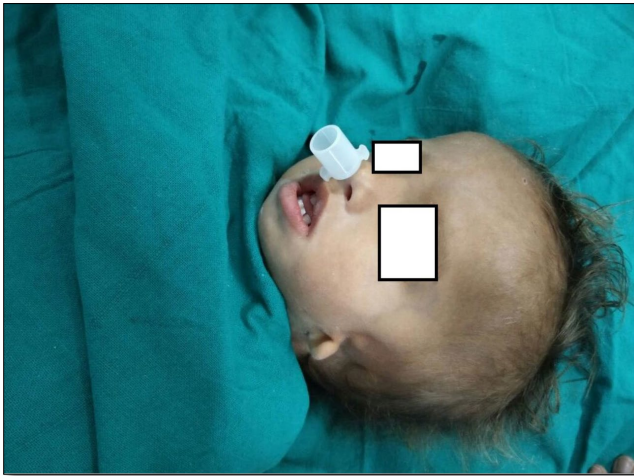
µg given and atracurium 5 mg was given. The airway was secured with 4 mm microcuffed ETT. The child ventilated with pressure control mode and maintained on sevoflurane. Surgery lasted for 45 min and intraoperative course of the child was uneventful. At the end of procedure, when child was having some spontaneous breathing effort, muscle relaxation reversed with neostigmine and glycopyrrolate. The child was extubated after appropriate respiration and power of limbs. Soon after extubation of trachea, child started showing signs of obstructed labored breathing pattern with presence of tracheal tug. Bilateral air entry decreased markedly. Her oxygen saturation dropped to 75% even though oxygen was being supplemented with bag and mask. The respiratory distress considered probably due to upper

**Corresponding author:** Dr. Narender Kalaria, Department of Anesthesiology and Critical Care, All India Institute of Medical Sciences, 303/06, AIIMS Residential Complex, Basni Phase II, Jodhpur, Rajasthan, India, Tel: +918872495145; E-mail: naren.keli@gmail.com

**Citation:** Jaju R, Kalaria N, Kothari N, Goyal S, Sethi P, et al. (2019) Uncuffed Endotracheal Tube as Nasopharyngeal Airway in Pediatrics: A Twig for Drowning Boat. *Int J Anaesth Res*, 2(1): 29-.

**Copyright:** ©2019 Jaju R, Kalaria N, Kothari N, Goyal S, Sethi P, et al. This is an open-access article distributed under the terms of the Creative Commons Attribution License, which permits unrestricted use, distribution, and reproduction in any medium, provided the original author and source are credited.

airway obstruction by soft tissue structures. The child was not compliant for putting oral airway or LMA and appropriate sized NPA was not available. So, we planned to use uncuffed endotracheal tube as NPA. The Polyvinyl chloride uncuffed ETT of 4.0 mm ID was cut to 10 cm length (measured as length between alar nasi and ear lobe) and the ETT connector was again attached. This modified nasopharyngeal airway (MNPA) was gently advanced after application of lubrication jelly just as like a conventional nasopharyngeal airway (**Figure 1**). A continuous positive airway pressure (CPAP) of 10 cm H<sub>2</sub>O was applied by connecting anesthesia breathing circuit to ETT connector while other nose and mouth was closed manually. Adequate ventilation confirmed by a good end-tidal carbon dioxide (EtCO<sub>2</sub>) tracing on the ventilator monitor screen. The obstruction was also relieved clinically as there were no signs of labored breathing. The child weaned off from CPAP after 20 min when he had no signs of obstructed breathing and maintaining saturation on room air. The child shifted to recovery room with MNPA in situ and monitored for saturation and signs of airway obstruction. The MNPA removed after 30 min when child was fully conscious. The child shifted toward after 2 h and discharged from there after 3 days.



**Figure 1.** Modified nasopharyngeal airway *in situ* with connector.

## DISCUSSION

The emergence from anesthesia is associated with a lot of complication if not planned in a proper way according to patient profile and extent of surgery; airway obstruction being one of them [1]. The common causes of airway obstruction are microaspiration, laryngeal edema, fall of tongue to posterior pharyngeal wall. The airway obstruction result in failure of airflow to lungs despite adequate inspiratory efforts. Increasing the inspiratory efforts against obstructed airway can worsen the situation as increasing negative intra-thoracic pressure collapses the soft tissues inwards [2]. The airway obstruction due to fall of tongue to

posterior pharyngeal wall can be relieved by jaw thrust maneuver, oropharyngeal airway or nasopharyngeal airway. A conscious patient is usually non-compliant for both jaw thrust maneuver and oropharyngeal airway and also may result in further laryngospasm and vomiting if used during emergence where gag reflex is present [3,4]. The safest option for this situation is use of nasopharyngeal airway that is more compliant during emergence. The nasopharyngeal airway is available only in adult size and appropriate size can be measured from side of nostril to angle of mandible. The appropriate size NPA is very important because both undersize and oversize will not resolve the obstruction. In our case, it was a pediatric case with obesity and difficult airway. Although, the NPA are softer as compared to oral airway and ETT but their size also decreases with decreasing diameter so it may not effectively relieve obstruction in most instances. The external length of ETT available outside helps in fixing the tube at correct position. Also, a universal connector better fit into the outer end of the ETT compared with a NPA so that outer end of tube can be connected to breathing circuit for application of CPAP effectively. ETT can be pre-warmed to make it soften but in our case we had no time for warming the tube.

## CONCLUSION

To conclude, we recommend that a lubricated, pre-warmed PVC endotracheal tube can be used as a replacement of nasopharyngeal airway to treat airway obstruction during emergence from anesthesia especially in a pediatric patient to overcome the limitation of nasopharyngeal airway.

## ACKNOWLEDGEMENT

I would like to acknowledge the patients and his parents for giving me consent to publish this interesting case.

## CONFLICT OF INTEREST

Nil

## REFERENCES

1. Karmarkar S, Varshney S (2008) Tracheal extubation. *Contin Educ Anesth Crit Care Pain* 8: 7.
2. Asai T, Koga K, Vaughan RS (1998) Respiratory complications associated with tracheal intubation and extubation. *Br J Anesth* 80: 765-775.
3. Mort TC (2003) Extubating the difficult airway: formulating the management strategy; use of accessory airway devices and alternative techniques may be key. *J Crit Illn* 18: 210-217.
4. Cavallone LF, Vannucci A (2013) Extubation of the difficult airway and extubation failure. *Anesth Analg* 116: 368-383.