

Metastatic Papillary Thyroid Carcinoma Presenting as Lateral Cystic Swelling of the Neck – A Case Report and Review of Literature

Sadaf Zia, Amna Khalil*, Sumayya Yahya, Hafsa Arshad Ali Khan, Iqbal A Muhammad Khyani and Salman Matiullah

*Department of Otolaryngology, Patel Hospital, Karachi, Pakistan

Received May 22nd, 2020; Revised May 30th, 2020; Accepted June 01st, 2020

ABSTRACT

Introduction: Carcinoma of the thyroid gland accounts for approximately 1% of all malignancies. An isolated cystic lesion as the presenting sign of papillary thyroid carcinoma (PTC) is extremely rare. It is even more unusual if there is no associated malignancy in the thyroid gland and the origin of the metastatic lesion remain unclear. Most such cases have been dealt with complete removal of the thyroid gland followed by appropriate radiotherapy having good prognosis.

Case Report: We present an unusual case of Metastatic Papillary Carcinoma of the Thyroid presenting as a left lateral neck swelling of cystic nature. The case is of a middle-aged gentleman who presented with a solitary cystic mass on the left side of neck. The case is unique as the thyroid gland itself was free from disease. Thyroid scan showed normal thyroid status, with no cold nodules in neck identified and the swelling over left side of neck was extra thyroidal. FNAC of the swelling was suggestive of cyst. Patient was advised computed tomography (CT) scan of neck with contrast. Excisional biopsy of the swelling confirmed the diagnosis of metastatic papillary thyroid carcinoma.

Conclusion: Metastatic presentation of papillary thyroid carcinoma as a lateral neck swelling is indeed a diagnostic challenge. This case report accentuates that patients presenting with a solitary lateral neck swelling must be treated with high index of suspicion. Excisional biopsy is indicated in all such presentations to rule out malignancy if fine needle aspiration cytology (FNAC) comes out to be inconclusive.

Keywords: Cyst, Neck, Fine needle aspiration, Metastatic, Papillary Thyroid Carcinoma

INTRODUCTION

Swellings of the neck are common complaints. Majority of cases are inflammatory lumps that resolve within few weeks, persistent lymph nodes can be signs of chronic disease or underlying malignancies.

Carcinoma of the thyroid gland accounts for approximately 1% of all malignancies. 10-15% of these cases manifestas cervical lymphadenopathy with an occult primary lesion. Isolated cystic metastasis as the presenting sign is extremely rare. Forty-two such cases have been reported previously [1]. Papillary thyroid carcinoma presenting as an isolated lateral neck mass is rare. It is even more unusual if there is no associated malignancy in the thyroid gland and the origin of the metastatic lesion remain unclear.

CASE SUMMARY

A 55-year-old male patient with no known co-morbid presented in outpatient department (OPD) of Otolaryngology, Head & Neck Surgery department with a

painless, slow-growing swelling on the left side of the neck for two years. There was no associated fever or weight loss. On examination, there was a single swelling on the left side of the neck, extending superiorly to level of hyoid bone and inferiorly up to supraclavicular region. It was an on-tender, smooth, soft and cystic swelling of about 7 x 3 cm in size. The thyroid gland and cervical lymph nodes were not palpable, and the rest of the ENT examination was unremarkable.

Ultrasound neck showed a large cystic mass on the left side of neck suggestive of necrotic lymph nodes. Thyroid gland

Corresponding author: Amna Khalil, Department of Otolaryngology, Patel Hospital, Karachi, Pakistan, E-mail: dr.amnakhali190@gmail.com

Citation: Zia S, Khalil A, Yahya S, Ali Khan HA, Khyani IAM et al. J Otolaryngol Neurotol Res, 3(1): 89-91.

Copyright: ©2020 Zia S, Khalil A, Yahya S, Ali Khan HA, Khyani IAM et al. This is an open-access article distributed under the terms of the Creative Commons Attribution License, which permits unrestricted use, distribution, and reproduction in any medium, provided the original author and source are credited.

appeared normal in size and shape. Small multiple hypo echoic nodules were visible in right lobe, one measuring 0.3x0.2 cm. The small size of the nodules was also difficult to get the exact location while doing fine needle aspiration cytology (FNAC) for confirmation of presence or absence of malignancy. Therefore, these nodules were not further investigated with FNAC of thyroid.

Thyroid scan showed normal thyroid status, with no cold nodules in neck identified and the swelling over left side of neck was extra thyroidal. FNAC of the swelling was suggestive of cyst. Patient was advised computed tomography (CT) scan of neck with contrast.

CT scan of neck with contrast revealed a multi-loculated cystic mass lesion in the posterior triangle of the left side of neck with thin enhancing septa. Thyroid gland did not show any nodule on CT scan neck. Bilateral cervical lymphadenopathy less than 1 cm at level I and II was also seen. Findings were more in favour of a benign neoplastic lesion such as lymphangioma. Excisional biopsy of mass was advised (Figures 1 and 2). Per-operatively, the lesion was a vascular looking mass just beneath the sternocleidomastoid muscle. There was no soft tissue connection with the left thyroid lobe. The mass was excised completely, and the wound was closed over negative pressure drain. Patient's post-operative recovery was uneventful.

Histopathology report of the mass showed cystic lymph node exhibiting a metastatic lesion with a papillary architecture. The tumor cells show positive staining for Thyroid transcription factor 1. The histopathology concluded that the neck lump was Metastatic Papillary Carcinoma of Thyroid Gland.

As this was an unusual case, a multi-disciplinary meeting was called to discuss the best possible option for the patient's management. The recommendation was for 'Total Thyroidectomy' followed by radioactive iodine-ablation as the next step of management. However, the patient refused for any further surgery.

To further evaluate the status of thyroid, an ultrasound neck was repeated for post-operative evaluation which showed multiple iso-echoic nodules in the right lobe of thyroid gland, one measuring 0.3 cm in diameter. Left lobe of thyroid gland was normal with no solid or cystic nodules seen. Small sub-centimeter lymph nodes were noted in the upper part of right side of the neck.

Considering that the left thyroid lobe was absolutely normal on the side of the lesion, the thyroid scan was normal with no cold nodules and the patient was asymptomatic, he was advised for monthly follow up. Evaluation was repeated one year post-operatively and follow up ultrasound done at this visit revealed a normal thyroid gland with no evidence of cervical lymphadenopathy. After three years post-operative

follows up, clinically there was no swelling in the neck or thyroid gland.

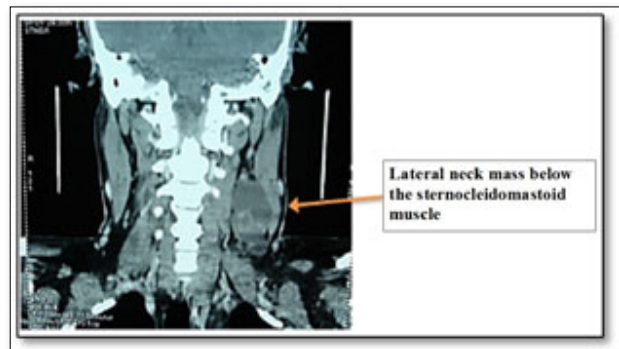


Figure 1. CT scan neck with contrast Coronal View.

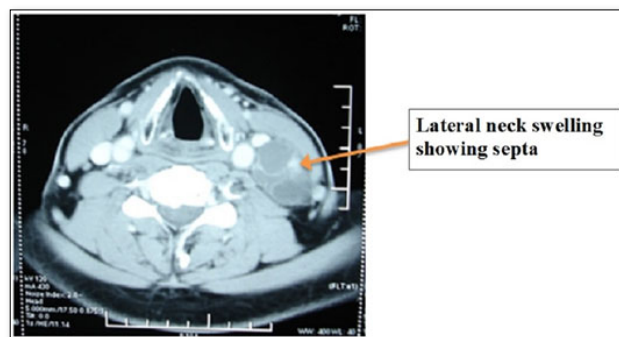


Figure 2. CT scan neck with contrast Axial View.

DISCUSSION

Cystic lesions such as Branchialc left cysts, Dermoid cysts, Hemangioma and Cystic Hygroma can all present as lateral neck swellings. However, the clinical evaluation of adults through middle to older age group presenting with lateral neck lumps is aimed more specifically at the exclusion of malignancy especially when the patient presents with a slow growing painless neck mass. Therefore, thorough evaluation is a must to reach an accurate diagnosis.

In our patient, taking his age and the nature of the lump under consideration we had to come to a diagnosis of exclusion, suspecting a malignancy. In a similar case reported by P Krishnappa, a cystic lesion in the patient's neck laterally proved to be an occult papillary carcinoma [1]. The most specific sonographic finding of papillary carcinoma is the presence of punctuate, non-shadowing echogenic foci termed micro-calcifications, associated with psammoma bodies for suspecting papillary thyroid carcinoma. This is the finding having high specificity (85-95%) and low sensitivity (25-59%) [2]. Although FNAC is reported as being highly accurate by Lowhagen and his colleagues, there can be a high rate of unsatisfactory aspirates, particularly in cystic or partly cystic swellings [3]. This was true in our case in which only the confirmation of the cystic nature of the swelling was obtained. The size of

nodules in thyroid gland which are considered significant for suspicion of malignancy is 0.5 cm; the reported ones in our case were less than that, therefore did not appear significant preoperatively. As the nodules within the thyroid gland were small (0.3 cm) and were on the contralateral side of the cystic neck lesion, the FNAC of thyroid nodule itself was not attempted. CT scan neck revealed a multi-loculated cystic mass lesion with enhancing septa favoring a benign neoplastic lesion. The thyroid gland was reported normal on CT scan.

If the results of the ultrasound scan and FNAC are inconclusive, excisional biopsy of the cyst is essential so as to rule out malignancy and to avoid the delay in the diagnosis and management [4]. The histopathology revealed Metastatic Papillary Carcinoma of Thyroid Gland. Solitary lateral cervical cystic mass is an uncommon presentation of papillary thyroid carcinoma (PTC) [4]. In up to 20% of all patients, lymph node metastases may even be the sole or initial manifestation of disease (occult primary tumor) [5]. According to the patients reviewed by Monchik [6], sometimes the primary thyroid tumor is less than 1 cm and at other times only microscopic, the extensive nodal metastasis has led them to favor near total or total thyroidectomy and modified neck dissection in this entity [6].

Rarely, PTC presents as a lateral cystic neck mass without palpable lesion in the thyroid gland. The origin of these cysts is controversial. Some authors think that it represents a malignant transformation of ectopic thyroid tissue. Others think that it represents a secondary metastatic spread from occult thyroid lesion to the lymph node which underwent central liquefaction with cystic formation [7].

In the case series by Y Al-Ashaa, five patients with papillary thyroid carcinoma presenting as a lateral neck cyst were studied, three patients had total thyroidectomy and modified radical neck dissection out of which two patients were followed up for 5 years and were completely free of the disease [4].

One out of every 10 lateral cervical cysts in young adult patients represents lymphatic metastases from occult thyroid carcinoma. The appearance of a solitary lateral cervical cystic mass as the only initial presenting symptom of occult thyroid carcinoma is extremely rare, with approximately 40 cases previously reported in the literature. Seven et al. has reported 11% of thyroid malignancy in patients with primary diagnosis of lateral cervical cyst [8]. Our patient had refused 'Total thyroidectomy with neck dissection so he was advised to keep a regular follow up.

On follow up, ultrasound neck after 1 year revealed no cervical lymphadenopathy and a completely normal thyroid gland. On three years' post-operative follow up, clinically there is no thyroid or lateral neck swelling. According to published studies of previous case reports, most were dealt

with complete removal of the thyroid gland followed by appropriate radiotherapy and good prognosis. In our case, the patient is free of disease three years post-operatively though the patient had refused treatment advised. However, the origin of the metastatic lesion remains unknown.

CONCLUSION

Solitary lateral cystic swelling of the neck is an uncommon presentation of papillary thyroid carcinoma, when occurs is usually considered as a benign lesion. Metastatic presentation of PTC as a lateral neck swelling is indeed a diagnostic challenge. This case report accentuates that patients presenting with a solitary lateral neck swelling must be treated with high index of suspicion. Excisional biopsy is indicated in all such presentations to rule out malignancy if FNAC comes out to be inconclusive.

REFERENCES

1. Krishnappa K, Kulkarni M (2009) Occult Papillary Carcinoma Thyroid presenting as Lateral Cystic Neck Mass: A Case Report & Review of Literature. *J Pathol* 10: 12.
2. Javan RMJ, McGinnis RS, Moinuddin M, Sarti M (2013) Thyroid ultrasound top10 pathology. Papillary Carcinoma .
3. Williams NS, Bulstrode CJK, O'Connell PR (2008) Baily and Love's Short Practice of Surgery. 25th ed. London: Hodder Arnold an imprint of Hodder Education;
4. Ashaa YA, Hefny A, Joshi S, Zidan FA (2011) Papillary thyroid carcinoma presenting as a lateral neck cyst. *Afr Health Sci* 11: 296-300.
5. Patil VS, Vijayakumar A, Natikar N (2012) Unusual presentation of cystic papillary thyroid carcinoma. *Case Rep Endocrinol* 2012: 4.
6. Monchik JM, De Petris G, De Crea C (2001) Occult papillary carcinoma of the thyroid presenting as a cervical cyst. *Surgery* 129: 429-432.
7. Attie JN, Setzin M, Klein I (1993) Thyroid carcinoma presenting as an enlarged cervical lymph node. *Am J Surg* 166: 428-430.
8. Seven H, Gurkan A, Cinar U, Vural C, Turgut S (2004) Incidence of occult thyroid carcinoma metastases in lateral cervical cysts. *Am J Otolaryngol* 25: 11-17.