

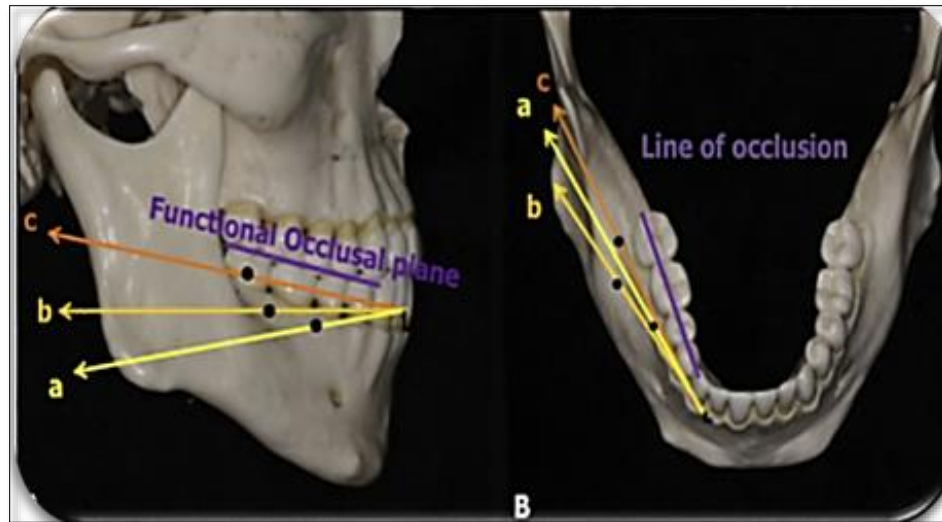Figure 8. Comparison of the Force Vector in each Device: A, Lateral View; B, Occlusal View. Dots Indicate the Positions of the Miniscrew Head and the Ramal Plate Hook: a, Interradicular Miniscrew; b, Buccal Shelf Miniscrew; c, Ramal Plate Hook.

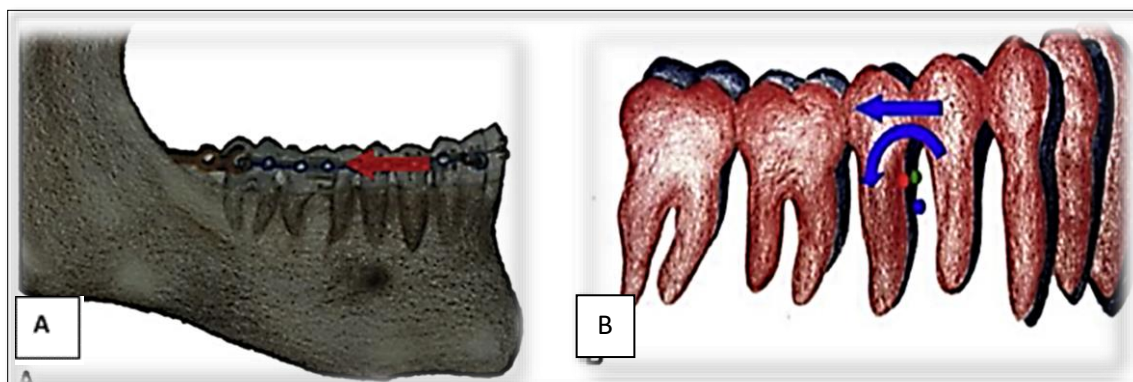


Figure 9. Force System and Tooth Displacement: A, Distalization Force Parallel to the Occlusal Plane at the Vertical Level of the Archwire; B, Distalization and Counterclockwise Potation of the Mandibular Occlusal Plane Around the Center of Rotation (Blue Dot), which is Slightly Apical to the Center of Resistance of the Mandibular Dentition (Green Dot, Pretreatment; Red Dot, Posttreatment); Blue Dentition, Pretreatment; Red Dentition; Posttreatment.

Lateral CBCT Cephalometric: Selected CBCT lateral cephalometric variables were identified for each cephalogram, representing skeletal, dentoalveolar, and soft tissue measurements (Figures 2-5).

Skeletal Change: Analysis of the treatment result indicated that there was a statistically significant change in the sagittal relationship between the mandible and maxilla. This result was highly statistically significant Wit’s appraisal, $p = 0.006$. This result agreed with Yu [34], Yeon [35] Also, the current study result got a high statistically significant ANB° P-Value = 0.004 as shown in Table 1, this result was not in agreement with [34] However, statistically significant levels of SNA° and SNB° did not change significantly between pre- and post-treatment (Tables 1).

The two variable of Facial high ratio and FMA° result indicated limited craniofacial change after treatment since no statistically significant difference observed in most of cephalometric Skeletal angular parameter (Table 1). This result is agreed with that of Yu [34] but was disagreed with that reported by Yeon [35] where the FMA° had significant result.

Dental Changes: Evaluation of the post-treatment outcome showed improvement in most of the bilateral alveolar variables as shown in Table 1 by highly significant in U1 to FH °P-Value = 0.000, IMPA °p-Value = 0.081 as well as the interincisal angle. [38] did not perform any statistical analysis in their research on this variable, and [34] did not take the same measurement parameter in their statistical analysis as the one that worked in this research. Our findings indicate that correction of the anterior reverse overjet and

overlay without significant change in the mandibular plane resulted in distalization of the mandibular teeth. This study improvement of interincisor angle was very significant while U1 to FH° and IMPA° were statistically highly significant as shown in **Table 1**.

Soft Tissue Changes: In the current study, four variables were used in an attempt to understand possible changes in different aspects of face, such as ANB° of soft tissue, nasolabial angle, upper lip and lower lip of esthetic plane line. Evaluation of the soft tissue profile in the 6 patients revealed an improvement a high statistically significant, especially in the ANB° of soft tissue has a high statistically significant p-value =0.000 as shown in **Table 1**. There is no agreement between our study and Yu [34] where there was no statistically significant effect on the position of the upper lip and nasolabial angle but their results agreed with our study in the lower lip.

CONCLUSION

After alignment and leveling the patients using recent application of Noval ramal plate in retromolar fossa, the retromolar fossa is an anatomically appropriate location. The force vectors that result is parallel to the occlusal plane, resulting in efficient molar distalization. With ramal plates, there was no significant change in the vertical position of the mandibular molar or in the MP angle. In the evaluation of dental variable, there were a statically significant in U1 to FH°, IMPA° and Interincisor Angle. In the evaluation of soft tissue there was a statically significant in Nasolabial Angle, Ls-E Line (mm), and Li-E line (mm). Therefore, ramal plates are an effective treatment option for Class III patients who are apprehensive about undergoing extraction teeth and or orthognathic surgery for mandibular complete arch distalization.

ACKNOWLEDGMENTS

The authors thank the Faculty of Dentistry, Sana'a University, Sana'a, and Yemen for their generous support.

CONFLICT OF INTEREST

No conflict of interest associated with this work.

AUTHOR'S CONTRIBUTIONS

This research is part of a master's degree in the Orthodontics, Pedodontics and Prevention Department, Faculty of Dentistry, Sana'a University, Yemen, first author Reem Hussein Sheikh Omar AL-Kaff, who conducted field work, and who did clinical work and other authors contributed to data analysis, drafting and review of the paper, and gave final approval to the research.

REFERENCES

- Jokić D, Jokić D, Uglešić V, Macan D, Knežević P (2013) Soft tissue changes after mandibular setback and bimaxillary surgery in Class III patients. *Angle Orthod* 83(5): 817-823.
- Janson G, de Souza JE, Alves Fde A, Andrade P Jr, Nakamura A, et al. (2005) Extreme dentoalveolar compensation in the treatment of Class III malocclusion. *Am J Orthod Dentofacial* 128(6): 787-794.
- Neto JV (2014) Compensatory orthodontic treatment of skeletal Class III malocclusion with anterior crossbite. *Dental Press J Orthod* 19(1): 113-122.
- Hu H, Chen J, Guo J, Li F, Liu Z, et al. (2012) Distalization of the mandibular dentition of an adult with a skeletal Class III malocclusion. *Am J Orthod Dentofacial Orthod* 142(6): 854-862.
- Saito I, Yamaki M, Hanada K (2005) Nonsurgical treatment of adult open bite using edgewise appliance combined with high-pull headgear and class III elastics. *Angle Orthod* 75(2): 277-283.
- Chen CH, Hsieh CH, Tseng YC, Huang IY, Shen YS, et al. (2007) The use of miniplate osteosynthesis for skeletal anchorage. *Plast Reconstr Surg* 120(1): 232-235.
- Sugawara J, Daimaruya T, Umemori M, Nagasaka H, Takahashi I, et al. (2004) Distal movement of mandibular molars in adult patients with the skeletal anchorage system. *Am J Orthod Dentofacial Orthop* 125(2): 130-138.
- Kinzinger G, Gross U, Diedrich P (2000) Fixed lingual arch appliance for compliance-free unilateral molar distalization in the mandible. Three case studies. *J Orofac Orthop* 61(6): 440-450.
- O'Donnell S, Nanda RS, Ghosh J (1998) Perioral forces and dental changes resulting from mandibular lip bumper treatment. *Am J Orthod Dentofacial Orthop* 113(3): 247-255.
- Muse DS, Fillman MJ, Emmerson WJ, Mitchell RD (1993) Molar and incisor changes with Wilson rapid molar distalization. *Am J Orthod Dentofacial Orthop* 104(6): 556-565.
- Jing Y, Han X, Guo Y, Li J, Bai D (2013) Nonsurgical correction of a Class III malocclusion in an adult by miniscrew-assisted mandibular dentition distalization. *Am J Orthod Dentofacial Orthop* 143(6): 877-887.
- Poletti L, Silvera AA, Ghislanzoni LT (2013) Dentoalveolar class III treatment using retromolar miniscrew anchorage. *Prog Orthod* 14: 7.
- Sugawara J, Kanzaki R, Takahashi I, Nagasaka H, Nanda R (2006) Distal movement of maxillary molars in nongrowing patients with the skeletal anchorage

- system. Am J Orthod Dentofacial Orthop 129(6): 723-733.
14. Sugawara Y, Kuroda S, Tamamura N, Takano-Yamamoto T (2008) Adult patient with mandibular protrusion and unstable occlusion treated with titanium screw anchorage. Am J Orthod Dentofacial Orthop 133(1): 102-111.
 15. Kook YA, Park JH, Bayome M, Kim S, Han E, et al. (2016) Distalization of the mandibular dentition with a ramal plate for skeletal Class III malocclusion correction. Am J Orthod Dentofacial Orthop 150(2): 364-377.
 16. AL-Awadi TAM, AL-Haddad KA, Al-labani MA, Al-Shamahy HA, Shaga-aldeen HM (2020) Prevalence of malocclusion among Yemeni children of primary schools. Uni J Pharm Res 5(1): 1-6.
 17. Yehia LAB, AL-Haddad KA, Al-labani MA, Al-Shamahy HA, Shaga-aldeen HM (2020) Occlusal characteristics of the primary dentition among a sample of Yemeni pre-school children. Uni J Pharm Res 5(1): 7-12.
 18. Bamashmoos KAO, Alhasani AH, Al-Akwa AAY, Zabara AQMQ (2020) Prevalence of premature loss of primary teeth at the age of 6-10 years in Sana'a city, Yemen. Uni J Pharm Res 5(4): 1-6.
 19. Zabara AQMQ, Al-Kholani AIM, Al-Shamahy HA, Al-Kibsi TAM, Al-Akwa AAY, et al. (2022) Resolution of factors and pattern of permanent dental extraction in selected dental clinics in Sana'a city, Yemen. Uni J Pharm Res 7(4): 1-8.
 20. Bilecenoglu B, Tuncer N (2006) Clinical and anatomical study of retromolar foramen and canal. J Oral Maxillofac Surg 64(10): 1493-1497.
 21. Rossi AC, Freire AR, Prado GB, Prado FB, Botacin PR et al, (2012) Incidence of retromolar foramen in human mandibles: Ethnic and clinical aspects. Int J Morphol 30: 1074-1078.
 22. von Arx T, Hänni A, Sendi P, Buser D, Bornstein MM (2011) Radiographic study of the mandibular retromolar canal: An anatomic structure with clinical importance. J Endod 37(12): 1630-1635.
 23. Alhadi YAA, Al-Shamahy NY, Al-Shamahy HA, Al-Najhi AMM, Al-Shamahy HA, et al. (2022) Maxillary sinus septa: Prevalence and association with gender and location in the maxilla among adults in Sana'a city, Yemen. Uni J Pharm Res 7(3): 1-6.
 24. Alhadi YAA, Al-Kibsi TAM, Al-Shamahy HA, Aldeen YAAS (2022) Surgical site infections: prevalence, associated factors and antimicrobial susceptibility patterns of the bacterial isolates among postoperative patients in Sana'a, Yemen. Uni J Pharm Res 7(3): 1-6.
 25. Abbas AM, Al-Kibsi TAM, Al-Shamahy HA (2020) Characterization and antibiotic sensitivity of bacteria in orofacial abscesses of odontogenic origin. Uni J Pharm Res 5(6): 36-42.
 26. Al-Akwa AA, Zabara A, Al-Shamahy HA (2020) Prevalence of *Staphylococcus aureus* in dental infections and the occurrence of MRSA in isolates. Uni J Pharm Res 5(2): 1-6.
 27. Al-Deen SSH, Al-Ankoshy AAM, Al-Shamahy HA, Al-Kibsi TAM, AL-Haddad KA, et al. (2021) *Porphyromonas gingivalis*: Biofilm formation, antimicrobial susceptibility of isolates from cases of Localized Aggressive Periodontitis (LAP). Uni J Pharm Res 6 (4): 1-6.
 28. AL-Haddad KA, Al-Najhi AMM, Al-Akwa AAY (2007) Antimicrobial susceptibility of *Aggregatibacter actinomycetemcomitans* isolated from Localized Aggressive Periodontitis (LAP) Cases. J Dent Oral Health Adv Res 103: 1-6.
 29. Alhasani AH, Ishag RA, Al Shamahy HA, Abdullah A, Shamahy AL, et al. (2020) Association between the Streptococcus mutans biofilm formation and dental caries experience and antibiotics resistance in adult females. Uni J Pharm Res 5(6): 1-3.
 30. Al-Shamahy HA, Abbas AMA, Mohammed MAM, Alsameai AM (2018) Bacterial and fungal oral infections among patients attending dental clinics in Sana'a City-Yemen. Onl J Dent Oral Health 1(1): 1-6.
 31. Al-dossary OAI, Al-Kholani AIM, Al-Shamahy HA (2022) Interleukin-1 β levels in the human gingival sulcus: Rates and factors affecting its levels in healthy subjects. Uni J Pharm Res 7(5): 25-30.
 32. Al-Haddad K, Al-Najhi MM, Al-Kholani AIM, Al-Shamahy HA, Alrubaidi YA, et al. (2023) Effect of removable dentures on colonization of aerobic bacteria in the oral cavity and antibiotic pattern of the common isolated bacteria. Uni J Pharm Res 7(6): 1-8.
 33. Makki KIF, Abbas AMA, Alhadi YAA, Al-Shamahy HA (2023) Clinical effects of Platelets Rich Fibrin (PRF) following surgical extraction of impacted lower third molars among a sample of Yemeni adults. Uni J Pharm Res 7(6): 8-14.
 34. Yu J, Park JH, Bayome M, Kim S, Kook YA, et al. (2016) Treatment effects of mandibular total arch distalization using a ramal plate. Korean J Orthod 46(4): 212-219.
 35. Yeon BM, Lee NK, Park JH, Kim JM, Kim SH, et al. (2022) Comparison of treatment effects after total

- mandibular arch distalization with miniscrews vs ramal plates in patients with Class III malocclusion. *Am J Orthod Dentofacial Orthop* 161(4): 529-536.
36. Krishnamurthy S, Prashantha GS, Sagarkar R, Bhaduri N, Padmanathan R, et al. (2022) En-masse distalization of mandibular dentition with ramal miniplate for correction of Class III malocclusion: A Case Report. *J Clin Diagnostic Res* 16(10): ZD08-ZD11.
 37. Chang C, Liu SS, Roberts WE (2015) Primary failure rate for 1680 extra-alveolar mandibular buccal shelf mini-screws placed in movable mucosa or attached gingiva. *Angle Orthod* 85(6): 905-910.
 38. Kook Y-A, Park JH, Bayome M, Kim S, Han S, et al. (2016) Distalization of the mandibular dentition with a ramal plate for skeletal Class III malocclusion correction. *Am J Orthod Dentofacial Orthop* 150: 364-377.
 39. Ludwig B, Glals B, Kinzinger GSM, Lietz T, Lisson JA (2011) Anatomical guidelines for miniscrew insertion: vestibular interradicular sites. *J Clin Orthod* 45: 165-173.
 40. Kim YH, Han UK, Lim DD, Serranon ML (2000) Stability of anterior open bite correction with multiloop edgewise archwire therapy: A cephalometric follow-up study. *Am J Orthod Dentofacial Orthop* 118: 43-54.