

Relationship between Coronary Slow Flow and Endothelial Dysfunction

Batur Gonenc Kanar^{1*}, Ahmet Anil Sahin¹ and Hatice Selen Kanar²

¹Department of Cardiology, Faculty of Medicine, Marmara University, Istanbul, Turkey

²Kartal Lutfi Kırdar Research and Training Hospital, Department of Ophthalmology, Istanbul, Turkey.

Received October 18, 2018; Accepted December 05, 2018; Published April 11, 2019

Coronary slow flow (CSF) is a vascular phenomenon which is detected by angiography images, created using a contrast dye, that are characterized by delayed distal vessel opacification without any significant epicardial coronary artery stenosis. This phenomenon, in clinical practice, is observed with a respectively high incidence, a rate of 7% in patients who have diagnostic coronary angiography [1]. CSF is seen in higher rates with patients who are young male smokers. Patients who have CSF might have a variety of symptoms from being asymptomatic to typical angina or unstable angina with a diagnosis of acute coronary syndrome [2].

Since this phenomenon was first identified, multiple hypotheses have been proposed to enlighten the pathophysiology of CSF, including small vessel disease, microvascular vasomotor dysfunction, diffuse atherosclerosis and endothelial dysfunction. But these pathophysiological mechanisms remained as hypotheses and the exact mechanism for this angiographic phenomenon had never been fully understood. Mosseri et al. [3] hypothesized that local small vessel dysfunction was the reason behind CSF and this hypothesis was supported by myocardial biopsies in research which revealed a loss of luminal size due to thickening of vessel walls during coronary microcirculation. But further research, in 1996, by Beltrame et al. [4] indicated a decreased response to endothelial stimuli in CSF patients. After these studies, intravascular ultrasound (IVUS) was used to observe the vessel thickening. Researchers showed that CSF patients had diffuse intimal thickening together with calcification which did not cause any luminal irregularities in the coronary angiography. Similarly in 2004, Pekdemir et al. [5] demonstrated that CSF patients had extended and widespread calcification in the epicardial coronary arteries and suggested that these calcifications may be a preliminary sign or cause of atherosclerotic disease in the coronary arteries; furthermore, CSF could be a form of early detection for atherosclerosis, a condition which affects the microvascular circulation [5]. Another finding revealed the relationship between ectasia in the coronary arteries and

slow flow [6]. It is known that the velocity of fluids in pipes can be altered when the pipe is suddenly enlarged or curved. Accordingly, abrupt changes in the vessels, like ectasia, can create a flow that might be slower compared to a vessel with ideal conditions. Based on the research, pathophysiology behind the CSF might be suggested not only as a structural problem but also as a microcirculatory dysfunction in the coronary arteries.

On the other hand, the assessment of flow-mediated dilatation (FMD) of the brachial artery has been widely used to investigate the endothelial function of the arteries. One of the studies showed that there was a concomitant relationship between CSF and FMD of the brachial artery. Patients who had CSF also showed reduced endothelial-dependent FMD of the brachial artery in an ultrasound [7]. Another finding indicated the concentrations of nitric oxide (NO) and endothelin-1 (ET-1) were lower in the CSF patients [8]. Kurtoglu et al. [9] investigated the effect of dipyridamole treatment which showed beneficial progress in restoring the flow in these patients. In another study, Tanriverdi et al. [10] showed impairment of endothelial function due to homocysteine induced oxidative stress in CSF patients. These findings suggest that CSF might be associated not only with local disease but with systemically affected endothelial dysfunction.

Both this systematical involvement and the microcirculation abnormality of coronary arteries may be associated with impaired choroidal microcirculation. It has been shown in animal models that atherosclerotic changes occurred in choroidal arteries [11]. Studies showed that subfoveal

Corresponding author: Batur Gonenc Kanar, Department of Cardiology, Faculty of Medicine, Marmara University, Istanbul, Turkey, Tel: +905395855150; Fax: +902166570695; E-mail: baturkanar@hotmail.com

Citation: Kanar BG, Sahin AA & Kanar HS. (2019) Relationship between Coronary Slow Flow and Endothelial Dysfunction. *J Genet Cell Biol*, 2(1): 44-46.

Copyright: ©2019 Kanar BG, Sahin AA & Kanar HS. This is an open-access article distributed under the terms of the Creative Commons Attribution License, which permits unrestricted use, distribution, and reproduction in any medium, provided the original author and source are credited.

choroidal thickness (SFCT) decreased in the patients who had retinitis pigmentosa due to a microcirculation abnormality [12,13]. These findings revealed the obvious relationship between vascular beds. In 2014, Ahmad et al. [14] showed that patients with coronary artery diseases had a thinner macular choroid than controls. In 2014, Altinkaynak et al. [15] showed that patients with congestive heart failure presented lower SFCT compared to age- and gender-matched controls. Another study indicated a close relationship between CSF and SFCT; additionally, the study demonstrated improvement of SFCT with the treatment of statin therapy [16].

Patients with CSF may also present with other clinical features. Yilmaz et al. [17] studied the clinical and laboratory relationships of CSF patients and found a close relationship between CSF and the following clinical problems: insulin resistance, impaired glucose tolerance, metabolic syndrome with the presence of higher total cholesterol, low-density lipoprotein cholesterol, fasting glucose and body mass index. Therefore, anti-inflammatory

statin therapies are studied for patients who have CSF and mentioned clinical problems.

Statins work in a variety of ways to effect CSF patients (Figure 1). Statins can effectively lower cholesterol levels by inhibiting endogenous cholesterol synthesis. This lowering effect might restore the endothelial function; however, trials showed that endothelial function was restored in patients before the levels of lipids were lowered, suggesting the cholesterol-independent effect of statins [18]. Taken together, endothelium dependent vasodilation was triggered by statin therapy which was associated with lowering cholesterol; statins also reduced the endothelin-1 release in endothelial cells [19,20]. Another effect of statin treatment was the modulation of the inflammatory process in the coronary arteries. Commonly, statin treatment significantly lowered the high-sensitive C-reactive protein (CRP) [21]. A statin lowered not only high-sensitive CRP, but it also decreased the interleukin-6 (cultured mononuclear cell) levels as well as inflammatory cytokine levels in *in vitro* studies of human cells [22,23].

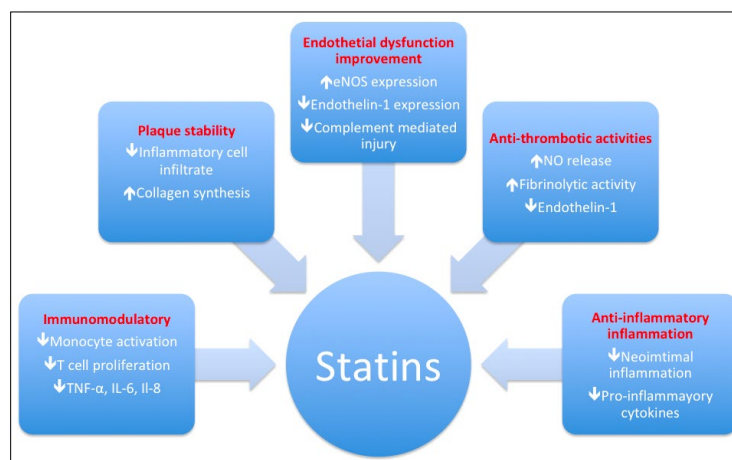


Figure 1. Pleiotropic effects of statins in atherosclerotic disease: Focus on the endothelial dysfunction.

REFERENCES

- Mangieri E, Macchiarelli G, Ciavolella M, Barilla F, Avella A, et al. (1996) Slow coronary flow: Clinical and histopathological features in patients with otherwise normal epicardial coronary arteries. *Cathet Cardiovasc Diagn* 37: 375-381.
- Beltrame JF, Limaye SB, Horowitz JD (2002) The coronary slow flow phenomenon - A new coronary microvascular disorder. *Cardiology* 97: 197-202.
- Mosseri M, Yarom R, Gotsman MS, Hasin Y (1986) Histologic evidence for small vessel coronary artery disease in patients with angina pectoris and patent large coronary arteries. *Circulation* 74: 964-972.
- Beltrame JF, Limaye SB, Wuttke RD, Horowitz JD (2003) Coronary hemodynamic and metabolic studies of the coronary slow flow phenomenon. *Am Heart J* 146: 84-90.
- Pekdemir H, Polat G, Cin VG, Camsari A, Cicek D, et al. (2004) Elevated plasma endothelin-1 levels in coronary sinus during rapid right atrial pacing in patients with slow coronary flow. *Int J Cardiol* 97: 35-41.
- Senen K, Yetkin E, Turhan H, Atak R, Sivri N, et al. (2004) Increased thrombolysis in myocardial infarction frame counts in patients with isolated coronary artery ectasia. *Heart Vessels* 19: 23-26.
- Sezgin AT, Sigirci A, Barutcu I, Topal E, Sezgin N, et al. (2003) Vascular endothelial function in patients with slow coronary flow. *Coron Artery Dis* 14: 155-161.

8. Camsarl A, Pekdemir H, Cicek D, Polat G, Akkus MN, et al. (2003) Endothelin-1 and nitric oxide concentrations and their response to exercise in patients with slow coronary flow. *Circ J* 67: 1022-1028.
9. Kurtoglu N, Akcay A, Dindar I (2001) Usefulness of oral dipyridamole therapy for angiographic slow coronary artery flow. *Am J Cardiol* 87: 777-779.
10. Tanriverdi H, Evrengul H, Enli Y, Kuru O, Selecic D, et al. (2007) Effect of homocysteine-induced oxidative stress on endothelial function in coronary slow-flow. *Cardiology* 107: 313-320.
11. Salazar JJ, Ramírez AI, de Hoz R, Rojas B, Ruiz E, et al. (2007) Alterations in the choroid in hypercholesterolemic rabbits: Reversibility after normalization of cholesterol levels. *Exp Eye Res* 8: 412-422.
12. Balmforth C, van Bragt JJ, Ruijs T, Cameron JR, Kimmitt R, et al. (2016) Chorioretinal thinning in chronic kidney disease links to inflammation and endothelial dysfunction. *JCI Insight* 1: 1-13.
13. Kim H, Lee SC, Kwon KY, Lee CS (2016) Subfoveal choroidal thickness as a predictor of treatment response to anti-vascular endothelial growth factor therapy for polypoidal choroidal vasculopathy. *Graefes Arch Clin Exp Ophthalmol* 254: 1497-1503.
14. Ahmad M, Kaszubski PA, Cobbs L, Reynolds H, Smith RT (2017) Choroidal thickness in patients with coronary artery disease. *PLoS One* 12: 1-12.
15. Altinkaynak H, Kara N, Sayın N, Güneş H, Avşar S, et al. (2014) Subfoveal choroidal thickness in patients with chronic heart failure analyzed by spectral-domain optical coherence tomography. *Curr Eye Res* 39: 1123-1128.
16. Kantar BG, Kantar HS (2018) Relationship between angiographic coronary slow flow phenomenon and subfoveal choroidal thickness: What is the effect of atorvastatin therapy? *Eur Exp Biol* 8: 9.
17. Yilmaz H, Demir I, Uyar Z (2008) Clinical and coronary angiographic characteristics of patients with coronary slow flow. *Acta Cardiol* 63: 579-584.
18. Wassmann S, Faul A, Hennen B, Scheller B, Bohm M, et al. (2003) Rapid effect of 3-hydroxy-3-methylglutaryl coenzyme A reductase inhibition on coronary endothelial function. *Circ Res* 93: 98-103.
19. Stroes ES, Koomans HA, de Bruin TW, Rabelink TJ (1995) Vascular function in the forearm of hypercholesterolemic patients off and on lipid-lowering medication. *Lancet* 346: 467-471.
20. Hernandez-Perera O, Perez-Sala D, Navarro-Antolin J, Sanchez-Pascuala R, Hernandez G, et al. (1998) Effects of the 3-hydroxy-3-methylglutaryl-CoA reductase inhibitors, atorvastatin and simvastatin, on the expression of endothelin-1 and endothelial nitric oxide synthase in vascular endothelial cells. *J Clin Invest* 101: 2711-2719.
21. Plenge JK, Hernandez TL, Weil KM, Poirier P, Grunwald GK, et al. (2002) Simvastatin lowers C-reactive protein within 14 days: An effect independent of low-density lipoprotein cholesterol reduction. *Circulation* 106: 1447-1452.
22. Jialal I, Stein D, Balis D, Grundy SM, Adams-Huet B, et al. (2001) Effect of hydroxymethyl glutaryl coenzyme A reductase inhibitor therapy on high sensitive C-reactive protein. *Circulation* 103: 1933-1935.
23. Weber C, Erl W, Weber KS, Weber PC (1997) HMG-CoA reductase inhibitors decrease CD11b expression and CD11b-dependent adhesion of monocytes to endothelium and reduce increased adhesiveness of monocytes isolated from patients with hypercholesterolemia. *J Am Coll Cardiol* 30: 1212-1217.