

permanent loss of spine motion and development of adjacent level abnormalities [9-12]. Research has indicated the development of adjacent level abnormalities leading to additional surgery is between 3% and 5% per year after an anterior cervical fusion [13]. Several review articles of the literature indicate the clinical success rates of anterior cervical fusion at one level are about 70% with a reoperation rate at the two-year follow-up of 10% [14]. The clinical results of anterior cervical discectomy and fusion (ACDF) decreases the more levels that are fused [15,16]. Another inherent problem with anterior cervical fusion is the failure of the fusion to heal. This results in what is called a pseudoarthrosis or failure of fusion. Half the patients with this situation generally require a second surgery in an attempt to obtain a fusion [17,18].

Cervical artificial disc replacement has become a preferred surgical option. This procedure underwent FDA testing beginning around 2005. McAfee, et al, published a metaanalysis comparing outcomes of cervical artificial disc versus anterior cervical fusion at one level. This metaanalysis reported superior reports with the use of an artificial disc versus a fusion at a single level when considering adjacent level degeneration [19]. Recently, an artificial disc has been approved for two levels and the prospective randomized study supporting this also indicated superior results with an artificial disc versus fusion at two levels [20]. There have been numerous papers published indicating the clinical superiority of cervical artificial disc over fusion subsequent to 2005 [21-27]. One persistent problem, however, is that many patients have degenerative changes at more than two levels, which is a prognostic indicator of poorer outcomes in surgical procedures.

Patients who have three or more degenerated discs in the cervical spine present a very difficult surgical treatment situation. The surgical results of three- and four-level anterior cervical fusions are certainly less than the 70% success rate reported with fusion at a single level. Thus, patients with more than two levels of degenerative changes in their neck have very poor surgical options [15,16]. Performing cervical artificial disc replacements at more than two levels is unusual and would very rarely be covered under insurance benefits.

The use of biologics to treat disc abnormalities is a possible non-surgical option which potentially can bridge the gap between traditional non-surgical treatments for cervical degenerative disc abnormalities and surgery. There is mounting evidence to support the use of biologic and cell based therapy for chronic discogenic low back pain, a condition with similar etiology [28,29]. The authors of this paper have published both one and two-year follow-up from a study assessing the safety and efficacy of bone marrow concentrated cells as an alternative to surgery for discogenic back pain at one or two levels [30,31]. There have been numerous studies utilizing mesenchymal stem cells to

enhance tissue repair and decrease inflammatory damage in both in vitro lab studies and in vivo clinical models [32-36]. It is known that bone marrow aspirate concentrate (BMAC/BMC), the treatment used in this study, contains mesenchymal stem cells as well as a number of other cell types including but not limited to: hematopoietic stem cells, endothelial progenitor cells, and platelets. Studies have shown both the mesenchymal stem cell population and other nucleated cell types have healing properties and may contribute in a synergistic fashion to the healing seen in studies on the lumbar spine [37-44].

This is the first study to evaluate the potential of intradiscal bone marrow concentrate to treat patients who have symptomatic degenerated cervical discs and associated chronic axial neck pain, headaches, and radiating arm pain.

MATERIALS AND METHODS

Study Design

This study is a prospective open-label non-randomized evaluation of patients having an injection of bone marrow concentrate (BMC) into symptomatic cervical discs. The patients enrolled as subjects in this study presented clinically with symptomatic moderate to severe chronic axial neck pain. Axial neck pain was also associated with interscapular pain, headaches, and radiating arm pain. Abnormalities were present on cervical MRI scanning and plain radiographs. These abnormalities include anterior and posterior osteophyte formation, disc space narrowing on plain radiographs, and nucleus pulposus desiccation on MRI scanning.

Pre-treatment baseline neck disability index (NDI) was a minimum of 30mm/100mm and pre-treatment baseline axial neck pain was at least 40mm/100mm on visual analog scale (VAS) pain scores. The patients were required to sign and fully comprehend an informed consent document before participating in the study. All patients underwent a pre-injection medical history and physical examination along with the neck disability index and visual analog scale pain scores. These questionnaires were repeated at six weeks, three months, six months, 12 months, and 24 months post injection of bone marrow concentrate. The patients' primary physical complaint in this study was one of axial neck pain with associated interscapular and headaches and may or may not have included radicular arm pain. Standard exclusion criteria included evidence of a symptomatic herniated disc. Patient demographics are listed in **Table 1**.

Bone Marrow Collection and Processing

Bone marrow aspirate (BMA, 55ml) was collected over acid citrate dextrose-anticoagulant (ACD-A, 5ml) from the patient's posterior iliac crest. The procedure was performed with IV sedation consisting of Versed and Fentanyl. Positioning of the Jamshidi needle in the iliac wing was confirmed by fluoroscopy. BMA was collected in a 60ml

syringe in a series of discrete pulls on the plunger (targeting a collection of 5-10ml per pull) with repositioning of the needle tip between pulls based on the reported enrichment of progenitor cells by (Hernigou et al 2013) [45]. The BMA was processed using the ART21 system (Celling Biosciences, Austin, TX) to produce a bone marrow concentrated cell preparation. The 55ml of BMA were centrifuged for 12 minutes to produce 3ml of BMC. The 3ml of BMC were drawn from the processed device and then 0.175 cc of 50% glucose and 0.175cc of bicarbonate were added to the 3ml of BMC which was then immediately transferred to the physician for injection [46].

Table 1. Patient demographics

Number of enrolled patients		182
Male:Female		97:85
Number of levels injected	1 level	33
	2 levels	60
	3 levels	45
	4 levels	44
Average number of levels injected		2.44
Age range		18-81 (median 54.5)
Average BMI		26
Average pre-injection NDI		44.5 (12-100)
Average pre-injection VAS		58.9 (10-100)

Interdiscal Injection

With the patient in a supine position, the skin overlying the disc to be injected was anesthetized with 1% buffered

Lidocaine. Bone marrow concentrate was percutaneously injected into the symptomatic cervical discs through the standard anterolateral approach on the patient’s right side of the cervical spine. Digital pressure was utilized to separate the carotid sheath and sternocleidomastoid laterally and trachea and esophagus medially and then a 20-gauge needle was placed into the disc space and centered on the anterior posterior and lateral fluoroscopy. Approximately 0.5ml of bone marrow concentrate was used per symptomatic cervical disc. The entire procedure averaged less than 45 minutes.

Patients were prescribed pain medication to be used as needed for three days and put on restricted physical activity for two weeks.

RESULTS

Pre-procedure neck disability index (NDI) was 44.5 (range 12-100) and visual analog scale (VAS) was 62 (range 10-100). Six-month follow-up NDI and VAS were 17.4 and 22.5. One-year NDI and VAS were 15.8 and 21.4. Two-year follow-up NDI and VAS were 16.5 and 20.7. All scores had a p-value of less than 0.001. This represents a 63% improvement in NDI and a 67% improvement in VAS at the two year follow up. There was no difference in the clinical results comparing one, two, three, or four disc levels injected. There were no injection complications and no patient was made worse from the procedure. No patient had surgery during the study. Figure One details the pre-procedure and post-procedure changes in NDI through two-year follow-up. Notice there was no difference in NDI improvement comparing the number of disc levels treated. Figure Two details the pre-procedure and post-procedure changes in VAS through two-year follow-up. Notice there was no difference in VAS improvement comparing the number of disc levels treated. The results in figure one and two represent all 182 patients.

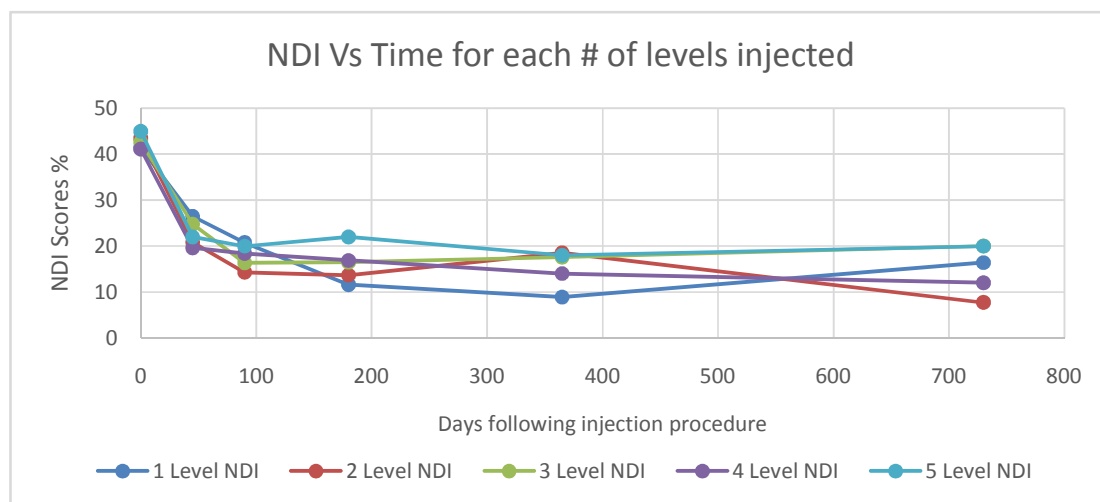


Figure 1. NDI Vs Time for each # of levels injected

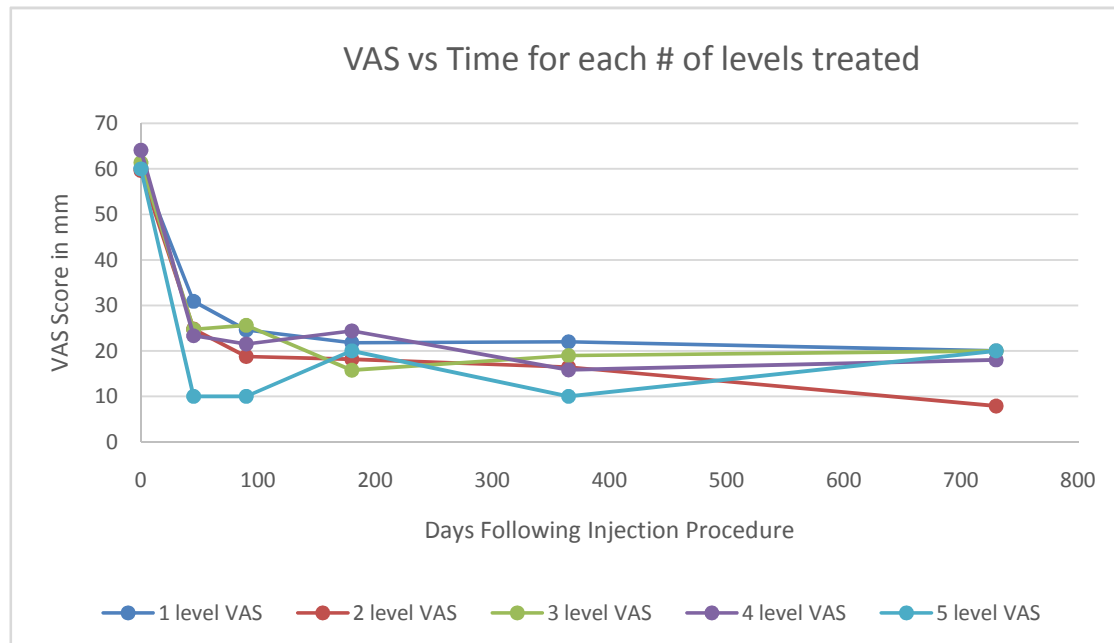


Figure 2. VAS vs Time for each # of levels treated

Analysis of the Bone Marrow Concentrate

This section is included from a previously published paper to detail the BMC cell analysis expected in these patients [30]. The paper involved a prospective study of 26 patients with discogenic low back pain. The demographics of those patients was similar to this study of patients with the same diagnosis in the cervical spine. This information is included to detail the method of cell analysis and MSC cell counts expected in this group of 182 patients.

Cell analysis and characterization of 20 out of the 26 patients' BMC samples were performed. An aliquot (1ml) of each subject's BMC was packed in a shipping container with 5°C cold packs and shipped overnight to the cell analysis laboratory (Celling Biosciences, Austin, TX). The samples were received and processed immediately to determine total nucleated cell (TNC) count and viability using a NucleoCounter NC-100 (Chemometec, Denmark). The BMC was diluted in phosphate buffered saline (PBS, Invitrogen, Grand Island, NY) with 2% fetal bovine serum (FBS, HyClone human mesenchymal grade, Thermo Scientific, Waltham, MA) and subjected to a Ficoll-Paque (GE Healthcare Life Sciences, Piscataway, NJ) gradient separation (1:1 cell solution to Ficoll ratio by volume) in order to deplete red blood cells. Analysis of the recovered cells included performing colony-forming unit-fibroblast and osteogenic (CFU-F and CFU-O, respectively) assays and phenotypic analysis by flow cytometry. For phenotype analysis, fresh (noncultured) BMC cells were stained with a

series of rabbit anti-human monoclonal antibodies for a hematopoietic lineage-committed (nonprogenitor) panel of markers including CD2, 3, 8, and 11b (APC-Cy7), CD34 (PE), CD90 (FITC), and CD105 (APC) as well as appropriate isotype controls. Isotype, single color stain, and four-color stain samples were analyzed by a Guava EasyCyte 8HT (Millipore, Billerica, MA). The CFU-F assay was performed by creating a dilution series (in culture medium with 5% FBS and 1% antibiotics) of each cell preparation at concentrations of 50,000-500,000 TNC per well in standard 12-well plates. The plates were placed in an incubator at 37°C, 5% CO₂, and 100% humidity for 72 hours when the medium was replaced. Medium was replaced every 3 days. After 9 days in culture, wells were gently washed with PBS, fixing the colonies/cells with methanol, staining the attached cells with Crystal Violet, rinsing with water, and air-drying the plates. Visualization and counting of the colonies were done with an inverted microscope. Colonies containing 20 or more cells were scored as a CFU-F. The CFU-O assay was performed identically as CFU-F, but after 9 days the medium was changed to an osteogenic induction medium (Advance STEM Osteogenic Differentiation Kit, HyClone, Logna, UT) for an additional 9 days with complete medium change every 3 days. On day 18, the wells were washed with PBS, then fixed for 15 minutes in 2% formalin solution, and costained for alkaline phosphatase activity (Vector Blue ALP, Vector Labs, Burlingame, CA) and calcified extracellular matrix (0.5% Alizarin Red solution, Sigma-Aldrich, St. Louis, MO).

Outcome Assessment and Analysis

There were no serious complications from harvesting the bone marrow concentrate or the disc injections. The most common events were transient pain at the harvest site and discomfort at the injection site, both of which typically resolved within 48 hours of treatment. Not every patient improved significantly, but no patient reported increases in visual analog scale or neck disability index from pre-

treatment scores. Patient follow up outcomes were obtained by independent reviewers who were not investigators with the study. The reviewers were paid senior pre-med students. Univariable data comparisons of baseline to follow-up were analyzed using a two-tailed student's t-test with a 95% confidence interval (Alpha=0.05, Microsoft Excel). Demographic comparisons were done using paired sample t-tests (www.socscistatistics.com).

Table 2. Average cell viability, TNC, total and frequency of CFU-F/CFU-O, and CD marker phenotypes in fresh bone marrow concentrate

Cell viability at 24 hours	98.1 (±1.2)%	TNC/ml in BMC	121 (±11) x 10 ⁶
Cell phenotype subpopulation	% of TNC	Subpopulation Concentration in BMC (cells per milliliter)	
CFU-F	0.0025%	2,713 (±491) per ml	
CFU-O	0.0027%	2,913 (±418) per ml	
Lineage ⁻ cells (CD 2/3/8/11b ⁻)	25.89%	31.5 x 10 ⁶ /ml	
Lineage ⁻ /CD34 ⁺	1.397%	1.69 x 10 ⁶ /ml	
Lineage ⁻ /CD34 ^{High} /CD90+/CD105+	0.0007%	802/ml	
Lineage ⁻ /CD34 ^{Low} /CD90+/CD105+	0.0040%	4,832/ml	
Lineage ⁻ /CD34 ⁻ /CD90+/CD105+	0.0049%	5,914/ml	

Table 3. Inclusion and exclusion criteria for enrolled patients

Inclusion Criteria	Exclusion Criteria
Males/females between 16 and 80 years old	Previous surgical procedure at any cervical level
History of axial neck pain > 6 months	Diagnosis of or MRI evidence of symptomatic spinal stenosis or soft cervical disc herniation
Moderate to severe symptomatic cervical disc degeneration based on increased Pfirrmann grades (4-7), bulging discs, or annular tears on MRI examination, and anterior/posterior osteophytes on MRI or plain radiographs	Abnormal examination indicating infective or neoplastic growth as primary cause of pain
Continued pain after 6 months of conservative measures	Active malignancy (current or within 5 years)
Moderate to severe pain and disability based on 30/100 or higher NDI and greater than 40/100mm on visual analog pain scale	Any significant comorbidity that, in the opinion of the investigators, might interfere with the outcomes or adversely affect the treatment process
No recent (3 months) epidural steroid injections	Vulnerable patients including children, those with substance dependencies, the mentally ill, or anyone not capable of satisfactorily providing informed consent
Willingness to perform follow-up examinations, sign consent form	Unwilling or incapable of performing follow-up score testing

*These are the same inclusion/exclusion criteria used for all current FDA lumbar spine biologic studies

Several human studies have recently been published documenting the clinical results of utilizing biologics to treat symptomatic chronic lumbar discogenic pain. The Coric, Pettine study was an FDA phase one evaluation of utilizing expanded juvenile cartilage cells to treat discogenic low back pain [47]. Fifteen patients were injected at one lumbar level with 10 million cells and followed for one year. ODI went from 53.3 to 20.3 (p-value<0.0001) and SF-36 improved from 35.3 to 46.9 (p-value<0.0002). MRI improvement of at least one Pfirrmann grade was observed in 77% of patients. No patient had surgery. Pettine, et al, have published one- and two-year follow-up studies on 26 patients injected with bone marrow concentrate (the same as this study) for discogenic low back pain. Average improvement in ODI was 64% and VAS was 71%. Only five of the 26 patients had surgery [30,31].

This study is a prospective non-randomized open label evaluation of 182 patients followed for two years to obtain preliminary data on the safety and efficacy of utilizing BMC to treat symptomatic cervical degenerated discs.

The results in this group of 182 patients undergoing a single injection of BMC into 1 to 4 discs in the cervical spine was unexpected. The two-year follow-up showed an average improvement in NDI of 63% and VAS of 67% (p<0.001). No patient was made worse and no patient underwent surgery during the follow up.

Limitations of this study include: no randomized control, no follow-up MRI scan data, and no cell count data. The author has published MRI follow-up data and cell count data in a similar group of patients in the lumbar spine [30,31].

CONCLUSION

Patients with more than two levels of symptomatic discogenic cervical pain have limited treatment options. There is minimal literature reporting the long-term efficacy of any non-operative treatment and these patients basically have minimal surgical options. Two-year follow-up data in treating multilevel discogenic cervical pain with the BMC showed an improvement in NDI of 63% (p<0.001) and VAS of 67% (p<0.001). No patient was made worse from the procedure and there were no complications from the percutaneous injection of BMC into the disc. Utilizing MSCs derived from BMC, based on these preliminary results, may offer patients with multilevel discogenic cervical pain a viable treatment option.

I would like to acknowledge the help of Dylan Merideth and Nick Collins in obtaining patient follow up.

REFERENCES

- Hoy DG, Protani M, De R, Buchbinder R (2010) The epidemiology of neck pain. *Best Pract Res Clin Rheumatol* 24: 783-792.
- Fejer R, Kyvik KO, Hartvigsen J (2006) The prevalence of neck pain in the world population: a systematic critical review of the literature. *Eur Spine J* 15: 834-848.
- Biondi DM (2005) Cervicogenic headache: a review of diagnostic and treatment strategies. *J Am Osteopath Assoc* 105: 16S-22S.
- Brodke DS, Zdeblick TA (1992) Modified Smith-Robinson procedure for anterior cervical discectomy and fusion. *Spine (Phila Pa 1976)* 17: S427-430.
- Brown JA, Havel P, Ebraheim N, Greenblatt SH, Jackson WT (1988) Cervical stabilization by plate and bone fusion. *Spine (Phila Pa 1976)* 13: 236-240.
- Cummins BH, Robertson JT, Gill SS (1998) Surgical experience with an implanted artificial cervical joint. *J Neurosurg* 88: 943-948.
- Fraser JF, Härtl R (2007) Anterior approaches to fusion of the cervical spine: a metaanalysis of fusion rates. *J Neurosurg Spine* 6: 298-303.
- Zindrick M, Harris MB, Humphreys SC, O'Leary PT, Schneiderman G, et al. (2010) Cervical disc arthroplasty. *J Am Acad Orthop Surg* 18: 631-637.
- Eck JC, Humphreys SC, Lim TH, et al. (2002) Biomechanical study on the effect of cervical spine fusion on adjacent-level intradiscal pressure and segmental motion. *Spine* 27: 2431-2434.
- Chang UK, Kim DH, Lee MC, et al. (2007) Changes in adjacent-level disc pressure and facet joint force after cervical arthroplasty compared with cervical discectomy and fusion. *J Neurosurg Spine* 7: 33-39.
- Dmitriev AE, Cunningham BW, Hu N, et al. (2005) Adjacent level intradiscal pressure and segmental kinematics following a cervical total disc arthroplasty: an in vitro human cadaveric model. *Spine* 30: 1165-1172.
- Elsawaf A, Mastronardi L, Roperto R, et al. (2008) Effect of cervical dynamics on adjacent segment degeneration after anterior cervical fusion with cages. *Neurosurg Rev* 32: 215-224.
- Hilibrand AS, Carlson GD, Palumbo MA, Jones PK, Bohlman HH (1999) Radiculopathy and myelopathy at segments adjacent to the site of a previous anterior cervical arthrodesis. *J Bone Joint Surg Am* 81: 519-528.
- Pettine KA, Eisermann L (2010) Meta-analysis of class I and II data on results of anterior cervical

- decompression and fusion. North American Spine Society, Orlando, FL.
15. Fraser JF, Härtl R (2007) Anterior approaches to fusion of the cervical spine: a metaanalysis of fusion rates. *J Neurosurg Spine* 6: 298-303.
 16. Wang JC, McDonough PW, Kanim LE, et al. (2001) Increased fusion rates with cervical plating for three-level anterior cervical discectomy and fusion. *Spine* 26: 643-646.
 17. Bohlman HH, Emery SE, Goodfellow DB, Jones PK (1993) Robinson anterior cervical discectomy and arthrodesis for cervical radiculopathy. Long-term follow-up of one hundred and twenty-two patients. *J Bone Joint Surg Am* 75: 1298-1307.
 18. Emery SE, Fisher JR, Bohlman HH (1997) Three-level anterior cervical discectomy and fusion: radiographic and clinical results. *Spine* 22: 2622-2624.
 19. McAfee PC, Reah C, et al. (2012) Meta-Analysis of comparative outcomes following cervical arthroplasty or anterior cervical fusion. *Spine* 37: 943-952.
 20. Bae HW, Kim KD, Nunley PD, et al. (2015) Comparison of clinical outcomes of 1- and 2-level total disc replacement: four-year results from a prospective, randomized, controlled, multicenter IDE clinical trial. *Spine* 40: 759-766.
 21. Gao F, Mao T, Sun W, et al. (2015) An updated meta-analysis comparing artificial cervical disc arthroplasty (CDA) versus anterior cervical discectomy and fusion (ACDF) for the treatment of cervical degenerative disc disease (CDDD). *Spine* 40: 1816-1823.
 22. Delamarter RB, Zigler J (2013) Five-year reoperation rates, cervical total disc replacement versus fusion, results of a prospective randomized clinical trial. *Spine* 38: 711-717.
 23. Murrey D, Janssen ME, Delamarter RB, et al. (2009) Results of the prospective, randomized, controlled multicenter Food and Drug Administration investigation device exemption study of the ProDisc-C total disc replacement and fusion for the treatment of one level symptomatic cervical disc disease. *Spine J* 9: 275-286.
 24. Burkus J, Haid R, Traynelis V, et al. (2010) Long-term clinical and radiographic outcomes of cervical disc replacement with the Prestige disc: results from a prospective, randomized controlled clinical trial. *J Neurosurg Spine* 12: 308-318.
 25. Zhang X, Zhang X, Chen C, et al. (2012) Randomized, controlled, multicenter, clinical trial comparing Bryan Cervical Disc arthroplasty with anterior cervical decompression and fusion in China. *Spine* 37:433-438.
 26. Garrido B, Wilhite J, Nakano M, et al. (2011) Adjacent-level cervical ossification after Bryan cervical disc arthroplasty compared with anterior cervical discectomy and fusion. *J Bone Joint Surg Am* 93: e76.
 27. Anderson PA, Sasso RC, Riew KD (2008) Comparison of adverse events between the Bryan artificial cervical disc and anterior cervical arthrodesis. *Spine* 33: 1305-1312.
 28. Murphy MB, Moncivals K, Caplan AI (2013) Mesenchymal stem cells: Environmentally responsive therapeutics for regenerative medicine. *Exp Mol Med* 45: e54.
 29. Murphy MB, Blashki D, Buchanan RM, et al. (2012) Adult and umbilical cord blood-derived platelet-rich plasma for mesenchymal stem cell proliferation, chemotaxis, and cryo-preservation. *Biomaterials* 33: 5308-5316.
 30. Pettine KA, Murphy MB, Suzuki RK, et al. (2015) Percutaneous injection of autologous bone marrow concentrate cells significantly reduces lumbar discogenic pain through 12 months. *Stem Cells* 33: 146-156.
 31. Pettine KA, Suzuki RK, Sand T, et al. (2016) Treatment of discogenic back pain with autologous bone marrow concentrate injection with minimum two-year follow-up. *Int Orthop* 40: 135-140.
 32. Gruber HE, Ingram JA, Davis DE, Hanley EN Jr (2009) Increased cell senescence is associated with decreased cell proliferation in vivo in the degenerating human annulus. *Spine J* 9: 210-215.
 33. Gruber HE, Johnson TL, Leslie K, Ingram JA, Martin D, et al. (2002) Autologous intervertebral disc cell implantation: a model using Psammomys obesus, the sand rat. *Spine (Phila Pa 1976)* 27: 1626-1633.
 34. Ganey T, Libera J, Moos V, et al. (2003) Disc chondrocyte transplantation in a canine model: a treatment for degenerated or damaged intervertebral disc. *Spine* 28: 2609-2620.
 35. Ganey TM, Meisel HJ (2002) A potential role for cell-based therapeutics in the treatment of intervertebral disc herniation. *Eur Spine J* 11 Suppl 2: S206-214.

36. Meisel HJ, Ganey T, Hutton WC, Libera J, Minkus Y, et al. (2006) Clinical experience in cell-based therapeutics: intervention and outcome. *Eur Spine J* 15 Suppl 3: S397-405.
37. Zhang YG, Guo X, Xu P, et al. (2005) Bone mesenchymal stem cells transplanted into rabbit intervertebral discs can increase proteoglycans. *Clin Orthop Relat Res* 430: 219-226.
38. Sakai D, Mochida J, Iwashina T, et al. (2005) Differentiation of mesenchymal stem cells transplanted to a rabbit degenerative disc model: potential and limitations for stem cell therapy in disc regeneration. *Spine* 30: 2379-2387.
39. Sakai D, Mochida J, Iwashina T, et al. (2006) Regenerative effects of transplanting mesenchymal stem cells embedded in collagen to the degenerated intervertebral disc. *Biomaterials* 27: 335-345.
40. Sheikh H, Zakharian K, De La Torre RP, Facek C, Vasquez A, et al. (2009) In vivo intervertebral disc regeneration using stem cell-derived chondroprogenitors. *J Neurosurg Spine* 10: 265-272.
41. Caplan AI, Correa D (2011) The MSC: an injury drugstore. *Cell Stem Cell* 9: 11-15.
42. Wakao S, Kuroda Y, Ogura F, Shigemoto T, Dezawa M (2012) Regenerative Effects of Mesenchymal Stem Cells: Contribution of Muse Cells, a Novel Pluripotent Stem Cell Type that Resides in Mesenchymal Cells. *Cells* 1: 1045-1060.
43. Caplan AI (2008) All MSCs are pericytes? *Cell Stem Cell* 3: 229-230.
44. Gimble JM, Katz AJ, Bunnell BA (2007) Adipose-derived stem cells for regenerative medicine. *Circ Res* 100: 1249-1260.
45. Hernigou P, Poignard A, Beaujean F, et al. (2005) Percutaneous autologous bone-marrow grafting for nonunions. Influence of the number and concentration of progenitor cells. *J Bone Joint Surg Am* 87: 1430-1437.
46. Kenneth Allen Pettine (2016) Regenerative Autologous Bone Marrow Cell Therapies and Methods for Their Use in the Treatment of Joint Pain, Patent No. 9,408,874.
47. Coric D, Pettine KA, Sumich A, et al. (2013) Prospective study of disc repair with allogenic chondrocytes presented at the 2012 Joint Spine Section Meeting. *J Neurosurg Spine* 18: 85-95.
48. Rubin R, Strayer D (2008) Rubin's pathology: clinicopathologic foundations of medicine. Lippincott Williams & Wilkins.