

Ultrasound Guided Thoracolumbar Interfascial Plane Block: An Exceptional Anesthetic Technique for Awake Transforaminal Endoscopic Single Level Lumbar Discectomies

Somita Christopher*, Krupa Mulgaonkar, Anu Singh and Gopal TVS

*Department of Anesthesia, Intensive Care and Pain Management, Care Hospitals, Banjara Hills, Hyderabad, Telangana, India.

Received December 02, 2019; Accepted December 23, 2019; Published April 27, 2020

ABSTRACT

The rising awareness for opioid free analgesia and enhanced recovery after surgery has led to an increasing popularity of regional anesthesia. Perioperative pain management in lumbar surgeries is a challenge for the anesthesiologists as these patients are already suffering from chronic pain and the methods available have remained limited.

Thoracolumbar Interfascial Plane Block (TLIP) is a relatively new technique that targets the dorsal rami of the thoracolumbar nerves as they pass through the paraspinal musculature. We describe here a series of ten patients who underwent endoscopic lumbar discectomies solely under TLIP block.

All the patients maintained a visual analogue score (VAS) of 0-2 during the surgery and 24 h post-operatively. None of the patients required opioids in the post-operative period.

Keywords: Thoracolumbar interfascial plane block, Disc herniation, post-operative analgesia, Endoscopic discectomy, Manuscript

INTRODUCTION

Lumbar disc herniation is the major cause of back pain and sciatica. In recent years a number of endoscopic procedures for lumbar disc herniation have been developed in terms of minimally invasive spine surgery (MISS) with clinical outcomes comparable to those of conventional open surgery [1]. Some of the advantages of endoscopic lumbar spine surgery are reduced blood loss, less muscle trauma; early functional recovery and reduced hospital stay [2]. We present here ten cases of awake transforaminal endoscopic discectomies which were done under thoracolumbar interfascial plane block (TLIP).

METHODOLOGY

Ten patients who were scheduled to undergo endoscopic discectomy were chosen randomly to receive TLIP block to evaluate its efficacy for perioperative analgesia without general anesthesia. All the patients had single nerve root lesions including sequestered or migrated disc at L4-5 or L5-S1. Pre-operatively, all the patients underwent magnetic resonance imaging to access the adequacy of decompression (**Figure 1**). The patient characteristics are given in **Table 1**. A detailed pre-anesthesia check-up was done and the patients were posted for the procedure after an informed written consent.

Corresponding author: Somita Christopher, Consultant, Department of Anesthesia, Intensive Care and Pain Management, Care Hospitals, Banjara Hills, Hyderabad, Telangana, India, Tel: 9701444512; E-mail: somitachristopher@yahoo.com

Citation: Christopher S, Mulgaonkar K, Singh A & Gopal TVS. (2020) Ultrasound Guided Thoracolumbar Interfascial Plane Block: An Exceptional Anesthetic Technique for Awake Transforaminal Endoscopic Single Level Lumbar Discectomies. Int J Anaesth Res, 3(1): 104-108.

Copyright: ©2020 Solanki N, Solanki S, Patel P, Kalotra K & Solanki H. This is an open-access article distributed under the terms of the Creative Commons Attribution License, which permits unrestricted use, distribution, and reproduction in any medium, provided the original author and source are credited.

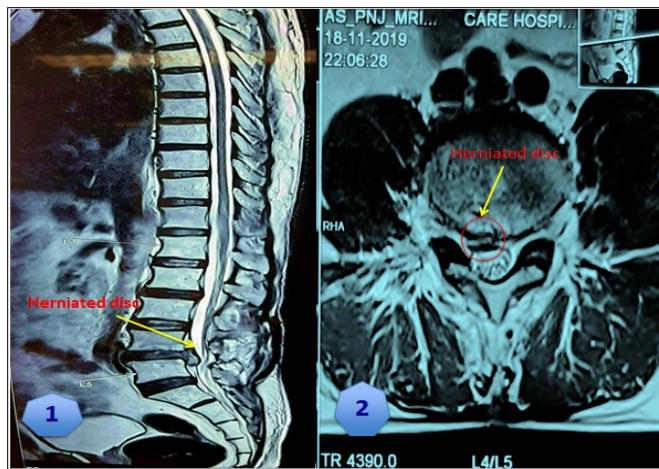


Figure 1. Perioperative.

1. Sagittal view; 2. Axial view showing migrated disc herniation at L4-L5 level in MRI (magnetic resonance imaging)

Table 1. Patient characteristics.

Age (years)	43 (24-62) years
ASA Classification (I/II)	7/3
Sex (Male/Female)	6/4

Values are presented in median range
 ASA: American Society of Anesthesiologists

In the operating room, after applying the standard American Society of Anesthesiology (ASA) monitors and establishing an intravenous line, the patients were placed in the prone position. Unilateral TLIP block was performed on the side of the endoscopic discectomy (Table 2). A curvilinear low frequency transducer using SonoSite Edge II ultrasound machine was used to identify and mark L3 lumbar vertebrae by counting up from L5-S1 in a para-sagittal oblique view (Figure 2). After cleaning, draping and rendering the transducer sterile, it was placed transversely at the level of L3 vertebrae to identify the spinous process. The transducer was then moved laterally to identify the multifidus (MF) and longissimus (LG) muscle interface. A 100 mm insulated echogenic needle was inserted in plane from lateral to medial direction through the bulk of LG muscle (Figure 3). Once the needle tip was identified deep to the midpoint of LG-MG interface, 15 ml of 0.375% of bupivacaine was

injected after negative aspiration (Figure 4). The needle was then redirected and 5 ml of local aesthetic (LA) was injected superficially to paraspinal muscles (Figure-5). All the patients received Inj midazolam 2 mg for light sedation. After 20 min, the patients were checked for adequacy of the block by loss of point discrimination to pinprick in the L2-S1 dermatomes on the side of the block. The average duration of surgery was 120 min (120-200 min) and all the patients remained hemodynamically stable throughout the procedure. Two patients complained of mild pain at the introduction of the scope for which they were given Injection Paracetamol 1 g and Injection fentanyl 25 µg as single doses. All the patients received Intravenous Paracetamol 1 g Q8 hourly in the post-operative period and had a VAS of 0-2 during the next 24 h. The patients were mobilized 4 h after the surgery and discharged on the next day.

Table 2. Surgery characteristics.

Site of endoscopy discectomy	L4-L5-7 patients L5-S1-3 patients
Slip of TLIP block	Right side - 6 patients Left side - 4 patients
Surgery time (min)	160 (120-200)

Values are presented as mean range
 TLIP: Thoracolumbar Interfascial Plane Block

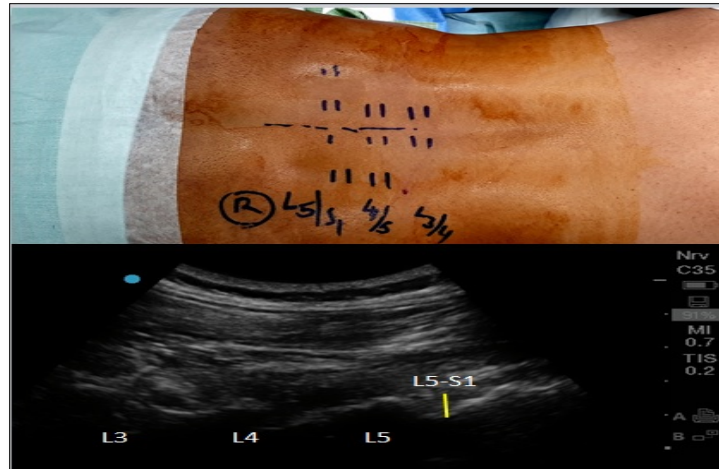


Figure 2. Identification of L3 vertebrae in parasagittal oblique view prior to the block.

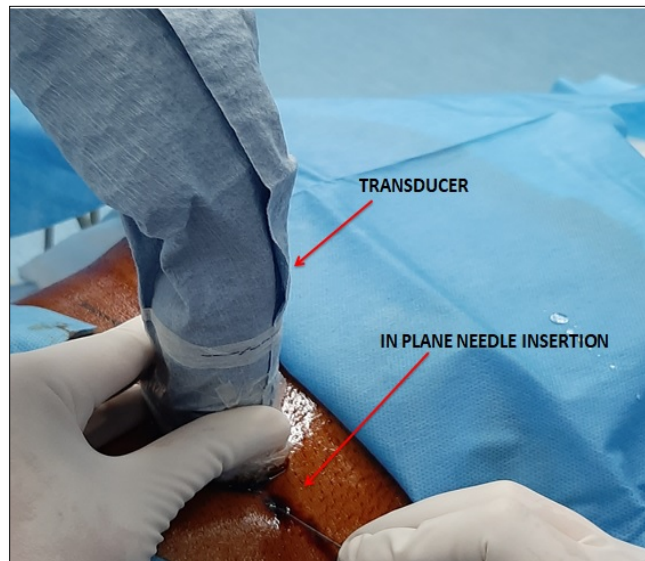


Figure 3. In plane needle insertion for TLIP block.

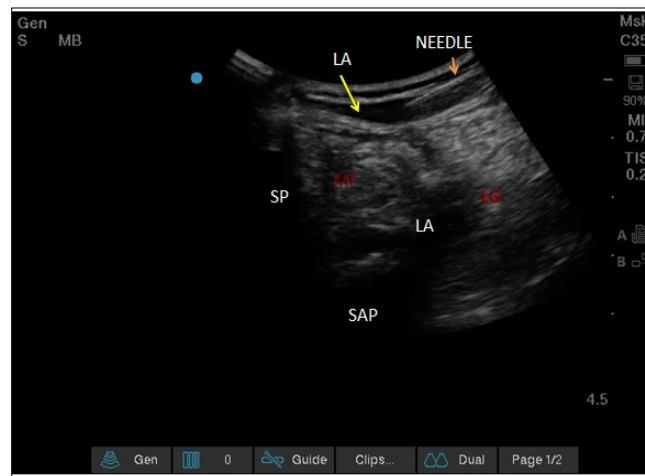


Figure 4. TLIP block. Injection between the multifidus (MF) and longissimus (LG) muscle on the right side. SP: Spinous Process; SAP: Superior Articular Process; LA: Local Anesthetic

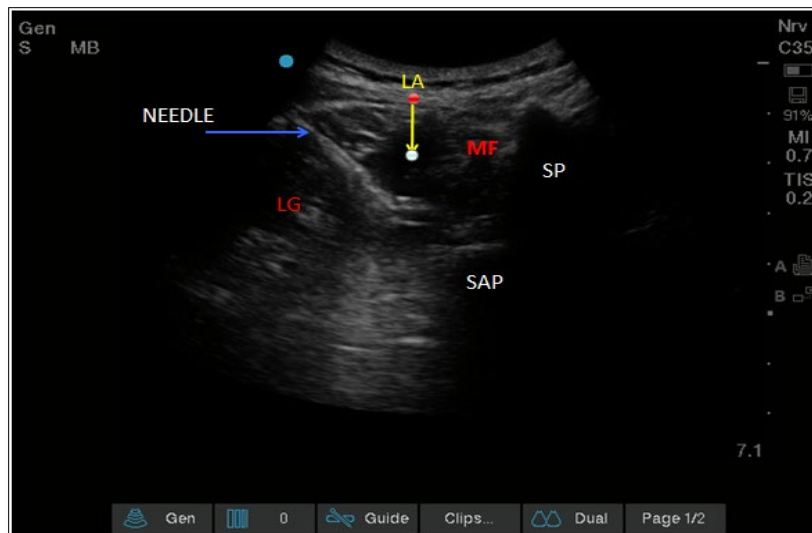


Figure 5. TLIP block - Injection of LA (local anesthetic) superficial to the paraspinal muscles and in the MF-LG interface on the left side.

SP: Spinous Process; SAP: Superior Articular Process; MF: Multifidus; LG: Longissimus

DISCUSSION

Thoracolumbar Interfascial Plane Block is an effective, safe and simple block for peri- and post-operative anesthesia and analgesia for lumbar laminectomies. The patients presenting for these surgeries have an additional burden of chronic pain along with long term consumption of analgesics or narcotics that alter pain perception thereby complicating pain management [3]. There are three muscle groups in the paraspinal area which have been described. These include multifidus, longissimus and iliocostalis from medial to lateral orientation. Lumbar spinal nerve emerges from the intervertebral foramina and divides into dorsal and ventral rami. The dorsal rami ascend at the junction between the spinous process and superior articular process and splits into three branches which emerge in the plane between the muscle groups [4].

TLIP block is a relatively new block which was first described in 2015 by Hand et al. [5]. The aim is to deposit the local anesthetic into the plane between the multifidus and longissimus muscle to block the dorsal rami of the thoracodorsal nerve as they pass through the paraspinal musculature. The second injection superficial to the paraspinal muscles results in further subcutaneous blockade. The extent of analgesia in our patients was between L2-S1 dermatomes as demonstrated by loss to pinprick sensation. In a study done by Ammar et al. [6], 3 ml of contrast medium was injected in one patient with the L.A to determine the extent and level of spread of the drug. In another study, the authors established loss of cold sensation in the T7-L1 dermatomes 20 min after injecting 20 ml of 0.25% bupivacaine for bilateral modified TLIP blocks [7]. All the previous studies have been done to demonstrate analgesia in patients undergoing lumbar laminectomies

under general anesthesia [6]. This case series is one of the first to demonstrate the efficacy of TLIP block in awake patients undergoing endoscopic lumbar discectomy. In our study, we injected 20 ml of L.A on the side of the surgery which gave excellent analgesia for 24 h. This is comparable to the retrospective study done by Ueshima et al [8]. Who demonstrated effective analgesia for 24 h after lumbar laminoplasty following bilateral TLIP blocks? None of our patients required opioids in the post-operative period. The VAS was significantly lower in these patients (0-2) even with active movement. Our results are comparable to the study done by Ahiskalioglu et al. [7] which concluded that patients receiving TLIP block consumed less fentanyl while reporting superior pain scores. Furthermore unlike other studies, we have used a low frequency curvilinear transducer for better penetration and wider field of view instead of high frequency linear transducer for performing the block.

LIMITATIONS

Although our patients were fairly comfortable throughout the procedure, there were many factors influencing the positive outcome. All the patients were fairly young individuals who did not have any major co-morbidity and tolerated the prone position fairly well. There were no patients with redo surgeries; hence we could not evaluate the role of TLIP block in patients undergoing revision lumbar laminectomies. The loss of sensation and adequacy of the block was tested by pin prick method; we did not do any contrast studies to evaluate the extent of the local anesthetic agent.

CONCLUSION

Therefore we conclude that TLIP block is a superficial, easy block which is a viable option for awake endoscopic

discectomies without any adverse effects. We believe that TLIP block will be the analgesic option of choice for post-operative analgesia after multi-level lumbar laminectomies as well there by reducing the need for opioids in these patients. Modified approach to TLIP block has been described, but large randomized trials are required to prove its efficacy [9].

REFERENCES

1. Choi G, Pophale CS, Patel B, Uniyal P (2017) Endoscopic spine surgery. J Korean Neurosurg Soc 60: 485-497.
2. Choi KC, Kim JS, Park CK (2016) Percutaneous endoscopic lumbar discectomy as an alternative to open lumbar microdiscectomy for large lumbar disc herniation. Pain Phys 19: E291-300.
3. Bhaskar SB, Bajwa SS (2013) Pharmacogenomics and anesthesia: Mysteries, correlations and facts. Indian J Anesth 57: 336-337.
4. Winiski LE (2019) Snell's Clinical Anatomy by Regions. 10th Edn. Philadelphia: Wolters Kluwer, p: 117.
5. Hand WR, Taylor JM, Harvey NR, Epperson TI, Gunselman RJ, et al. (2015) Thoracolumbar interfascial plane (TLIP) block: A pilot study in volunteers. Can J Anesth 62: 1196-1200.
6. Ammar MA, Tasimah M (2018) Evaluation of thoracolumbar interfascial plane block for post-operative analgesia after herniated lumbar disc surgery: A randomized clinical trial. Saudi J Anesth 12: 559-564.
7. Ahiskalioglu A, Yayik AM, Doymus O, Selvitopi K, Ahiskalioglu EO, et al. (2018) Efficacy of ultrasound guided modified thoracolumbar interfascial plane block for post-operative analgesia after spine surgery. A randomized controlled trial. Can J Anesth 65: 603-604.
8. Ueshima H, Ozawa T, Toyone T, Otake H (2017) Efficacy of the thoracolumbar interfascial plane block for lumbar laminectomy. A retrospective study. Asian Spine J 11: 722-725.
9. Ekinsi M, Ciftci B, Atalay YO (2019) Ultrasound-guided modified thoracolumbar interfascial plane block is effective for pain management following multi-level lumbar spinal fusion surgery. Ain-Shams J Anesthesiol 11: 24.