Ophthalmology Clinics & Research
OCR, 3(3): 173-175
www.scitcentral.com

ISSN: 2638-115X

Case Report: Open Access

Successfully Treated Isolated Cilioretinal Artery Occusion – A Case Report

Mehul A Shah* **and Shreya M Shah**

Drashti Netralaya, Dahod, Gujarat, India

Received September 06th, 2020; Revised October 01st, 2020; Accepted October 03rd, 2020

ABSTRACT

Introduction: Isolated cilioretinal artery occlusion is a rare clinical condition occurring in about 3% of retinal artery occlusion cases.

Methods: The present report describes the diagnosis and treatment of a 55-years old male patient who presented sudden, painless diminution of vision in the left eye since 24 hours previously. Best corrected visual acuity was 20/30, N6 in the right eye and finger counting near face in the left eye at the time of presentation. Anterior segment examination showed Relative afferent pupillary defect (RAPD). Dilated fundus examination of the left eye revealed an area of retinal ischemia with whitish edges in the superior papillomacular region. Optical Coherence Tomography (OCT) confirmed intraretinal oedema in the area of the infarct. The patient was diagnosed with left isolated cilioretinal artery occlusion, and was administered intravitreal injections (Bevacizumab + intra vitreal tiamcelone acetate).

Result: In the weekly follow up, left eye vision was found to be restored to 20/30, N6, with a significant decrease in intraretinal oedema.

Conclusion: Isolated cilioretinal artery occlusion though rare it is possible to regain structural and functional integrity.

Summary: This is a case report which reports isolated cilioretinal branch of central retinal branch, following treatment we reported structural and functional recovery.

Keywords: Isolated cilioretinal artery occlusion, Intravitreal injection, Bevacizumab, Intravitreal Triamcinolone Acetonide, Papillomacular infarction

INTRODUCTION

Human retina is nourished by two separate systems of blood circulation: the retinal circulation and the choroidal circulation, which supply blood to the inner and outer retinal layers respectively [1]. As a result, retinal artery occlusions most frequently affect the inner retinal layers rather than outer retinal layers, because the inner layers of the retina are nourished by the retinal blood vessels, whereas choroidal circulation supplies most of the oxygen to the outer layers of the retina.

The cilioretinal artery is a branch of the short posterior ciliary artery that has been reported to be clinically present in about 20% of human eyes, and angiographically present in approximately 32% of human eyes [2]. The point of entry into the retina is usually from the temporal aspect of the optic disc. Occlusion of this artery may occur in one of the following three ways: (i) in an isolated manner (Isolated occlusion); (ii) in association with Central Retinal Vein Occlusion, or (iii) in association with Anterior Ischemic Optic Neuropathy [3]. The first type i.e., isolated cilioretinal artery occlusion, is a rare clinical entity observed in only 3% of all retinal artery occlusions.

CASE REPORT

History

A 55 years old male patient was presented with the chief complaint of sudden, painless diminution of vision in his left eye since 24 h. Best corrected distance visual acuity was 6/9 in the right eye and Finger counting near face in the left eye. There was no H/O diabetes mellitus, hypertension, bleeding disorders or any other systemic illness.

Examination

Slit lamp examination revealed that the anterior segment was quiet and within normal limits in Right Eye and RAPD in Left Eye. Indirect ophthalmoscopy showed a normal right eye

Corresponding author: Mehul A Shah, Drashti Netralaya, near GIDC, Chakalia Road. Dahod, Gujarat, 389151, India, Tel: 00-91-2673-645364; Fax: 00-91-2673-221232; E-mail: omtrustdahod@gmail.com.

Citation: Shah MA & Shah SM. (2021) Successfully Treated Isolated Cilioretinal Artery Occusion – A Case Report. Ophthalmol Clin Res, 4(1): 183-185.

fundus, but revealed retinal ischemia in the left eye with a well demarcated white edematous retina extending from the optic disc superiorly to the macula, but sparing the foveola **(Figure 1)**. The rest of the retina appeared normal. Intraocular pressure was normal (14 mm Hg OU) in both eyes. Optical coherence tomography (OCT Cirrus spectral domain-Carl Zeiss) revealed firstly, an increase in thickness and hyper-reflectivity of the inner retinal layers in the affected area, and secondly, shadowing with decreased reflectivity of photoreceptor and retinal pigment epithelial layers, consistent with the incidence of intracellular oedema **(Figure 1)**. Left eye central macular thickness measured 377 µm in ocular coherence tomography. Fundus photographic documentation was also performed. The above findings established the clinical diagnosis as isolated cilioretinal artery occusion in the left eye.

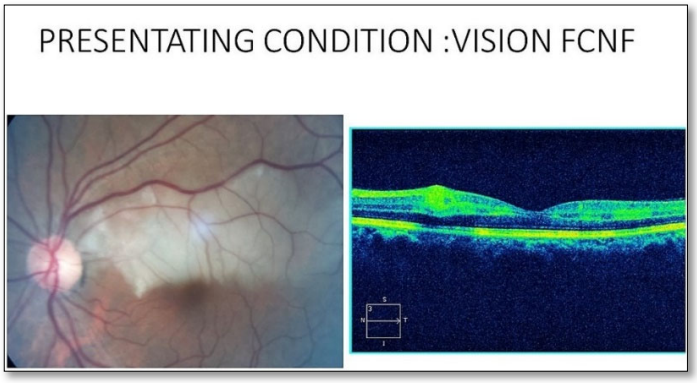

Figure 1. Presenting image and OCT.

The patient was treated with oral carbonic anhydrase inhibitors (250 mg tablets of acetazolamide, 1x2) and intravenous hyperosmolar agent (350 ml mannitol). In addition, intravitreal injections (Bevacizumab + intra vitreal tiamcelone acetate) were planned on the same day in the left eye: Bevacizumab 1.25 and 2 mg triamcinolone acetate were administered in vitreous cavity with aseptic precautions, following which the patient was examined once again.

At the post-treatment follow-up one week later, the best corrected distance visual acuity in the left eye had improved to 6/9, while the right eye vision remained unaltered with a reading of 6/9. Posterior segment examination demonstrated that the previously noted well demarcated whitish areas of retinal ischemia had turned into ill-defined pinkish regions **(Figure 2)**. Fundus photography and ocular coherence tomography were repeated and ocular coherence tomography retinal thickness recorded as 242 µm **(Figure 2)**.

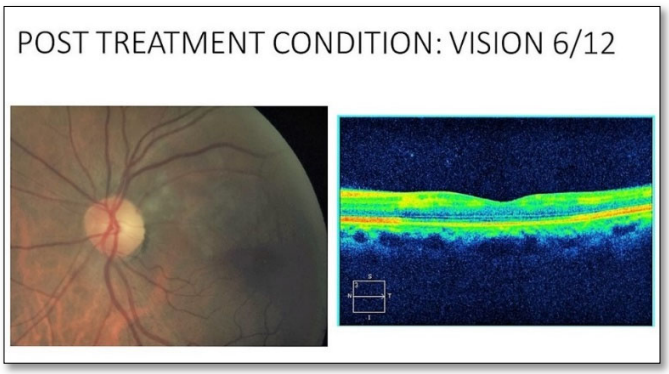

Figure 2. Post treatment image and OCT.

DISCUSSION

In comparison to isolated cilioretinal artery occlusion, the visual prognosis of retinal artery occlusions is poor, and its current acute management has limited and unproven benefits for the improvement of vision [4,5]. Several studies have reported a variety of treatment modalities such as ocular massage; treatment with carbogen (95% oxygen and 5% carbon dioxide), topical Timolol maleate and acetazolamide; and anterior chamber paracentesis, but these modes of treatment have not been established as safe and efficacious options for this visually disabling condition [6,7].

To the best of our knowledge, no studies have reported a significant improvement in visual acuity following intravitreal injections of anti-Vaso Endothelial Growth Factor

and triamcilione. However, in the present case study, the patient responded well to intravitreal injections of Bevacizumab + intra vitreal tiamcelone acetate, and showed a markedly significant improvement in visual acuity within 1 week of therapy. The observed improvement in vision could also be attributed to the early initiation of treatment, young age of the patient and absence of precipitating factors.

CONCLUSION

Intravitreal administration of Bevacizumab + intra vitreal tiamcelone acetate (through injections) appears to be a promising treatment modality for retinal artery occlusions. Prompt initiation of treatment can contribute considerably to restoration of normal vision. However, the topic needs to be researched on a large scale with a long-term follow-up and analysis to validate the findings of this study.

REFERENCES

1. Regillo D, Chang TS, Johnson MW (2007) Basic and Clinical Science Course: Retina and Vitreous. American Academy of Ophthalmology, San Francisco, USA.
2. Justice J Jr, Lehmann, RP (1976) Cilioretinal arteries: A study based on review of stereo fundus photographs and fluorescein angiographic findings. Arch Ophthalmol 94: 1355-1358.
3. Brown GC, Moffat K, Cruess AF, Magargal LE, Goldberg RE (1983) Cilio retinal artery obstruction. Retina 3: 181-187.
4. Schmidt D, Schumacher M, Wakhloo AK (1992) Microcatheter urokinase infusion in central retinal artery occlusion. Am J Ophthalmol 113: 429-434.
5. Duker JS, Sivalingam A, Brown GC, Reber R (1991) A prospective study of acute central retinal artery obstruction: The incidence of secondary ocular neovascularization. Arch Ophthalmol 109: 339-342.
6. Rumelt S, Dorenboim Y, Rehany U (1999) Aggressive systematic treatment for central retinal artery occlusion. Am J Ophthalmol 128: 733-738.
7. Beatty S, Au Eong KG (2000) Acute occlusion of the retinal arteries: current concepts and recent advances in diagnosis and management. J Accid Emerg Med 17: 324-329.