

Case Study: Covid-19 Patient

Vijayaraddi Vandali* and Kamel Abdi

*Department of Nursing, Komar University of Sciences and Technology, Sulemania, Kurdistan, Iraq.

Received June 20, 2020; Revised July 23, 2020; Accepted July 26, 2020

ABSTRACT

Mr. Y (name changed), 56 years old married man and an IT professional came to the hospital with s/s of fever, cough, breathing difficulty and weakness and then tested for covid-19, it was positive. After Mr. Y developed severe Signs/Symptoms such as breathing difficulty, high fever and myalgia then transferred to Intensive Care Unit, where patient treated with oxygen, PCT, HCQ, Azithromycin etc. and some antivirals for 8-10 days, Mr. X gradually started to breathe.

At the time when admission to the hospital Mr. Y was suffering with Fever (39 degree Celsius/102-degree Fahrenheit), dry Cough, mild breathing difficulty, weakness etc. and soon his sample sent for COVID-19 test and received report as positive and then Mr. Y symptoms further increased. Treatment started with IV fluids, Paracetamol, azithromycin, dexamethasone and ventilator support, with this treatment Mr. Y gradually recovered and again sent for the test after that received as negative. Mr. Y discharged with special instructions to be followed at home. Moreover, the treatment and immunity of the particular patient matters in cure/recover from COVID-19.

Keywords: COVID-19, Case study, WHO, Treatment, Cure and immunity

INTRODUCTION

Introduction of COVID-19

Coronaviruses belongs to a big family of viruses. Some of them cause the common cold in people. Others infect animals, including bats, camels, and cattle.

Novel corona virus was first detected in Wuhan, China, in late 2019 and has become a deadly global pandemic, its highly contagious disease and can able to spread very rapidly [1-6] (Figure 1).

Introduction to case

Mr. Y (name changed), 56 years old married man and an IT professional came to the hospital with s/s of fever, cough, breathing difficulty and weakness and then tested for COVID-19, which was positive.

After Mr. Y developed severe S/S he got transferred to ICU, where patient was treated with oxygen, PCT, HCQ and some antivirals for 8-10 days, Mr.X started to breathe himself [2].

Developed following S/S (Signs and Symptoms)

- Fever (39 degree celsius),
- Cough
- Myalgia,
- Sore throat

- Breathing difficulty (mild) and
- Anosmia is suspected to be covid-19.

Current Problem

- No household or work history of known exposure to COVID-19. Developed fever (39 degree C) with chills & persistent dry cough. Self-managed with Paracetamol for 3 days.
- On 4th day he developed acute SOB and felt unwell.
- He contacted emergency team who sent an ambulance.
- Seen in casualty and noted he was in type-2 respiratory failure.
- Intubated and taken to ICU [3].

Test

- Blood: LFT, FBC, CRP, U&E, ABG,

Corresponding author: Vijayaraddi Vandali, Faculty, Department of Nursing, Komar University of Sciences and Technology, Sulemania, Kurdistan, Iraq, E-mail: vijayvandali84@gmail.com

Citation: Vandali V & Abdi K. (2021) Case Study: Covid-19 Patient. J Infect Dis Res, 4(2): 220-221.

Copyright: ©2021 Vandali V & Abdi K. This is an open-access article distributed under the terms of the Creative Commons Attribution License, which permits unrestricted use, distribution, and reproduction in any medium, provided the original author and source are credited.

- Throat & mouth swab,
- CXR, blood cultures done.
- CXR showed COVID-19 features.
- Throat swabs were positive.
- Mr. Y Inflammatory markers raised.
- Mr. Y was in respiratory acidosis from gases.
- Mr. Y was intubated and admitted ITU and was on ventilator for 2 weeks.
- Then Mr. Y extubated [4].

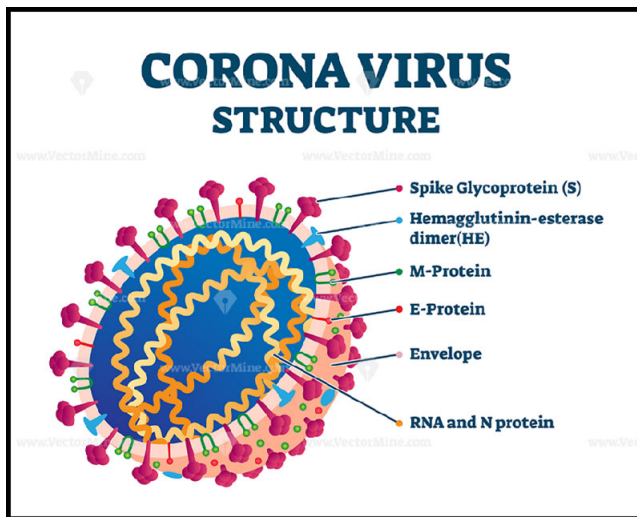


Figure 1. Structure of corona virus.

Source: Google image

On 11th day he was showing signs of voluntary breathing hence Mr. Y was weaned off from ventilator.

Mr. Y treated with:

- Tazocin,
- Paracetamol,
- Azithromycin
- Lansoprazole,
- NG feeds,
- IV fluids prn,
- Oxygen support
- Ferrous supplement.

(Note: There is no accurate treatment yet for the COVID-19 as per WHO, at present different countries/states/provinces using different protocol to treat and moreover treatment depend upon patient's age/gender/immunity/health status etc.)

Mr. Y was extubated on 11th day since admission. He was transferred to normal ward and on supplemental oxygen. Was doing well in the ward and discharged after getting NEGATIVE COVID-19 test [5].

CONCLUSION

In this case study it was found that the cure/recovery from COVID-19 is possible with quality and symptomatic treatment on time with fullest extent. As per World Health Organization, there is no particular drug to cure the COVID-19 till now but different countries are using many different protocols to treat/recover from COVID-19. Such as few countries using HCQ, Paracetamol and Azithromycin with IV FLUIDS and OXYGEN/Ventilator support, plasma therapy also using to get cure/recover from the pandemic and in some countries, steroids are being used for critically ill patients such as Dexamethasone and this drug has proven to be very effective and reduced significant death rates in critically ill COVID-19 patients. More over many countries cured/recovery rate from COVID-19 is better such as in India, Indonesia, China etc. good thing that lakhs of positive patients of COVID-19 cured/recovered across the globe and meanwhile keep rising in the total number of COVID-19 positive cases in the world, such as more than 10 million of cases reported [2].

ACKNOWLEDGEMENT

I would like to thank my parents, my wife, my children's, my brothers and my uncle and aunt who has been constant motivator for me in research.

REFERENCES

1. World Health Organization (2020) Coronavirus.
2. Alarm Grows as Markets Tumble and Death Toll Rises (2020) The New York Times.
3. Hopkins Medicine (2020) Available online at: <https://www.hopkinsmedicine.org/health/conditions-and-diseases/coronavirus/coronavirus-social-distancing-and-self-quarantine>
4. Sawicki SG, Sawicki DL (2005) Coronavirus transcription: a perspective. *Curr Top Microbiol Immunol*: 31-55.
5. Kuljić-Kapulica N (2005) SARS corona virus--a new dilemma. *Med Pregl* 58: 43-46.
6. Vandali V, Desai BS (2020) Corona Virus Outbreak: A Mini Review. *J Nurses Voice Impact* 2: 1-3.