International Journal of Surgery and Invasive Procedures
IJSIP, 2(3): 76-84
www.scitcentral.com

ISSN: 2640-0820

Case Report: Open Access

Camouflage Surgery to Correct Craniofacial Defects with Custom Implants: Case Series

Diego Barreto, Carolina Gamboa, Álvaro Rodríguez and Juan Morales*

[*]El Bosque University, Bogota, Colombia.

Received May 09, 2019; Accepted May 24, 2019; Published September 14, 2019

ABSTRACT

Objective: The purpose of this paper is to report the use of custom implants as an esthetic correction method for craniofacial defects.

Materials and methods: The case series introduced in this paper corresponds to three patients, which have craniofacial congenital malformations. The defects were corrected using PoreStar (Anatomics Pvt. Ltd. Wellington street St. Kilda, Australia) custom implants.

Results: The craniofacial implants adapted and integrated themselves optimally to the patients. None of them exhibited failures during the research study and follow-up period, showing a 100% survival rate. The esthetic results and acceptance by the patient were very satisfactory.

Conclusion: The custom implants accomplish optimal esthetic results regarding the handling of craniofacial defects, facilitating the unique and specific reconstruction of human characteristics.

Keywords: Implants, Craniofacial defects, Esthetics

INTRODUCTION

The complex esthetic and functional consequences that craniofacial defects generate require planning reconstruction and an ideal selection of materials for their restoration [1]. Congenital malformations, defects due to tumor ablation and sequels of trauma are the main causes of these defects. The complex anatomy of the malar region turns this facial region into one of the most vulnerable. Since after altering its natural position, esthetic deficiencies are produce in its projection and the shape and function of the eyeball is compromised [2]. Likewise, it produces in the patient a severe emotional burden that justifies the integral rehabilitation of these defects [3].

The autologous grafts for the reconstruction of craniofacial defects are considered as the first option for reconstruction, however, the need for a donor site and the additional surgical interventions, limit their use [4]. The extension of the defect, the anatomical characteristics of the zone that will be operated and the presence of vital structures near the affected area, highlight the importance of using custom prostheses that can work with these requirements, restoring the esthetic and function in accordance with the requirements of each patient [4,5]. Alloplastic implants are an efficient option for the reconstruction of craniofacial defects, since their high predictability and surgical stability allows decreasing the operation times and improves the defect's reconstruction capacity [5].

The craniofacial implants are medical devices manufactured to replace/reconstruct an absent biological structure, a damaged structure or improve an existing structure [6]. These materials must be compatible, easy to manipulate, resistant to infection and allow an easy extraction-insertion. Some of the materials used for these implants are high-density-porous-polyethylene (HDPP), expanded-poli-tetrafluoroethylene (ePTFE), polyether-ether-ketone (PEEK), methyl-methacrylate, silicone, bio-ceramic/bio-glass, etc. [6,7].

The purpose of this paper is to report the use of PoreStar (Anatomics Pvt. Ltd. Wellington street St. Kilda, Australia) custom implants as an esthetic correction method for cranio-

Corresponding author: Juan Manuel Morales Fernández, Resident of Oral and Maxillofacial Surgery, El Bosque University, Bogotá, Colombia, E-mail: juanman1210@hotmail.com

Citation: Barreto D, Gamboa C, Rodríguez A & Morales J. (2019) Camouflage Surgery to Correct Craniofacial Defects with Custom Implants: Case Series. Int J Surg Invasive Procedures, 2(3): 76-84.

Copyright: ©2019 Barreto D, Gamboa C, Rodríguez A & Morales J. This is an open-access article distributed under the terms of the Creative Commons Attribution License, which permits unrestricted use, distribution, and reproduction in any medium, provided the original author and source are credited.

facial defects.

MATERIALS AND METHODS

The case series corresponds to patients with craniofacial defects who were subjected to surgical interventions to place custom implants (personalized) made with alloplastic materials. The patients had facial congenital malformations and an acceptable health status. Eight high-density porous polyethylene (HDPP) PoreStar (Anatomics Pvt. Ltd. Wellington street St. Kilda, Australia) implants were placed on three patients.

The patients included in the research study exhibited congenital craniofacial defects and an ASA I or ASA II classification per the American society of anesthesiologists 2014: physical status classification system. The patients excluded from the research study were patients that exhibited craniofacial defects associated to trauma consequences or tumor ablation. Besides this, they also had an ASA III or higher classification per the American society of anesthesiologists 2014: physical status classification system.

This research study was conducted in accordance with the Declaration of Helsinki and was approved by the researchers from the ethics committee from the corresponding service. Patient release form was obtained from all the patients included in this research study.

The initial evaluation was conducted using a CT scan from the face with high-resolution specifications and minimal distance cuts between corresponding images at 0.5 mm of spacing, under the strict imaging calibration from the PoreStar (Anatomics Pvt. Ltd. Wellington street St. Kilda, Australia) implants protocol. The craniofacial three-dimensional reconstruction was obtained through stereolithographic models and the alloplastic implants were custom designed in the models. The virtual assistance conducted jointly with biomedical engineers from the parent company allowed to fully comply with the specific technical requirements of each patient. The three patients were treated at the Simon Bolivar Hospital (Bogota, Colombia).

The surgical bio-model with the custom implants in place was sterilized. Before placing the implants, they were submersed in a dilution of 500 ml of SSN 0.9%/2 g cefazolin. Subsequent conventional approaches were conducted and the implants were placed. The fixation of the implant had a minimum of two screws (medial and lateral). The implant considered successful when the 12 months post-implant period ended without producing associated adverse events.

CASE SERIES

Patient one

Male patient, thirty years old, diagnosed with Treacher Collins syndrome. Exhibits marked deficiency on the projection frontal, temporal and bilateral malar **(Figures 1A-1C)**. Additionally, the patient exhibits class II malocclusion with severe micrognathism and sequels of facial esthetic surgery done to correct bilateral microtia. For the correction of the craniofacial defects the following were conducted: osteogenic mandibular distraction, functional septum-rhinoplasty and camouflage through custom implants in the frontal-temporal and bilateral malar region. The simultaneous facial-cranial approach as camouflage for congenital defects is poorly referenced in the literature.

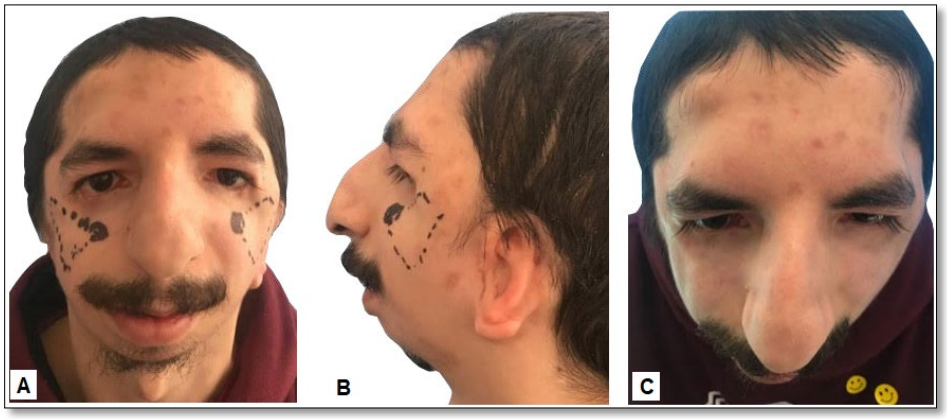

Figure 1. Patient with Treacher Collins syndrome. **A, B)** Demarcation of the bilateral malar defect. **C)** Notice the bilateral frontal-temporal defect.

The planning begins by three-dimensionally reconstructing the defects that appear in the CT, choosing the ideal position and contour of the implants **(Figure 2)**. The stereolithographic model shows the custom implants in the frontal-temporal region and bilateral malar in place **(Figure 3)**. Subsequently a vestibular approach was made with sub periosteal exposition of the malar region. The implants were adjusted and fixed in the ideal position **(Figures 4A-4C)**. Follow-up of 2 years 3 months without complications **(Figures 5A-5C)**. The esthetic improvement in the frontal, temporal and malar projection and contour optimally camouflages the defects.

Additionally, the esthetic correction through osteogenic mandibular distraction and functional septum-rhinoplasty **(Figures 6A and 6B)** in the patient facilitated the acceptance of the defects, significantly improving his quality of life.

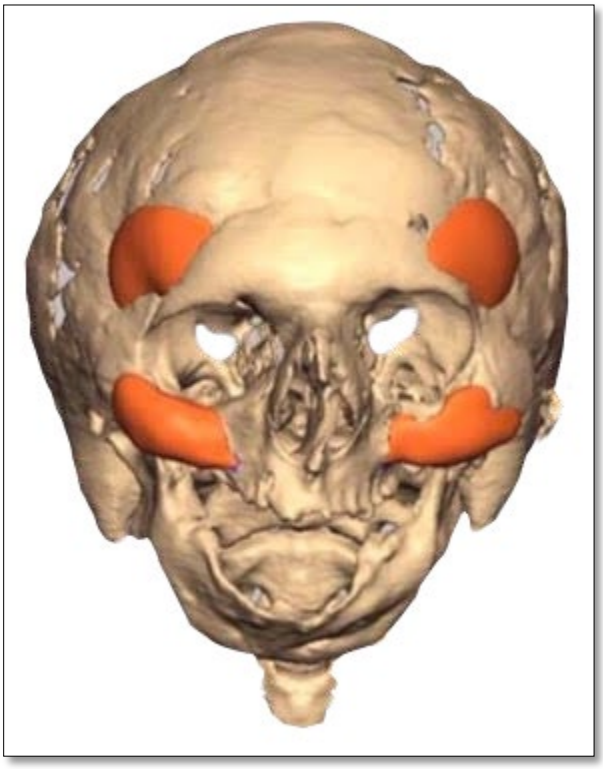

Figure 2. Virtual 3D planning. Ideal position and contour of the implant.

Figure 3. Stereolithographic model with implants adjusted in place.

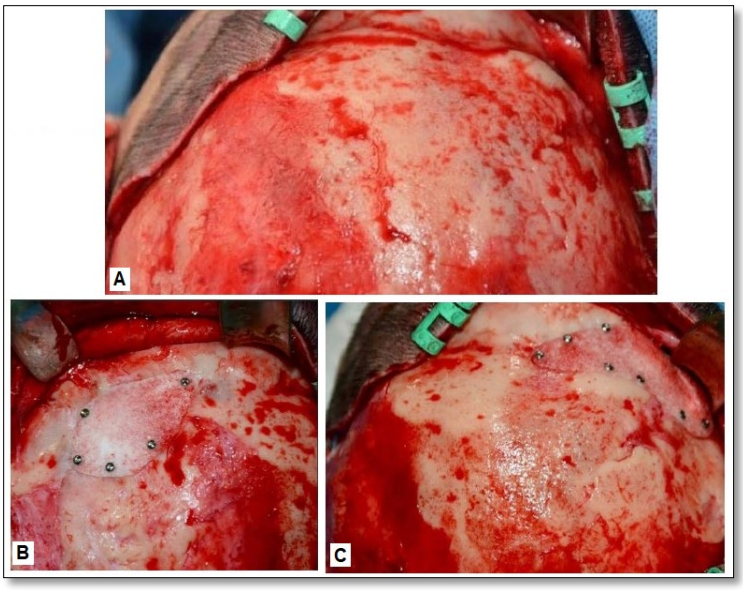

Figure 4. Conventional coronal approach. **A)** Subperiosteal exposure. **B)** Frontal-temporal left implant in place. **C)** Frontal-temporal right implant in place.

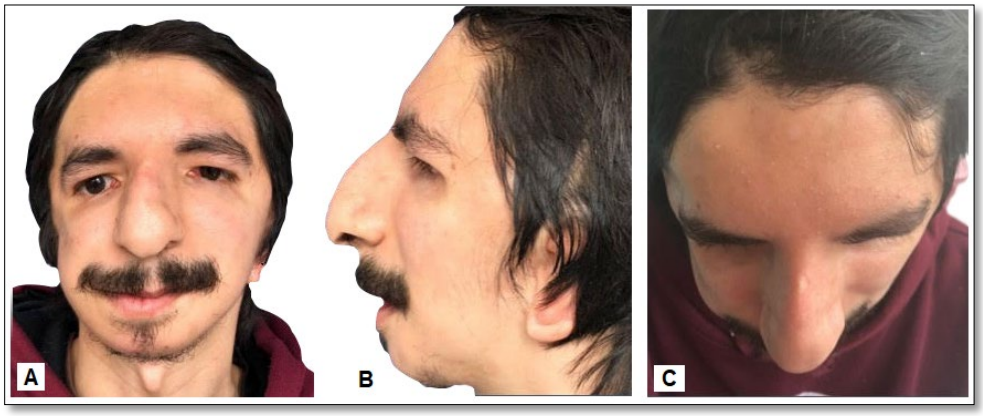

Figure 5. Postoperative period of 1 year after mandibular osteogenic distraction and bilateral frontal-temporal and malar implants. **A, B)** Correction of malar projection and mandibular retrognathism **C)** Frontal-temporal camouflage.

Figure 6. A, B) Postoperative period of 15 days after functional septum-rhinoplasty. The nasal correction allows a proper nasal profiling. Notice the discrepancy of the residual nasal tissue and facial proportions.

Patient two

Male patient, nineteen years old, who exhibits craniofacial defects consistent with microtia and left malar hypoplasia. To correct the craniofacial defects, the following were conducted: surgical placing of prosthesis for the auricular left pinna through the epiplating system (Medicon. Tuttlingen, Germany Company) **(Figures 7A and 7B)** and camouflage through a custom implant in the left malar region.

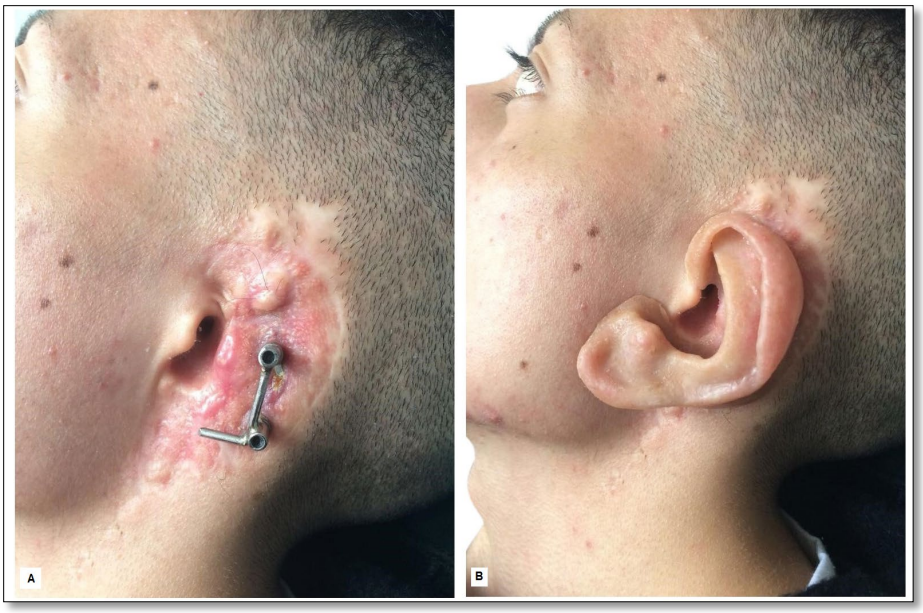

Figure 7. Epiplating system **A)** Transcutaneous bar and pins. **B)** Anchored auricular protheses.

The stereolithographic model shows the custom implant in the left malar region **(Figure 8A)**. A conventional approach was implemented in the back of the vestibule with a sub periosteal exposure of the left malar region, the implant was adjusted and fixed in the ideal position **(Figure 8B)**. Follow-up of 1 year and 8 months without complications **(Figures 9A and 9B)**. The esthetic improvement in the malar projection and contour camouflages the defect optimally. Additionally, the esthetic prosthesis complements the integral handling of the patient.

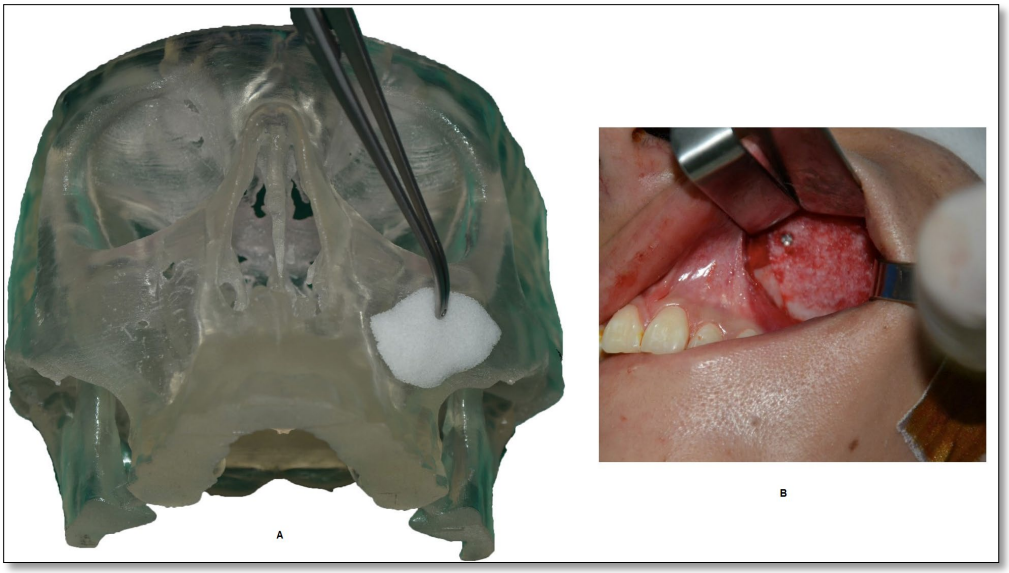

Figure 8. A) Stereolithographic model with implant adjusted in place. **B)** Intra-operative view

Figure 9. Control 1 year after the surgery. **A)** Left hemifacial compensation. **B)** Auricular prosthesis naturalness.

Patient three

Female patient, thirty-three years old, who exhibits surgical sequels due to the congenital alteration of cleft palate and lip. Exhibits marked deficiency in the malar projection and contour bilaterally **(Figures 10A and 10B)**. Additionally, the patient exhibits strabismus, class III malocclusion with maxilla hypoplasia, speech disorder (severe hypernasality) and proportion and volume nasal defect. The craniofacial defects were corrected through bilateral sagittal split osteotomy and chin surgery. The camouflage option by means of the placing of paranasal and malar custom implants was determined through a consensus with the patient and the surgical team to avoid further disruptions in speech. Besides, the poor bone quality and the remaining bone defects hampered the proper completion of the maxilla osteotomy procedure.

Figure 10. Unilateral left cleft lip and palate consequences. **A)** Evident nasal, lip and mandibular underbite defects. **B)** Poor malar projection and dentofacial class III anomaly with severe maxilla hypoplasia.

The stereolithographic model shows the custom implants in the bilateral paranasal-malar region in place **(Figure 11A)**. The defect was corrected with a conventional approach in the back of the vestibule with a sub periosteal exposure of the malar and paranasal region with implants in place **(Figure 11B)**. Follow-up of 2 years without complications **(Figures 12A-12C)**. The esthetic improvement in the paranasal-malar projection and contour optimally camouflages the defects. Additionally, the esthetic

correction of the patient was successfully accomplished without compromising function.

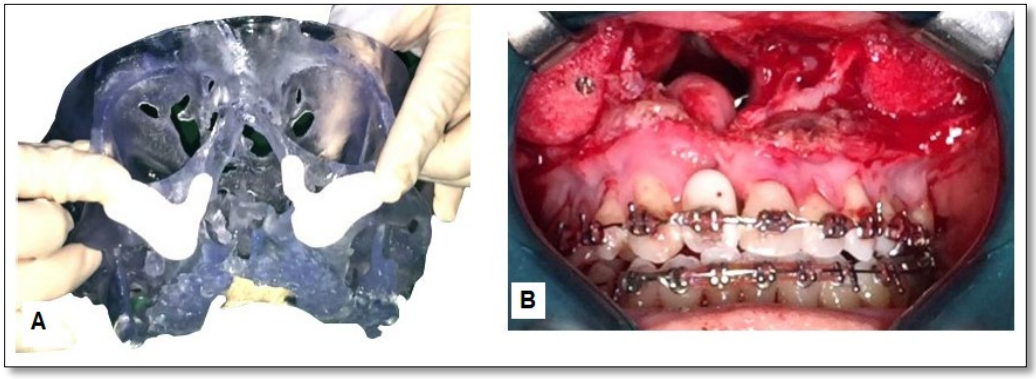

Figure 11. Bilateral malar implant. **A)** Stereolithographic model with implants adjusted in place. **B)** Intra-operative view.

Figure 12. Control 2 years after the surgery. **A)** Concomitant facial defects in correction process. **B, C)** Bilateral malar camouflage related to mandibular osteotomy.

RESULTS

The adaptation of the craniofacial implants significantly improved the esthetic of the operated patients. The eight adjusted and adapted implants placed to correct the craniofacial defects showed a success rate of one year over with an implant placing of 100%. The camouflage obtained in the 3 patients was physically and mentally tolerated in a satisfactory manner.

DISCUSSION

The reconstruction of the craniofacial defects represents a great challenge for the physician [8], who must remember and implement the general facial analysis, and in specific cases, local specific layouts (for example, the malar zone) [9]. The choice of the ideal reconstruction material may be confusing, since the range of available materials is extensive (poli-tetrafluoroethylene, methyl-methacrylate, HDPP, PEEK, silicone, etc.) [10]. The senior author and other clinicians prefer custom alloplastic implants made of porous polyethylene [11,12] silicone [13] or PEEK based on patient specific implants [14]. However, despite the morbidity of the donor site and rate of resorption, other authors prefer fatty autologous grafts [15,16] or hyaluronic acid fillers that avoid a donor site and it is analogous to fat transfer techniques for deeper volumetric adjustment [17].

The HDPP implants (PoreStar, Anatomics Pvt. Ltd. Wellington street St. Kilda, Australia – Medpor, porex surgical Inc., College Park, GA) have the advantage of biological integration to the recipient site. The collagen deposits form a highly stable compound that will resist infectious processes, undesired exposures to the material or malformation due to contractile forces [12]. The preference of different authors [3,9,12,18] because of their mechanical and biological capacity justifies their use. On the other hand, silicone implants (Silastic implant Tech, Ventura, CA), have the advantage of biological encapsulation in the recipient site, facilitating their adjustment and possibility of easy removal when needed, dissenting on the use of HDPP implants [13]. Currently, 3D planning facilitates the planning and execution of reconstructions in a custom manner, allowing obtaining more predictable results with minimal morbidity [19,20].

Atherton et al. in 2014 [21] describe the usefulness of malar and paranasal implants related to reconstructions of

midfacial and malar hypoplasia defects in patients with history of cleft lip and cleft palate, similar to the case introduced in this paper, where the osteogenic distraction and orthognathic surgery were not viable treatment options. Likewise, they describe their use in situations, where despite acceptable esthetic results, the craniofacial contours are compromised.

The handling of craniofacial deformities through the combination of camouflage techniques and esthetic-functional procedures allows the appropriate correction and integral rehabilitation of the different defects found in these patients. Barreto et al. in 2019 [3] conducted the correction of auricular defects through the auricular epiplating prothesis system (Medicon. Tuttlingen, Germany Company). Likewise, the authors conducted osteogenic distraction surgeries and functional septum-rhinoplasty surgeries using PoreStar implants (Anatomics Pvt. Ltd. Wellington street St. Kilda, Australia) as a protocol for integral craniofacial rehabilitation with optimal esthetic results.

In accordance with Robiony et al. in 1998 [9], who simultaneously conducted orthognathic surgeries and implant placing in the malar region for the correction of craniofacial defects, in our cases we opted for camouflage interventions that improved the esthetic, without compromising the function of the patient. In a similar manner as the one exposed in case three, Robiony et al. [9], specify cases where large maxilla advances or movements with poor predictability can be replaced by esthetic camouflages with custom implants.

The complications associated to facial implants are around 31.5%, mainly related to esthetic (dissatisfaction of 10.1% due to asymmetry or implant migration) and infection of the operated place (7.2%) [11]. Other minor complications that may emerge are swelling, ecchymosis, implant malposition, bone resorption, external implant palpation and asymmetry [22]. There were not complications in our cases. The intraoral conventional surgical technique used by the author and in accordance with Atherton et al. 2014 [21], only exhibits a 0.5% of complications related to infection. Although the periorbital approaches provide a direct vision, they also increase the probability of complications (ectropion, epiphora, infraorbital neurapraxia, etc.) [23].

The greatest questions the surgeon has are, which implant to use and where to place it. The appropriate implant should be the one with the correct specifications [13]. The esthetic and functional rehabilitation of the craniofacial defects represents a great challenge for the surgeon. The autografts and allografts used for many years implied an increase in the morbidity of the patients and the completion of an optimal functional and esthetic rehabilitation was very unpredictable. The rehabilitation through alloplastic substitutes accomplishes an ideal esthetic camouflage difficult to obtain through other methods [24]. The use of custom implants not only allows camouflaging the esthetic defect, but it also facilitates the acceptance due to psychogenic self-perception, which generates an improvement in the quality of life of the patient and in their immediate social surroundings [21].

CONCLUSION

The handling of patients with different craniofacial pathologies (Treacher Collins syndrome, cleft lip and palate, etc.) who exhibit extreme anatomical conditions can be treated with optimal esthetic results and minimal morbidity. Custom HDPP implants accomplish optimal esthetic results in the handling of craniofacial defects, facilitating the unique and specific reconstruction of human characteristics.

ACKNOWLEDGEMENT

Carlos E Buitrago, DDS, who provided excellent feedbacks to the article.

REFERENCES

1. Osunde OD, Adebola RA, Veror N, Amole IO, Akhiwu BI, et al. (2013) Augmentation of craniofacial defects using alloplastic material. West Indian Med J 62: 654-657.
2. Singaram M, Udhayakumar RK (2016) Prevalence, pattern, etiology and management of maxillofacial trauma in a developing country: A retrospective study. J Korean Assoc Oral Maxillofac Surg 42: 174-181.
3. Barreto D, Rangel R, Morales J, Gutierrez P (2019) Epiplating in auricular defects as a facial reconstruction method: Case series. J Oral Maxillofac Surg 77: 183-e1-183-e8.
4. Parthasarathy J (2014) 3D modeling, custom implants and its future perspectives in craniofacial surgery. Ann Maxillofac Surg 4: 9-18.
5. Jammalamadaka U, Tappa K (2018) Recent advances in biomaterials for 3D printing and tissue engineering. J Funct Biomater 9: 22.
6. Zegers T, Ter Laak-Poort M, Koper D, Lethaus B, Kessler P (2017) The therapeutic effect of patient-specific implants in cranioplasty. J Craniomaxillofac Surg 45: 82-86.
7. Ayoub A, Al-Fotawei R (2015) Biomaterials in the reconstruction of the oral and maxillofacial region. In: Biomaterials for Oral and Craniomaxillofacial Applications. Karger Publishers 17: 101-114.
8. Aldekhayel S, Aljaaly H, Fouda-Neel O, Shararah AW, Zaid WS, et al. (2014) Evolving trends in the management of orbital floor fractures. J Craniofac Surg 25: 258-261.
9. Robiony M, Costa F, Demitri V, Polit M (1998) Simultaneous malaroplasty with porous polyethylene implants and orthognathic surgery for correction of malar deficiency. J Oral Maxillofac Surg 56: 734-741.

10. Lethaus B, Ter Laak MP, Laeven P, Beerens M, Koper D, et al. (2011) A treatment algorithm for patients with large skull bone defects and first results. J Craniomaxillofac Surg 39: 435-440.

11. Ridwan-Pramana A, Wolff J, Raziei A, Ashton-James CE, Forouzanfar T (2015) Porous polyethylene implants in facial reconstruction: Outcome and complications. J Craniomaxillofac Surg 43: 1330-1334.

12. Yaremchuk MJ (2003) Facial skeletal reconstruction using porous polyethylene implants. Plast Reconstr Surg 111: 1818-1827.

13. Niamtu J (2010) Essentials of cheek and midface implants. J Oral Maxillofac Surg 68: 1420-1429.

14. Honigmann P, Sharma N, Okolo B, Popp U, Msallem B, et al. (2018) Patient-specific surgical implants made of 3D printed PEEK: Material, technology and scope of surgical application. BioMed Res Int.

15. Pasquale P, Gaetano M, Dell'Aversana Orabona Giovanni CL, Gilberto S (2015) Autologous fat grafting in facial volumetric restoration. J Craniofac Surg 26: 756-759.

16. Wu R, Yang X, Jin X, Lu H, Jia Z, et al. (2018) Three-dimensional volumetric analysis of 3 fat-processing techniques for facial fat grafting: A randomized clinical trial. JAMA Facial Plast Surg 20: 222-229.

17. John HE, Price RD (2009) Perspectives in the selection of hyaluronic acid fillers for facial wrinkles and aging skin. Patient Prefer Adherence 3: 225-230.

18. Bose S, Roy M, Bandyopadhyay A (2012) Recent advances in bone tissue engineering scaffolds. Trends Biotechnol 30: 546-554.

19. Oh JH (2018). Recent advances in the reconstruction of cranio-maxillofacial defects using computer-aided design/computer-aided manufacturing. Maxillofac Plast Reconstr Surg 40: 2.

20. Sainsbury DC, George A, Forrest CR, Phillips JH (2017) Bilateral malar reconstruction using patient-specific polyether ether ketone implants in Treacher-Collins syndrome patients with absent zygomas. J Craniofac Surg 28: 515-517.

21. Atherton D, Haers P(2014) Mid-facial augmentation in teenage cleft patients using malar and paranasal Medpor implants. Int J Oral Maxillo fac Surg 43: 824-826.

22. Cuzalina LA, Hlavacek MR (2009) Complications of facial implants. Oral Maxillofac Surg Clin North Am 21: 91-104.

23. Logani SC, Conn H, Logani S, Terino EO (1998) Paralytic ectropion: A complication of malar implant surgery. Ophthalmic Plast Reconstr Surg 14: 89-93.

24. Tevlin R, McArdle A, Atashroo D, Walmsley GG, Senarath-Yapa K, et al. (2014) Biomaterials for craniofacial bone engineering. J Dent Res 93: 1187-1195.