Stem Cell Research & Therapeutics
SCRT, 2(1): 64-73
www.scitcentral.com

ISSN: 2474-4646

Original Research: Open Access

Autologous Fat Grafting and Cell-assisted Lipotransfer to Alleviate Radiotherapy Tissue Damage

Ryan A. Lockhart[2], Cloe S. Hakakian[2], Zoe Birnbaum[2] and Joel A. Aronowitz[1,2,3]

[1]*Cedars-Sinai Medical Center, Los Angeles, CA, USA*

[2]*University Stem Cell Center, Los Angeles, CA, USA*

[3]*USC Keck School of Medicine, Los Angeles, CA, USA*

Received April 29, 2016; Accepted June 17, 2016; Published July 25, 2017

ABSTRACT

Radiation therapy is the standard of care for a variety of oncological conditions because it is highly effective at reducing the risk of local recurrence following resection. However, radiation often causes detrimental effects to the surrounding tissue. One therapeutic outlet being increasingly explored to address post-radiation morbidities is autologous fat grafting (AFG). Beneficial regenerative effects including volume restoration, improved skin quality, pain reduction, and trophic restoration are attributed mainly to the presence of adipose-derived stem and stromal cells present within the adipose tissue. Here we review published data pertaining to the use of autologous fat grafting and cell-assisted lipotransfer for the treatment of radiotherapy-associated tissue damage, or radiodermatitis, as well as the data supporting the role of adipose-derived stem cells.

INTRODUCTION

Radiation therapy is the standard of care for a variety of oncological conditions because it is highly effective at reducing the risk of local recurrence following resection. However, radiation often causes detrimental effects to the surrounding tissue including skin discoloration altered collagen structure, reduced skin elasticity, and dermal thickening as well as a reduction in small vessel density, blistering, draining and/or dryness [1,2]. More serious cases can produce chronic pain, scarring, ulceration and tissue necrosis. The structural alterations and complications of the tissue can make reconstruction of irradiated wounds and tissue difficult.

One therapeutic outlet being increasingly explored to address post-radiation morbidities is autologous fat grafting (AFG). Autologous fat grafting (AFG) is steadily becoming the method of choice for most contour and soft tissue defect repairs. AFG was first reported in 1893 by Gustav Neuber to fill a depressed facial scar [3]. Poor clinical results and interference with xenography and mammograms caused AFG to be overlooked for nearly a century [4,5]. Recently, however, improvements in imaging techniques and clinical outcomes have enabled AFG to become an increasingly popular remedy for a myriad of reconstructive problems requiring soft tissue restoration. The use of adipose tissue to treat soft tissue injuries and restore volume has dramatically increased in the last 20 years. Adipose tissue makes an ideal filler because it is easily acquired and prepared and ultimately provides a permanent, natural filler. The clinical use of AFG to treat irradiated tissue has demonstrated drastic regenerative effects in addition to restored volume including improved skin quality, improved skin tone and improved structural and vascular networks. These beneficial regenerative effects are attributed mainly to the presence of adipose-derived stem and stromal cells present within the adipose tissue [6,7].

The benefit of adipose-derived stem cells in fat grafting has been frequently explored in the last 10 years, beginning with

Corresponding author: Joel A. Aronowitz, Cedars-Sinai Medical Center, Los Angeles, CA, USA, E-mail: dra@aronowitzmd.com

Citation: Lockhart A R, Hakakian S C, Birnbaum Z & Aronowitz A J. (2017) Autologous Fat Grafting and Cell-assisted Lipotransfer to Alleviate Radiotherapy Tissue Damage. Stem Cell Res Th, 2(1): 64-73.

the 2006 report by Matsumoto et al. [8] which demonstrated superior volumetric retention of fat grafting when supplemented with adipose-derived stem cells. They termed this technique cell-assisted lipotransfer (CAL). Adipose-derived stem cells are thought to facilitate graft survival by producing anti-inflammatory, anti-apoptotic, and pro-angiogenic cytokines as well as differentiating into adipose tissue and new vascular structures. **Figure 1** and **Figure 2** gives a brief overview of methodology of cell-assisted lipotransfer and the role of ASCs. Here we review published data pertaining to the use of autologous fat grafting and cell-assisted lipotransfer for the treatment of radiotherapy-associated tissue damage, or radiodermatitis, as well as the data supporting the role of adipose-derived stem cells.

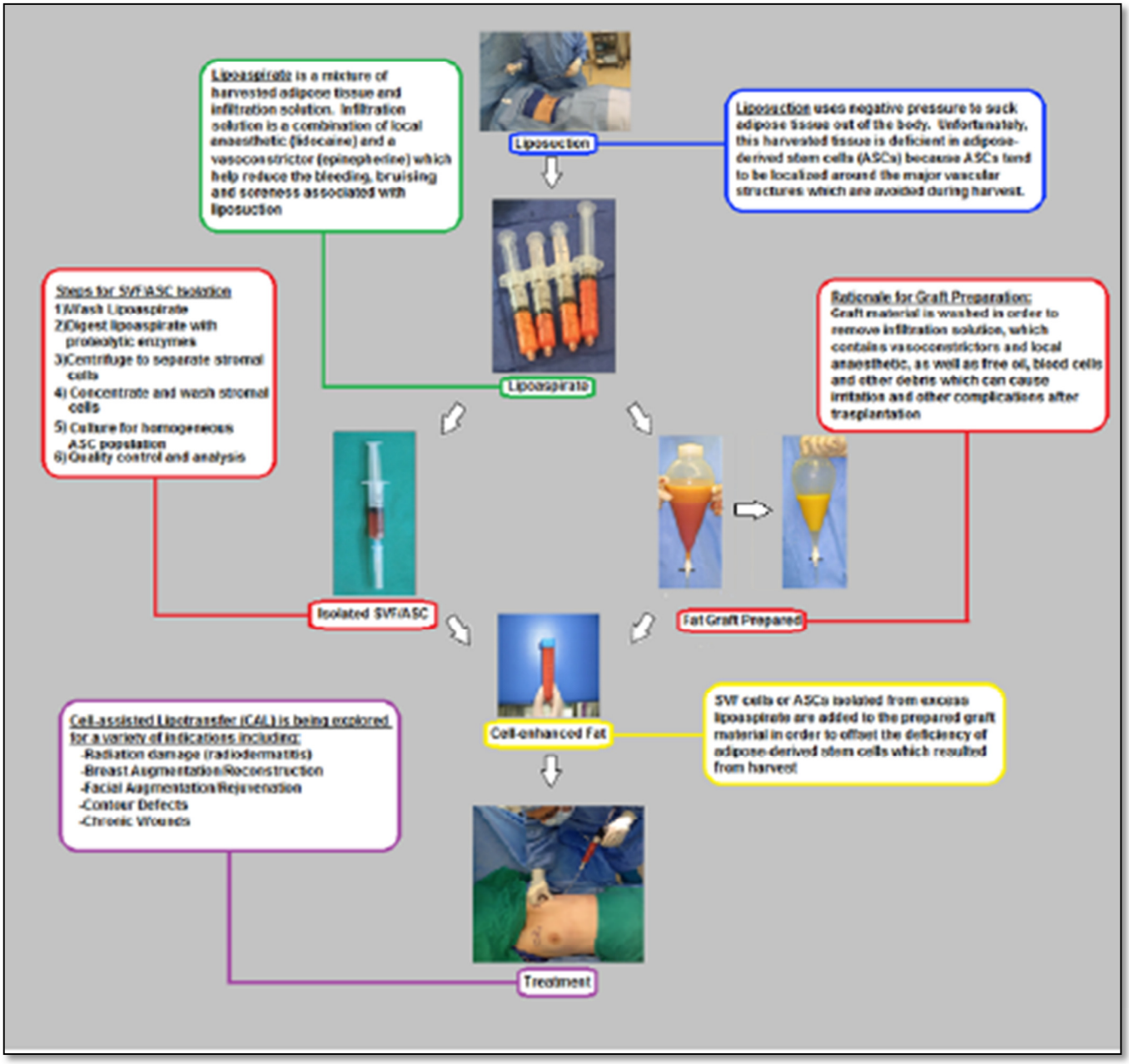

Figure 1. Brief overview of CAL protocol.

Radiotherapy Tissue Damage

Radiodermatitis is an inflammatory condition characterized by erythema, edema, epidermal thickening, pruritus (itchiness) and desquamation (skin peeling). Radiodermatitis is one of the most common side effects observed in patients who have received radiation therapy for sarcoma, breast, anal, vulvar, and head and neck cancers [9,10]. The acute stage of inflammation leads to a more chronic fibrotic

process (chronic radiodermatitis). Chronic radiodermatitis is characterized by a decrease in elasticity, subpar wound healing, and hyperpigmentation (**Figure 3**) and at its most severe state, radionecrosis with ulceration [11-13].

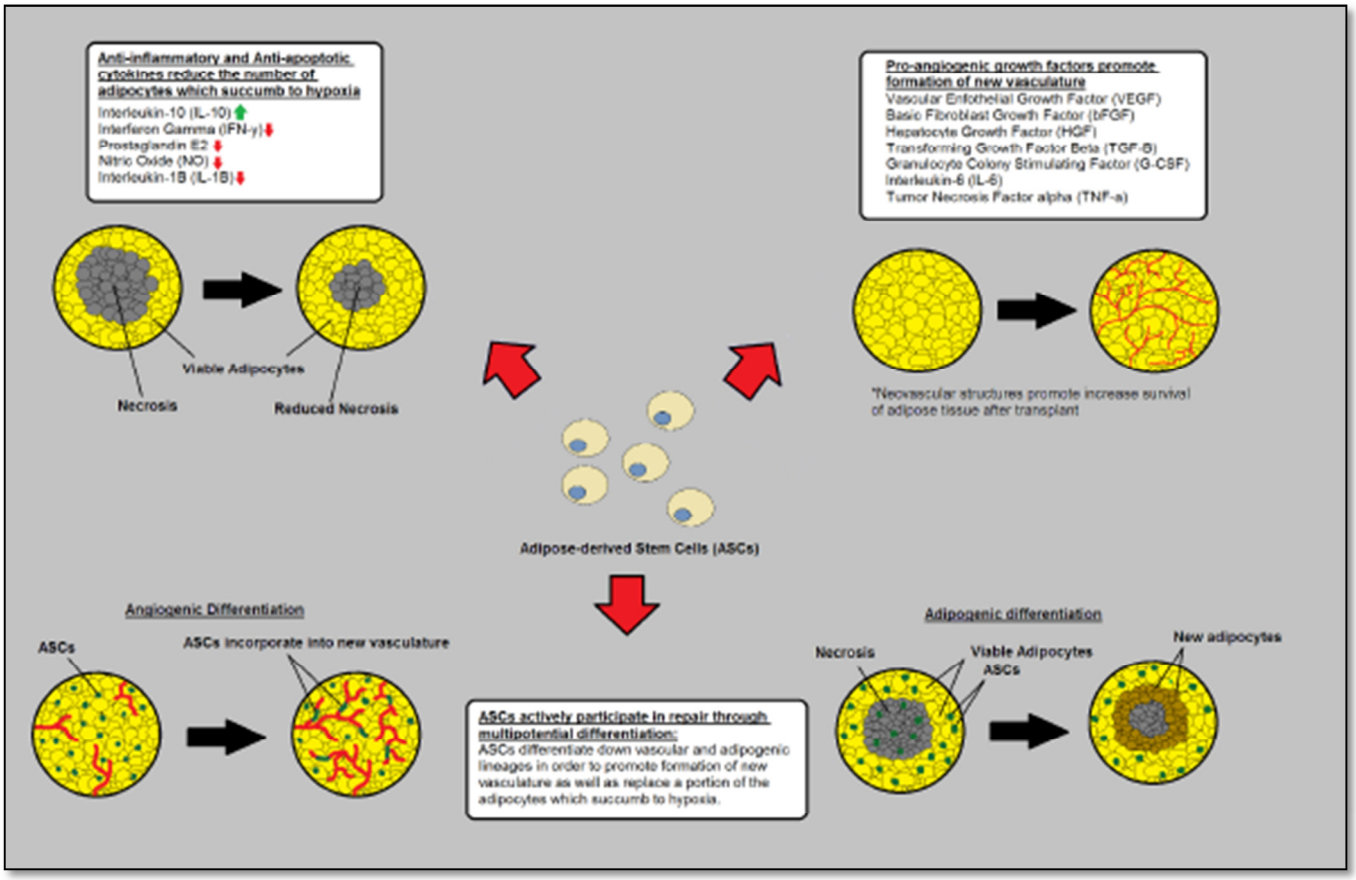

Figure 2. The role of ASCs in Cell-assisted lipotransfer (CAL).

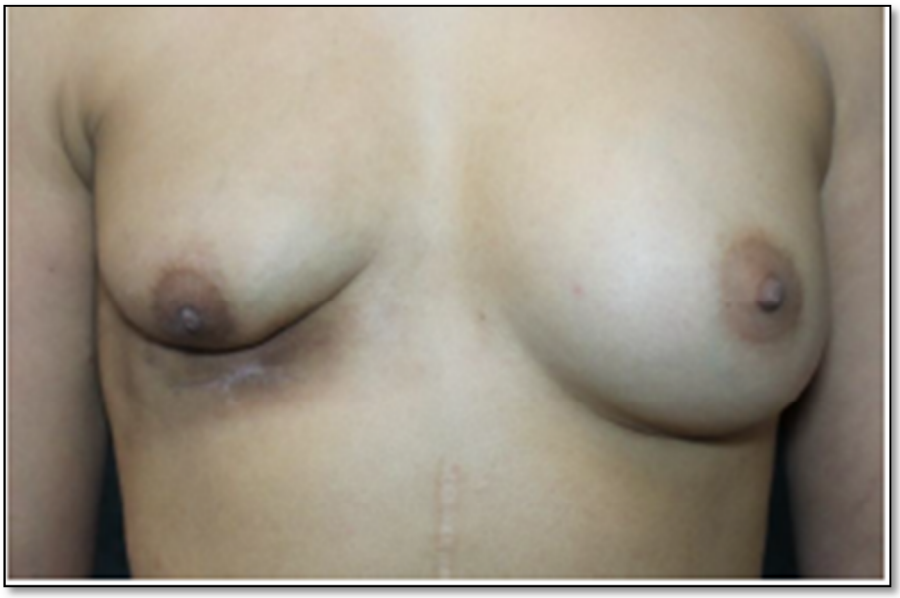

Figure 3. A 40 year old woman presenting with radiation damage of the right breast after receiving a breast conserving lumpectomy with adjunct radiation therapy and chemotherapy 5 years prior. Tissue below the right breast exhibits altered pigmentation typical of radiodermatitis.

Exposure to radiation has also been shown to significantly alter the microvascular structure of exposed tissue. In the acute phase of the response to radiation exposure, the vascular endothelium experiences increased permeability, leading to edema and thrombosis. The hyperpermeability ultimately leads to an increase in capillary density, but the newly formed capillaries are irregular and easily occluded [14]. Damage to the vascular endothelium induces hypoxia and exposure to ionizing radiation upregulates transforming growth factor ß (TGF-ß) production by human dermal fibroblasts [15]. TGF-ß is a cytokine which actively promotes radiation-induced fibrosis [16]. Radiation fibrosis predisposes the treatment area to the development of ulcers, skin breakdown and tissue retraction, which can be painful and limit mobility (**Figure 4).** Additional morbidities which can be observed in the chronic phase of radiodermatitis include loss of hair follicles, nails, skin appendages and sebaceous glands in the treatment area. Radiation induced tissue damage and ischemia eventually lead to tissue necrosis if left untreated and the radiation exposure predisposes exposed cells to neoplastic transformation, as ionizing radiation can cause mutations and chromosomal abnormalities in mitochondrial and nuclear DNA [17]. **Table 1** summarizes the characteristics of acute and chronic radiodermatitis.

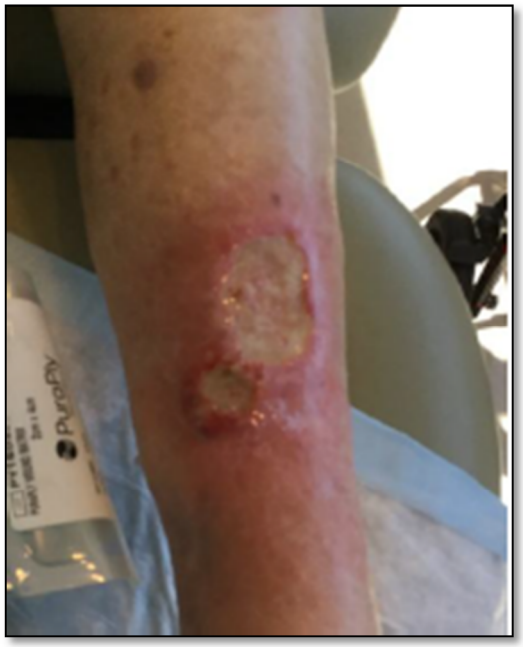

Figure 4. A 90 year old woman who presented with a non-healing radiation ulcer of the left leg as a result of radiotherapy 9 months prior.

The level of tissue damage is commonly assessed using a variety of assessment tools, none of which has emerged as a gold standard. The most widely used grading scales are the National Cancer Institute's Common Terminology Criteria for Adverse Events (CTCAE) for the classification of acute radiodermatitis and the Radiation Therapy Oncology Group (RTOG)/European Organization for Research and Treatment of Cancer (EORTC) scale or the Late Effects Normal Tissue Task Force- Subjective, Objective, Management, and Analytic (LENT-SOMA) scale for the classification of chronic dermatitis. **Table 2** briefly summarizes all 3 grading scales for dermatologic conditions.

Autologous Fat Grafting

The first documented clinical series using autologous fat grafting to treat radiotherapy tissue damage was published by Rigotti et al. in 2007 [18]. This study reported on the clinical outcomes of 20 patients treated with autologous lipoaspirate injections into irradiated breast tissue. All patients had a LENT-SOMA grade 3 (severe) or grade 4 (irreversible functional damage) radiation damage (**Table 2**) as a result of receiving a dose of radiation between 45-55 Gy. Rigotti et al. reported dramatic symptom improvement in 19 out of 20 subjects and overall a significant decrease in the LENT-SOMA score after therapy. Symptomatic improvements observed included complete remission of all cases of skin necrosis, elimination of telangiectasia and pain, as well as a reduction of fibrosis, atrophy and skin retraction. The 19 out of 20 patient who showed a response to the therapy all experiences an improvement of 2 points or better on the LENT-SOMA Scale.

Rigotti et al. examined the potential causes of these regenerative effects at a cellular level. Prior to injecting any lipoaspirate back into patients, compositional and ultrastructural analysis were conducted on the harvested

lipoaspirate. What they found attributed the regenerative effects of the tissue to the stromal cell populations contained within the lipoaspirate, specifically the adipose-derived stem cells. Ultrastructural analysis revealed a relative paucity of fully intact adipocytes and an abundance of intact stromal cells. Histologically they observed progressive regeneration including neovascular formation and improved tissue hydration. They ultimately suggested the presence of adipose-derived stem cells to be responsible for neovascular formation and improved tissue quality.

Table 1. Summary of Acute and Chronic Radiodermatitis [1,2,6,7,9-19].

Classification	Time Frame	Characteristics
Acute Radiodermatitis	≤ 90 days post radiation exposure	Erythema Edema Altered pigmentation Increased skin sensitivity and tightness Dry, flaky or scaly skin (Dry desquamation) Epidermal sloughing, skin blisters, serious draining (Moist desquamation)
Chronic Radiodermatitis	90+ days post radiation exposure	Altered pigmentation Loss of hair follicles, nails, skin appendages, and sebaceous glands Telangiectasia Fibrosis Ulcers Radiation-induced morphea (RIM) Dermal ischemia Radiation necrosis Predisposition to latent development of new neoplasms in treatment area

Sultan et al. [19] examined the effects of autologous fat grafting on chronic radiodermatitis in a murine model in an attempt to clarify the mechanism of regeneration observed by Rigotti et al., with an emphasis on histological and phenotypic changes. A group of 25 mice (wt FVB mice) were divided into 3 groups: control (non irradiated, no injections, n=5), irradiated and then sham grafted (saline injections, n=10) and irradiated and then fat grafted (human fat injections, n=10). Sham and fat grafts occurred 4 weeks after mice received a 45 Gy dose of radiation. They noted that in the fat grafted group, radiation ulcers became smaller and hyperpigmentation decreased, whereas no improvements were noted in control or sham grafted groups. Histologically, they observed that fat grafting attenuated epidermal thickening, stabilized irradiated microvasculature, restored collagen organization and reduced the fibrotic response to radiation.

A 2014 study by Garza et al. [18] further examined the effects of fat grafting on irradiated tissue. A set of 15 Crl:NU-*Foxn1*^{nu} CD-1 immunocompromised mice were divided into 2 groups. 6 were used as non-irradiated controls and 9 received a dose of 30 Gy of external beam radiation to the scalp. 4 weeks post irradiation, all mice received 200ul injections of donor human fat into the scalp. Skin samples

were harvested before fat injections (4 weeks after irradiation) as a baseline and at 2 and 8 weeks post fat injection. They observed that fat grafting alleviated dermal thickening which resulted from radiation exposure, decreased skin collagen content and increased neovascular density in irradiated skin. However, they noted significantly decreased fat retention observed in the irradiated tissue compared to the control group, but the permanently engrafted tissue was histologically identical between groups. They attribute the decreased volumetric retention to the greater ischemic state resulting from irradiation. When the graft material, already deficient in vasculature as a result of harvest [20], is introduced into the ischemic environment of the irradiated tissue, it is exposed to a greater level of hypoxia than it would if placed into healthy tissue, thereby decreasing the overall retention as a greater number of mature adipocytes succumb to hypoxic stress.

Table 2. Summary of Radiodermatitis Grading Scales

Scale name	Assesses	Scale Range	Characteristics
National Cancer Institute's Common Terminology Criteria for Adverse Events (CTCAE) [47]	Acute Radiodermatitis	1 to 5	1-Mild 2-Moderate 3-Severe 4-Life threatening 5-Death (not appropriate for all adverse events)
RTOG/EORTC Scale [48]	Chronic Radiodermatitis	0 to 4	Grade 0- No abnormality Grade 1- Skin: Slight atrophy, change in pigmentation, some hair loss. Subcutaneous tissue: Loss of subcutaneous fat, mild fibrosis, slight induration. Atrophy or dryness of mucous membranes. Grade 2- Skin: Patch atrophy, moderate telangiectasia, and total hair loss Subcutaneous tissue:Moderate fibrosis Grade 3- Skin: Marked atrophy and gross telangiectasia Subcutaneous tissue: Severe induration and loss of subcutaneous fat Grade 4- Ulceration or necrosis
LENT-SOMA Scale [49]	Chronic Radiodermatitis	1 to 4	Grade 1- Occasional pain and minimal hypersensitivity, pruritus, mild fibrosis (epidermal only) Grade 2- Intermittent and tolerable pain, dermal fibrosis (increased intensity and firmness) Grade 3- Persistent and intense pain, severe fibrosis with marked density, retraction and fixation of subcutaneous tissue Grade 4- Refractory and excruciating pain, bone exposure/ulceration or necrosis

Salgarello et al. [21] reported another clinical series involving the treatment of 16 patients who received a prior mastectomy or lumpectomy with adjunct radiation therapy. All patients had radiation damage at grade 1 or 2 on the LENT-SOMA scale. All subjects were treated with autologous fat grafting to the affected region and required 2 or 3 sessions in 3 month increments in order to achieve a LENT-SOMA score of 0 (no damage). Salgarello et al. reports high patient satisfaction in all cases except 1, and additionally that the use of fat grafting can help reduce the risk of implant related complications in patients with a history of radiation if treated with AFG prior to placement of an implant.

Phulpin et al. [22] reported on a series of 11 patients who received AFG to alleviate radiotherapy induced tissue damage in the head and neck area. 10 patients had received 50 Gy of radiation or more and 1 patient received a dose of 30 Gy. AFG was conducted throughout affected areas. Improvements reported included disappearance or decrease in fibrosis, restoration of tissue volume and symmetry as well as other significant aesthetic improvements. In addition to cosmetic improvements, restoration of function was reported in a number of cases as well including easier swallowing, increased mobility of the head and neck region, improvement of breathing, and improved phonation.

A number of case reports describing treatment of 1 or 2 patients for radiotherapy tissue damage have been published as well [23-25]. These studies all report favorable outcomes in terms of tissue quality, aesthetics and patient satisfaction where applicable. An additional benefit which reported for AFG is the reduction of pain in patients experiencing post-mastectomy pain syndrome (PMPS) after undergoing mastectomy with radiation therapy [26,27].

Cell-assisted Lipotransfer

The observations of Garza et al. suggest that further research into methods focused on improving the volumetric retention of autologous fat grafting in irradiated tissue is warranted. A study published in 2016 by Luan et al. [28] examined the outcomes of AFG and CAL in a mouse model. A total of 24 Crl:NU-*Foxn1*^{nu} CD-1 immunocompromised mice were divided into 4 groups: irradiated with AFG (n=6), irradiated with CAL (n=6), non-irradiated with AFG (n=6) and non-irradiated with CAL (n=6). Irradiated mice received a dose of 30 Gy of external beam radiation. 5 weeks after irradiation, all mice received a 200ul fat grafts of donor human fat to the scalp which were supplemented with 10,000 uncultured SVF cells per graft (50,000 SVF cells/mL) if in one of the CAL groups. There was no significant difference in volumetric retention between mice who received CAL with or without irradiation. Both CAL groups showed significantly greater volumetric retention compared to the AFG groups. Following previously reported trends, the irradiated AFG group resulted in significantly reduced volumetric retention compared to all other groups. When comparing CAL and AFG in irradiated tissue, CAL was shown to significantly increase graft integrity and decrease the occurrence of oil cysts and vacuoles. CAL also resulted in a greater reduction in dermal thickness, greater reduction in collagen density, and greater increase in graft vascularity than AFG post engraftment. Overall, they noted that CAL improved volumetric retention and provided greater rescue from radiation-induced skin damage than AFG.

The Regenerative Potential of Adipose-derived Stem Cells

As is suggested by the work of Rigotti et al. [6], Sultan et al. [7], and Garza et al. [18], the regenerative effects of fat grafting are attributed to the adipose-derived stem cell (ASC) population present within adipose tissue. ASCs have been shown to play a supportive role in adipogenesis and angiogenesis as well as a protective role by modulating inflammation and immunity through cytokine production [20,29-33]. Numerous preclinical and clinical studies has demonstrated a wide range of beneficial regenerative effects exerted by adipose-derived stem cells.

Multilineage differentiation potential, specifically adipogenic and angiogenic, is a very important aspect to the regenerative potential of ASCs and is particularly important in terms of graft retention and volume retention. Fat injections have been shown to result in growth of new adipose tissue at the site of injection and paracrine stimulation by injected ASCs has been shown to influence the local stem cell populations to differentiate down adipocyte lineages [34,35]. When conducting fat transfer procedures, a significant portion of the transplanted tissue will succumb to the hypoxic stress and die. The presence of ASCs in the fat allows a portion of this tissue to regenerate new adipose tissue as a result of adipogenic differentiation. Eto et al. proposed a model for the fate of adipose tissue after transplantation [20]. The system describes 3 tissue zones of transplanted fat: the surviving zone, the regenerating zone and the necrotizing zone. The surviving zone receives adequate oxygen via diffusion from the surrounding tissue and allows both the fat and stem cell population to survive. The necrotizing zone is too deep and insufficient oxygen reaches the tissue resulting in death and resorption of both the adipocytes and stem cells. The regenerating zone however receives an intermediate amount of oxygen which results in death of the adipocyte population but survival of the stem cell populations, which are more resistant to hypoxic insult. The surviving stem cell populations in the regenerating zone tend to differentiate down adipocytic lineages and replace a portion of the adipose tissue which was lost [20,30,31].

The angiogenic potential of ASCs is well documented as well. ASCs have been shown to increase tissue perfusion in grafted areas via induction of angiogenesis, through differentiation and paracrine mechanisms, as well as playing a protective role on existing vasculature [29,32,36].

The presence of ASCs in grafted fat tissue promotes a more rapid recovery from the hypoxic state experienced after transplantation. A more rapid recovery of tissue perfusion and vasculature results in a greater survival rate of grafted tissue as well as facilitate more rapid wound healing [37,38].

While it was initially assumed that the regenerative benefits of stem cells was purely due to direct differentiation and replacement of damaged tissues by the transplanted stem cell populations, growing evidence shows that the greatest benefit is afforded by the paracrine effects of molecules

secreted by mesenchymal stem cells. The paracrine effects exerted by ASCs have demonstrated anti-inflammatory, antioxidant, antiapoptotic and immunomodulatory effects which protect neighboring cells against hypoxia, ischemia reperfusion and reactive-oxygen species (ROS) induced damage as well as promote granular tissue formation, reduce fibrosis, promote extracellular matrix remodeling and increase epithelialization [39-41]. The secretory profile of adipose-derived stem cells has been shown to secrete a wide variety of cytokines including IL-8, IGF, bFGF, HGF and VEGF. These cytokines have all been associated with vascular regeneration [42-44]. Given that a significant underlying cause of radiotherapy induced tissue damage is associated with hypoxia, poor vascularity and lymphedema, this secretion profile proves beneficial in the regeneration of the microvascular environment. These immunomodulatory and proangiogenic secretion profiles are shown to be strengthened in a hypoxic environment, like that experienced in irradiated tissue [45,46].

CONCLUSIONS

There is a growing body of evidence in favor of the use of autologous fat grafting or cell-assisted lipotransfer for the treatment of radiotherapy tissue damage. In vitro analysis points to the presence of adipose-derived stem cells contained within the transplanted tissue as being primarily responsible for the regeneration. ASCs have demonstrated multi differentiation capacity as well as a secretome which is proangiogenic, antiapoptotic and immunomodulatory, all of which prove beneficial when overcoming injuries resulting from radiotherapy. The data suggests that CAL provides a superior method of treating radiation induced injuries compared to AFG, but a lack of well controlled clinical trials and a relative paucity of clinical data has restricted more widespread clinical adoption.

REFERENCES

1. Ryan JL (2012) Ionizing radiation: the good, the bad, and the ugly. J Invest Dermatol 132: 985-993.
2. Hymes SR, Strom EA, Fife C (2006) Radiation dermatitis: clinical presentation, pathophysiology, and treatment 2006. J Am Acad Dermatol 54: 28-46.
3. Neuber GA (1893) Verhandlungen der Deutschen Gesellschaftfür Chirurgie 1: 66
4. Delay E, Garson S, Tousson G, Sinna R (2009) Fat injection to the breast: technique, results, and indications based on 880 procedures over 10 years. Aesthetic Surg J 29: 360-376 .
5. ASPRS (1987) Ad-Hoc Committee on New Procedures. Plast Surg Nurs 7: 140-141.
6. Rigotti G, Marchi A, Galie M, et al. (2007) Clinical Treatment of radiotherapy tissue damage by lipoaspirate transplant: A healing process mediated by adipose-derived adult stem cells. Plast Reconstr Surg 119: 1409.
7. Sultan SM, Stern CS, Allen Jr. RJ, et al. (2011) Human fat grafting alleviates radiation skin damage in a murine model. Plast Reconstr Surg 128: 363.
8. Matsumoto D, Sato K,Gonda K, et al. (2006) Cell-Assisted Lipotransfer: Supportive Use of Human Adipose-Derived Cells for Soft Tissue Augmentation with Lipoinjection. Tissue Engineering 12: 3375-382
9. Salvo N, Barnes E, van Draanen J, Stacey E, Mitera G, et al. (2010) Prophylaxis and management of acute radiation-induced skin reactions: a systematic review of the literature. Curr Oncol 17: 94-112.
10. McQuestion M (2011) Evidence-based skin care management in radiation therapy: clinical update. Semin Oncol Nurs 27: e1-17
11. Goldschmidt H, Sherwin WK (1980) Reactions to ionizing radiation. J Am Acad Dermatol 3: 551-579.
12. Bentzen SM, Thames HD, Overgaard M (1989) Latent-time estimation for late cutaneous and subcutaneous reactions in a single-follow-up clinical study. Radiother Oncol 15: 267-274.
13. Arcangeli G, Friedman M, Paoluzi R (1974) A quantitative study of late radiation effect on normal skin and subcutaneous tissues in human beings. Br J Radiol 46: 44-50
14. Morgan K (2014) Radiotherapy-induced skin reactions: prevention and cure. Br J Nurs 23: S26-32.
15. Mu¨ller K, Meineke V (2011) Radiation-induced mast cell mediators differentially modulate chemokine release from dermal fibroblasts. J Dermatol Sci 61: 199-205
16. Amber KT, Shiman MI, Badiavas EV (2014) The use of antioxidants in radiotherapy-induced skin toxicity. Integr Cancer Ther 13: 38-45
17. Pie´rard GE, Pie´rard-Franchimont C, Paquet P, Quatresooz P (2009) Emerging therapies for ionizing radiation-associated skin field carcinogenesis. Expert Opin Pharmacother 10: 813-821.
18. Garza RM, Paik KJ, Chung MT, et al. (2014) Studies in fat grafting: Part III. Fat grafting irradiated tissue: Improved skin quality and decreased fat graft retention. Plast Reconstr Surg 134: 249-257.

19. Sultan SM, Stern CS, Allen Jr. RJ, et al. (2011) Human fat grafting alleviates radiation skin damage in a murine model. Plast Reconstr Surg 128: 363.
20. Eto H, Kato H, Suga H, et al. (2012) The fat of adipocytes after nonvascularized fat grafting: evidence of early death and replacement of adipocytes. Plast. Reconstr. Surg 129: 1081-1092.
21. Salgarello M, Visconti G, Barone-Adesi L (2012) Fat grafting and breast reconstruction with implant: another option for irradiated breast cancer patients. Plast Reconstr Surg 129: 317-329.
22. Phulphin B, Gangloff P, Tran N, et al. (2009) Rehabilitation of irradiated head and neck tissues by autologous fat transplaantation. Plast Reconstr Surg 123: 1187.
23. Ibchigolo F, Tatullo M, Pacifici A, et al. (2012) Use of dermal-fat grafts in the post-oncological reconstructive surgery of atrophies in the zygomatic region: clinical evaluations in the patients undergone to previous radiation therapy. Head Face Med 8: 33.
24. Hespe GE, Albornoz CR, MEhrara BJ, et al. (2013) CASE REPORT Pharyngocutaneous fistula closure using autologous fat grafting. Eplasty 9: 13.
25. Salgarello M, Visconti G, Farallo E (2010) Autologous fat grafting in radiated tissue prior to alloplastic reconstruction of the breast: report of two cases. Aesthet Plast Surg 34: 5-10.
26. Caviggioli F, Maione L, Klinger F, et al. (2016) Autologous fat grafting reduces pain in irradiated breast: a review of our experience. Stem Cells Int.
27. Maione L, Vinci V, Caviggioli F (2014) Autologous fat graft in postmastectomy pain syndrome following breast conservation surgery and radiotherapy. Aesthet Plast Surg 38: 528-532.
28. Luan A, Duscher D, Whittam J, et al. (2016) Cell-assisted lipotransfer improved volume retention in irradiated recipient site and rescues radiation-induced skin changes. Stem Cells 34: 668-673.
29. Rehmam J, Traktuev D, Li J, et al. (2004) Secretion of angiogenic and antiapoptotic factors by human adipose stromal cells. Circulation 109: 1292-1298.
30. Suga H, Eto H, Aoi N, et al. (2010) Adipose tissue remodeling under ischemia: death of adipocytes and activation of stem/progenitor cells. Plast Reconstr Surg 126:1911-1923.
31. Kato H, Mineda K, Eto H, et al. (2014) Degeneration, regeneration and cicatrization after fat grafting: dynamic total tissue remodeling during the first 3 months. Plast Reconstr Surg 133: 303-313.
32. Planat-Bernard V, Silvestre JS, Cousin B, et al. (2004) Plasticity of human adipose lineage cells towards endothelial cells: physiological and therapeutic perspectives. Circulation 109: 656-663.
33. Miranville A, Heeschen C, Sengenes C, et al. (2004) Improvement of postnatal neovascularization by human adipose tissue-derived stem cells. Circulation 110: 349-355.
34. Naderi N, Wilde C, Haque T, et al. (2014) Adipogenic differentiation of adipose-derived stem cells in a 3-dimensional spheroid culture (microtissue): implications for the reconstructive surgeon. J Plast Reconstr Aesthet. Surg.
35. Zuk PA, Zhu M, Mizuno H, et al. (2001) Multilineage cells from human adipose tissue: implications for cell-based therapies. Tissue Eng 7: 211-229.
36. Baer PC and Geiger H (2012) Adipose-derived mesenchymal stromal/stem cells: tissue localization, characterization, and heterogeneity. Stem Cells Int 3: 1–11
37. Ebrahimian TG,Pouzoulet F,Squiban C, et al. (2009) Cell therapy based on adipose tissue-derived stromal cells promotes physiological and pathological wound healing. Arterioscler Thromb Vasc Biol 29: 503-510.
38. Yuan Y, Gao J, Liu L, et al. (2013) Role of adipose-derived stem cells in enhancing angiogenesis early after aspirated fat transplantation: induction or differentiation? Cell Biol Int 37: 547-550.
39. Kim WS, Park BS, Kim HK, et al. (2008) Evidence supporting antioxidant action of adipose-derived stem cells: protection of human dermal fibroblasts from oxidative stress. J Dermatol Sci 49: 133-142.
40. Mohammadzadeh A, Pourfathollah AA, Shahrokhi S, et al. (2014) Immunomodulatory effects of adipose-derived mesenchymal stem cells on the gene expression of major transcription factors of T cell subsets. Int Immunopharmacol 20: 316-321.
41. Maria AT, Toupet K, Maumus M, et al. (2016) Human adipose mesenchymal stem cells as potent anti-fibrosis therapy for systemic sclerosis. J Autoimmun.
42. Huo Y, Ryu CH, Jun JA, et al. (2014) IL-8 enhances the angiogenic potential of human bone marrow mesenchymal stem cells by increasing

vascular endothelial growth factor. Cell Biol Int 38: 1050-1059.

43. Haleagrahara N, Chakravarthi S, Mathews L (2011) Insulin like growth factor-1 (IGF-1) causes overproduction of IL-8, an angiogenic cytokine and stimulated neovascularization in isoproterenol-induced myocardial infarction in rats. Int J Mol Sci 12: 8562-8574.
44. Sezer O, Jakob C, Eucker J, et al. (2001) Serum levels of the angiogenic cytokines basic fibroblast growth factor (bFGF), vascular endothelial growth factor (VEGF) and hepatocyte growth factor (HGF) in multiple myeloma. Eur J Haematol 66: 83-88.
45. Frazier TP, Gimble JM, Kheterpal I, et al. (2013) Impact of low oxygen on the secretome of human adipose-derived stromal/stem cell primary cultures. Biochimie 95: 2286-2296.
46. An HY, Shin HS, Choi JS, et al. (2015) Adipose mesenchymal stem cell secretome modulated in hypoxia for remodeling of radiation-induced salivary gland damage. PloS One 10: e0141862.
47. U.S. Department of Health and Human Services (2010) Common Terminology Criteria for Adverse Events (CTCAE) version 4.03.
48. Radiation Therapy Oncology Group (2016) RTOG/EORTC Late Radiation Morbidity Scoring Schema. 2016.
49. Khanna NR, Kumar DP, Laskar SG, et al. (2013) Radiation dermatitis: an overview. Indian J Burns 21: 24-31.