

Patent Ductus Arteriosus Patch Closure under Total Hypothermic Circulatory Arrest

Sarika Katiyar^{1*}, Sanjeev Gupta² and Rajni Chadar³

¹Department of Anesthesia, DNB, IDCC, Bhopal Memorial Hospital and Research Centre, Bhopal, India

²Bhopal Memorial Hospital and Research Centre, Bhopal, India

³Department of Anesthesia, DA, Bhopal Memorial Hospital and Research Centre, Bhopal, India

Received August 01, 2020; Revised August 14, 2020; Accepted August 16, 2020

ABSTRACT

PDA represents 5-10% of all congenital heart defects. Patent Ductus Arteriosus is most often diagnosed and surgically corrected in infancy, so a diagnosis of PDA in an adult of 29 years is rare. If not treated, it may lead to pulmonary hypertension, heart failure, Eisenmenger's syndrome and endarteritis. We present a case of large Patent Ductus Arteriosus who was treated under deep hypothermic circulatory arrest with complicated intraoperative sequelae.

Keywords: Total hypothermic circulatory arrest, Ductus arteriosus

CASE REPORT

A 29-year-old male 36 kg and 156 cm height was admitted with complaints of chest pain and breathlessness off and on for last 6 weeks. Symptoms were increasing in frequency. On clinical examination grade 2 parasternal heave and a continuous murmur was present at left upper sternal border. Chest X ray showed cardiomegaly (**Figure 1**). An echo revealed an 11 mm PDA (Lt-Rt shunt) with a mean gradient of 65 mm of Hg along with dilated pulmonary artery and mild MR and TR. As device closure was not possible so we planned for surgical closure via left thoracotomy. For this we inserted a double lumen tube of 30 French under effect of fentanyl 300 mcg, Midazolam-2 mg, Morphine-7.5 mg, Thiopentone-125 mg, and Rocuronium 50 mg. Right radial and left femoral arterial lines were cannulated and for central line right Internal Jugular Vein was used.

However, on thoracotomy pleura was adherent and thus after sending biopsy and CBNAAT (suspicion of TB), chest was closed. It was planned to do median sternotomy. Thus, we changed the double lumen tube to a single lumen tube of 8 mm size. On sternal retraction even pericardium was very adherent and calcified. Thus, pericardectomy was done PDA was isolated which was quite big. Thus, it was planned to close it under Total hypothermic circulatory arrest by putting a PTFE patch. This was done to prevent flooding of the pulmonary vasculature and for good visualization of the surgical field. BIS monitoring was done intraoperatively. Reading was noted to be 50. Nasopharyngeal temperature probe was already in place. Maintenance of anesthesia was done with vecuronium, fentanyl and isoflurane (not beyond

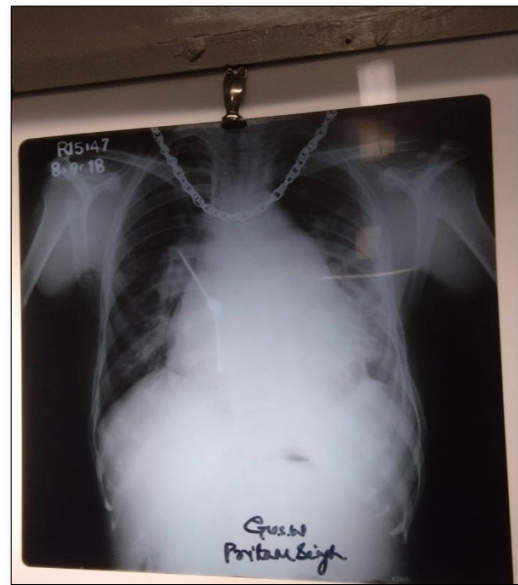

Figure 1. Chest X Ray showing Cardiomegaly.

Corresponding author: Sarika Katiyar, Department of Anesthesia and Critical care, BMHRC, Bhopal, India, Tel 075527422125102; E-mail: sarikaakatiyar@gmail.com

Citation: Katiyar S, Gupta S & Chadar R. (2021) Patent Ductus Arteriosus Patch Closure under Total Hypothermic Circulatory Arrest. Int J Clin Case Stud Rep, 3(1): 154-156.

Copyright: ©2021 Katiyar S, Gupta S & Chadar R. This is an open-access article distributed under the terms of the Creative Commons Attribution License, which permits unrestricted use, distribution, and reproduction in any medium, provided the original author and source are credited.

1 MAC) as per the hemodynamics. Intravenous heparin 400 units/kg was given. Cardiopulmonary bypass was initiated by aortic and bicaval cannulation. Patient was slowly cooled down to 20°C and BIS was noted to be 0. External cooling via mattress and head jacket filled with ice was done for brain protection. Intravenous Thiopentone 1 gram was administered through CPB just before arrest. Total circulatory arrest was done for 24 min and 7 min consecutively. Right pulmonary artery was opened, and PTFE patch closure of PDA was done as primary closure was not possible.

Thereafter patient was slowly rewarmed and weaned off CPB. Total cross clamp time was 65 min. Blood pressure was 110/52 mm of Hg on infusion of adrenaline at 8 mcg/kg/min and dobutamine at 5mcg/kg/min. Hemodynamics were within normal limits and thus heparin was reversed with protamine 150 mg. After closure patient was shifted to CTVS ICU, where he was planned for extubation the next morning. His chest X ray (**Figure 2**) on next day revealed right sided pneumothorax for which a right sided ICD insertion was done. Then patient was slowly weaned off the ventilator and extubated on 1st postoperative day in the evening. Initially he was delirious but then maintained on nasal prongs at 2-3 liters/min. Postoperative Echo showed no residual shunt. And finally, patient was discharged on 11th postoperative day.

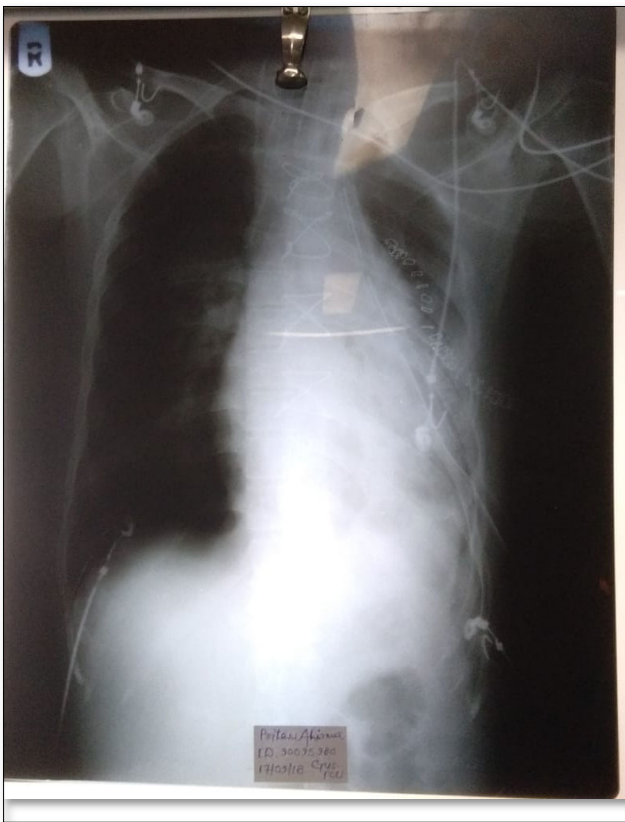


Figure 2. Chest X Ray showing Pneumothorax.

DISCUSSION

Patent Ductus Arteriosus is usually diagnosed shortly after birth and treated surgically or percutaneously to prevent the development of pulmonary hypertension and heart failure. This patient presented with a big PDA (11 mm) along with adherent pleura and pericardium. Thus, we had to change our plan to Total Circulatory arrest for good exposure and also to prevent flooding of pulmonary vessels. The aim of total hypothermic circulatory arrest is to cool the patient, cease blood flow to brain and rely on hypothermic protective effects of decreased cerebral metabolic rate of oxygen consumption. There is almost 6-7% decrease in brain metabolism with every 1° centigrade fall in body temperature. At 15-18°C CMRO₂ is decreased to 15%. As per Svensson et al. [1] safe duration to prevent neurological dysfunction is 40-60 min.

One analysis has suggested that the risk of stroke increases when the length of DHCA is longer than 40 min [2]. To prevent brain injury, we use intermittent hypothermic circulatory arrest technique to allow cerebral circulation. Slow cooling is advised homogenous hypothermia of cerebrum. Similarly, slow rewarming should be done to a temperature of 36°C before weaning from CPB. Postoperatively temperature should be maintained at 36-37°C [3].

We had used BIS for neurological monitoring but with very little evidence as it is interfered by Anesthetic agents, hypothermia etc. We avoided steroids because of non-availability of Methyl Prednisolone and secondarily it caused hyperglycemia, which might hamper its neuroprotective effects. Postoperatively these patients need close monitoring as temperature may decrease residual shunt, bleeding, coagulopathy and hemodynamic monitoring. Hypoxemia and hypotension should be avoided. Cognitive disorders are quite common after THCA [4,5].

REFERENCES

1. Svensson LG, Crawford ES, Hess KR, Cosdle JS, Raskin S, et al. (1993) Deep Hypothermia with circulatory arrest. Determinants of stroke and early mortality in 656 patients. *J Thoracic Cardiovasc Surg* 106: 19-28.
2. Gega A, Rizzo JA, Johnson MH, Tranquilli M, Farkas EA, et al. (2007) Straight deep hypothermic arrest: experience in 394 patients supports its effectiveness as a sole means of brain preservation. *Ann Thorac Surg* 84: 759-766.
3. Kumral E, Yuksel M, Buket S, Yagdi T, Atay Y, et al. (2001) Neurologic complications after deep hypothermic circulatory arrest: Types, predictors and timing. *Tex Heart Inst J* 28: 83-88.
4. Leibuss R, Kalejs M, Ozolina A, Skride A, Stradins P, et al. (2013) Anesthesia management with deep hypothermic circulatory arrests during pulmonary

thromboendarterectomy. *Acta Chirurgica Latviensis* 13: 93-96.

5. Welz A, Pogarell O, Tatsch K, Schwarz J, Cryssagis K, et al. (1997) Surgery of the thoracic aorta using deep hypothermic total circulatory arrest: Are there neurological consequences other than frank cerebral defects? *Eur J Cardiothoracic Surg* 11: 650-656.