

Microperimetry and Multifocal Electroretinogram in the Detection of Chloroquine Retinopathy: Case Series

Yannara Elina Columbie Garbey* and Odelayis Hernandez Echavarria

*Department of Neuro-ophthalmology, Cuban Ophthalmology Institute, "Ramon Pando Ferrer," Havana, Cuba.

Received July 17, 2018; Accepted October 05, 2018; Published December 20, 2018

ABSTRACT

We describe 7 cases of retinal toxicity due to chloroquine in patients with systemic lupus erythematosus and drug use for 24 and 30 years, with doses of 250 mg daily that accumulate in total doses of 2190 g and 2737 g, respectively, for the first two cases and time of consumption between 2 and 6 years for the rest of the patients, with an average cumulative dose of 337.53 g. The patients underwent complete ocular examination, microperimetry, optical coherence tomography and multifocal electroretinography. The first case had a color vision dysfunction, without affecting visual acuity and contrast sensitivity, corneal deposits, loss of central retinal sensitivity of 14 dB in the microperimetry, evident fundus maculopathy, reduction of the retinal thickness in the macular area at 138 μm , with loss of the internal segment/junction of the external segment in the perifoveal region, loss of the foveal peak in the three-dimensional image with reduced P1 amplitude in the central rings in the multifocal electroretinogram. The second case showed a serious affectionation of all the visual psychophysical parameters, diminished retinal sensitivity to 4 dB in the microperimetry, obvious maculopathy, macular thickness reduced to 108 μm , with loss of the internal/external segment in the macular, without foveal peak and P1 reduced Amplitude in all hexes in multifocal electroretinography. These cases illustrate different forms of retinal toxicity with chloroquine, apparently depending on the cumulative dose of the drug. The remaining 5 cases presented normal physical examination with slight loss of the internal/external segment of the photoreceptors, decreased retinal sensitivity in the microperimetry and decreased foveal peak in a smaller amount than the first two patients. Multifocal electroretinography, microperimetry and optical coherence tomography are useful to detect visual impairment at different stages of the disease.

Keywords: Chloroquine retinopathy, Microperimetry, Multifocal electroretinogram, Optical coherence tomography

INTRODUCTION

Chloroquine (CQ) is a 4 aminoquinolona used in the treatment of rheumatic diseases, particularly rheumatoid arthritis and lupus erythematosus since the early fifties. It can produce a dose-dependent iatrogenic affecting the retina, and was first described by Hobbs in 1959. Conducting research for the detection of retinopathy has been subject to controversy. Recent studies agree that it is unnecessary to conduct screening when the doses are below 3 mg/kg/day for a period of less than 5 years and there are no risk factors [1-4]. Currently the disease is still reported as a rare event, with a low incidence at least with current methods of screening.

In recent times perimetry fund or microperimetry has been used frequently for the functional assessment of patients with any type of maculopathy, using morphofunctional evaluation. Microperimetry accurately determines the location and fixation and stability of retinal threshold in the macular area, thus allows the projection medical diagnostic improve the various macular disorders.

We present two cases of chloroquine retinal toxicity after prolonged use, with different characteristics with regard to

the pattern of damage and the characterization of the alterations by different diagnostic methods including microperimetry.

CASE REPORTS

1st case

A 56 year old woman with a history of lupus erythematosus consumed 250 mg of chloroquine daily for 24 years. She described progressively slow blurred vision that causes problems reading for a period of 1 year. The psychophysical studies that include the best corrected visual acuity (BCVA), contrast sensitivity (CS) and color vision (CV) are shown in

Corresponding author: Yannara Elina Columbie Garbey, MD, Department of Neuro-ophthalmology, Cuban Ophthalmology Institute, "Ramon Pando Ferrer," Havana, Cuba, E-mail: elina1379@gmail.com

Citation: Garbey YEC & Echavarria OH. (2018) Microperimetry and Multifocal Electroretinogram in the Detection of Chloroquine Retinopathy: Case Series. *Ophthalmol Clin Res*, 1(2): 22-27.

Copyright: ©2018 Garbey YEC & Echavarria OH. This is an open-access article distributed under the terms of the Creative Commons Attribution License, which permits unrestricted use, distribution, and reproduction in any medium, provided the original author and source are credited.

The slit-lamp examination showed corneal opacities in the right eye (RE), but not other anomalies in the previous segment (**Table 1**). In the background there was discrete bilateral temporal paleness of both optic nerves, with no changes in the retinal pigment epithelium (RPE) in the macular area (**Figure 1**). Microperimetry (Nidek Technologies, MP-1) showed a normal mean retinal sensitivity in the macular areas: 11 dB RE and 14 dB left eye (LE) (**Figure 2**). The optical coherence tomography showed

a minimal loss of peripapillary fibers and a decrease in the temporal and superior quadrants in both eyes, as well as a loss of the thickness of the macular retina at 141 μm RE and 136 μm LE. And, there was a loss of the inner junctions/outer segment in both eyes (**Figure 3**). Multifocal electro retinography (Roland Consult, mfERG) showed loss of the foveal peak in the three-dimensional image, with a reduction of the P1 amplitudes predominantly in rings 1 to 4, with average values of 11.8 nv/deg^2 and 35.4 ms.

Table 1. Corrected psychophysical studies.

Eye	BCVA (VAR)	BCVA	CS (log units)	CV
	Bavie-Lovie Chart	Snellen	Pelli-Robson Chart	Ishihara, 21 plates
RE	100	20/20	1.65	1
LE	100	20/20	1.65	1

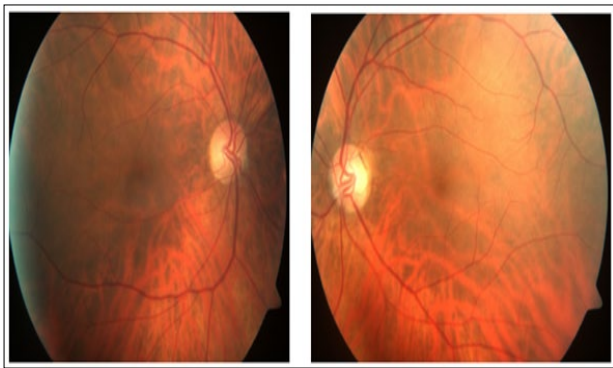


Figure 1. Mild bilateral temporal pallor of the optic nerve with foveal reflective absent.

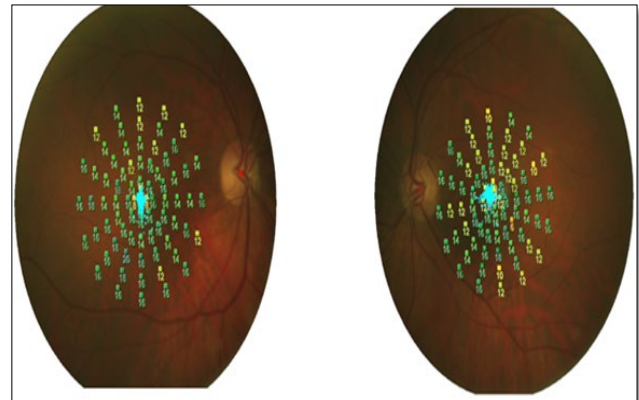


Figure 3. Microperimetry with half retinal sensitivity in 11 dB right eye and 14 dB left eye.

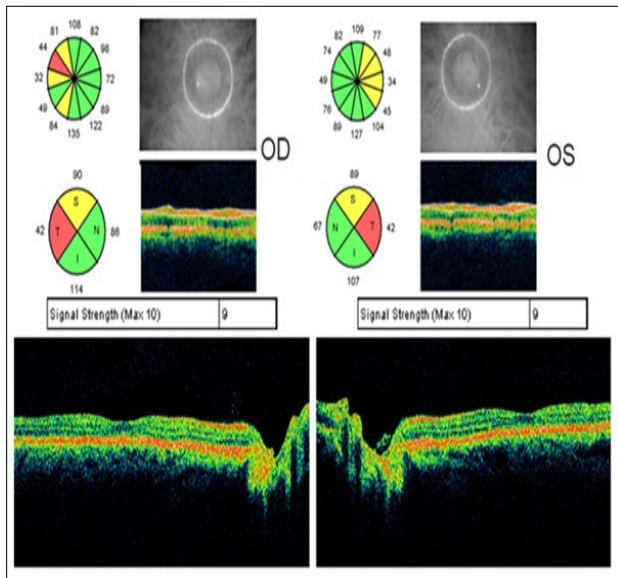


Figure 2. Loss of nerve fibers in quadrants temporal and superior in both eyes, decrease of nerve fibers layer reflecting cause by loss of the inner/outer segment junctions in the perifoveal region.

2nd case

A 64 year old woman with a history of lupus erythematosus treated with chloroquine 250 mg daily for 30 years. She refers progressive decrease in visual acuity for 3 years, accompanied by distortion of objects. Psychophysical studies including best corrected visual acuity (BCVA), contrast sensitivity (CS) and color vision (CV) are shown in **Table 2**. Slit lamp examination without abnormalities in the anterior segment. Fundoscopy showed bull's eye maculopathy in both eyes (**Figure 4**). Optical coherence tomography showed decreased retinal thickness to 104 μm RE and 112 μm LE in macular area, as well as greater loss of the inner segment/outer segment photoreceptor junctions (**Figure 5**). Microperimetry presented a mean retinal sensitivity of 5 dB RE and 7 dB LE (**Figure 6**). The mfERG showed loss of foveal peak, with a marked decrease of P1 amplitudes in all rings, and to a lesser degree of involvement of the P1 latency in rings 1 to 4, with respect to the normal patient records 9.21 nv/deg^2 mean values and 27.8 ms (**Table 3**).

Table 2. Best corrected psychophysical studies.

Eye	BCVA (VAR) Bavie-Lovie Chart	BCVA Snellen	CS (log units) Pelli-Robson Chart	CV Ishihara, 21 plates
RE	10	20/400	null	1
LE	70	20/80	0.75	1

Table 3. Psychophysical studies for total doses.

Case	Eye	Accumulating to total doses	BCVA (VAR)	BCVA Snellen	CS (log units) Pelli-Robson Chart	CV Ishihara, 21 plates	Retinal sensitivity MP1 (dB)
3	RE	136.9	100	20/20	1.65	21	14.0
	LE		100	20/20	1.65	21	16.7
4	RE	365.0	100	20/20	1.65	9	14.3
	LE		100	20/20	1.65	8	16.0
5	RE	547.5	100	20/20	1.65	20	16.0
	LE		100	20/20	1.65	20	13.0
6	RE	456.2	100	20/20	1.65	21	18.0
	LE		100	20/20	1.65	21	15.5
7	RE	182.5	100	20/20	1.65	21	15.0
	LE		100	20/20	1.65	21	17.5

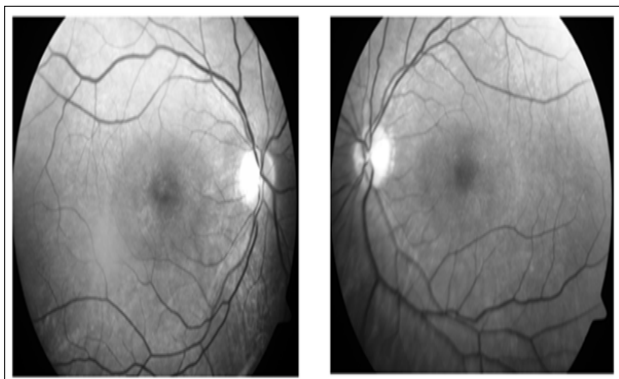


Figure 4. Red free photography showed Bull eyes maculopathy in both eyes.

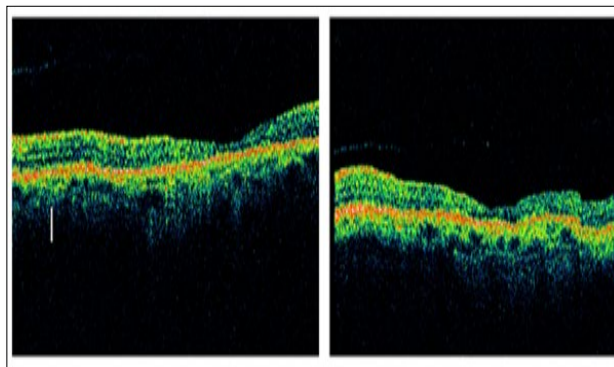


Figure 5. Marked decrease of nerve fibers layer reflecting cause by loss of fibers and pigmentary epithelium gross or diminished, as well as greater loss of the inner/outer segment junctions.

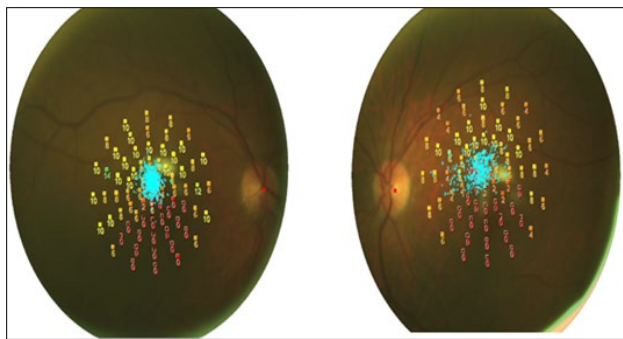


Figure 6. Microperimetry with half retinal sensitivity in 5 dB right eye and 7 dB left eye.

DISCUSSION

Retinopathy of chloroquine (CQ) is still reported as a rare event, especially after the increased use of hydroxychloroquine (HCQ) in the world, deriving the latter less toxic. In our environment by the limited availability of HCQ, CQ remains the choice in the treatment of rheumatic diseases with prolonged use due to the chronic course of the same. For these reasons it is more likely that patients taking this drug presented its toxic effects. The mechanisms by which toxic retinopathy occurs are not well known although it appears that oxidative stress caused anti-malarials in the retina play an important role. The CQ has acute effects on the metabolism of the cells of the retina, including photoreceptors. However, histopathologically, the earliest changes occur in the ganglion cell [5,6]. Clinically CQ retinopathy is characterized by bilateral and occasionally loss of visual field asymmetric shaped paracentral scotoma within 4 to 9 degrees of fixation and it precedes the development of clinical background, is often accompanied by defects in color perception. The first clinical data include a mild pigment mottling with loss of foveal reflex to evolve, in advanced stages, the typical target picture or bull's eye. The VA is compromised when there is macular involvement [5,7-9]. Alterations, if slight, can be reversed after discontinuation of medication. In advanced cases, the abnormalities may continue despite the suspension [2,5,10,11].

According to current trends despitaje studies for detection of retinal damage by consumption of CQ and its derivatives, there is a risk of toxicity with daily doses above 3 mg/kg of weight for more than 5 years of use and cumulative dose greater than 460 g. The elderly over 60 years and kidney disease, liver and retinal are also basic retinotoxicity potential risk [1,12,13]. Recently, the American Academy of Ophthalmology has updated its recommendations for the retinotoxicity pesquizaje by CQ and its derivatives, suggesting a series of diagnostic tools including multifocal electroretinogram (mfERG), optical coherence tomography in the frequency domain (SD-OCT), retinal autofluorescence and automated perimetry 10^{-2} program, all useful for their

sensitivity in detecting early-stage retinal damage, which is really the goal of despitaje studies [1] As it is known that in advanced stages when maculopathy appears, it is highly unlikely the recovery of visual acuity.

In the first two cases analyzed, retinal damage was secondary to the prolonged consumption of CQ. Although both showed abnormalities on physical examination, differed in the severity of visual dysfunction. With regard to psychophysics the first case with a cumulative dose of 2190 g, higher than the recommended 460 g showed no involvement of the VA or CS, but color vision was affected. In relation to color, taking into account that there was no maculopathy states, that it affected the green and red axis and did not have a baseline study before we cannot exclude that the patient had a congenital defect of color vision, but this anomaly is very rare in women (0.4 to 0.5%) [14] On the other hand, although the loss of fibers in the papillomacular bundle would justify a dysfunction of color, does not correspond with the results of other psychophysical parameters (VA and CS) completely normal. The second case with a cumulative dose of 2737 g presented same impairment of color vision, in addition to severe impairment of visual acuity and contrast sensitivity, changes that can be explained by the maculopathy and loss of normal pattern of nerve fibers. Recent studies claim that the color test is not sensitive to detect early retinal damage due to errors in color vision are not specific to CQ toxicity and may occur in other macular diseases and optic nerve [1]. Ophthalmoscopy showed maculopathy, with changes in the retinal pigment epithelium (RPE) in the second case, not in the first, which only detected the absence of foveal brightness, in the ophthalmoscopic studies has proved useful to document pre-existing maculopathy before the use of medication and see changes in pigmentation of the macula and changes over time with use of the drug, but not for detection of subclinical damage, because when the changes are visible is highly unlikely that the damage can be reversed [1]. The fourth case presented chromatic alterations, with normal visual acuity, contrast sensitivity and ophthalmoscopy. The remaining 4 patients did not present dysfunction in the visual psychophysical studies. The OCT confirmed the loss of fibers in papillomacular bundle in the first case and decreased retinal thickness in the macular region, as well as loss of the inner segment/outer segment (IS/OS) junctions for all patients. Rodriguez et al. [15] in a study of 15 patients treated with hydroxychloroquine, retinal abnormalities confirmed using high-speed Ultra-High-Resolution Optical Coherence Tomography. These abnormalities appeared to progress in severity from distinctive loss of the IS/OS photoreceptor junction with preservation of the fovea to more generalized loss of the IS/OS junction. In patients that were examined with stratus OCT photoreceptor layer disruption was visible only in some cases. In our case, there was greater disruption of photoreceptors in the second case with clinically evident maculopathy.

The mfERG according to different studies seems to have become the gold standard test to detect CQ damage in early stages and to follow after discontinuing the drug [11,16-19]. In our patients despite being in different stages of toxicity with and without maculopathy, the mfERG demonstrated retinal dysfunction, affecting P1 amplitudes in all cases and changes in implicit time only in cases with bull eyes maculopathy. The rings 1 to 4 were the most affected, with major changes in the patient with a higher cumulative dose of the drug. Has been shown by other authors that the time of prolonged medication use and therefore higher cumulative doses predisposes to retinal toxicity and therefore changes occur gradually over the mfERG [16].

Microperimetry test is useful for the study of macular diseases and available in our environment in all ophthalmology centers. Allows a detailed study of central retinal sensitivity with accurate topographic correlation between the fundus details. In our patients select the program Macula 20 degrees, 4² threshold strategy, Goldmann III. In the first case without maculopathy, the fixation was stable with a decrease in mean retinal sensitivity 6 dB with respect to normal values between 18 and 20 dB, despite not being impaired visual acuity and contrast sensitivity this study to quantify the functional deficit. The second case presented with an unstable fixation reduced the sensitivity to 12 dB compared to normal, functional impairment was higher, corresponding to structural changes. In the third and fourth cases, the fixation was stable with a decrease in the mean retinal sensitivity by 5 dB. The fifth case presented a decrease of 6 dB and the remaining two cases of 4 dB.

We are the criteria that microperimetry, allows an analysis of the visual quality reliable and reproducible, when examining the same retinal points in each study, which joined the mfERG that determines the focal retinal sensitivity and the changes that occur even before clinically evidencing the damage, are useful tools to allow monitoring with the same parameters evaluated in the initial examination. In the second case by the severe impairment of visual acuity, visual rehabilitation was started, for which the microperimeter MP1 was useful in the evaluation of fixation.

CONCLUSION

The behavior of the retinal toxicity of CQ and its derivatives depends largely on the cumulative dose of the drug. The microperimetry showed changes in retinal sensitivity even in the absence of visible maculopathy or changes in psychophysical studies. Microperimetry with the mfERG and OCT can be a useful tool in the screening procedure chloroquine toxicity.

REFERENCES

1. Gilhotra JS, Mitchell P, Healey PR, Cumming RG, Marmor MF, Kellner U, Lai T, Lyons J, Mieler W (2011) Revised recommendations on screening for

chloroquine and hydroxychloroquine retinopathy. *Ophthalmology* 118: 415-422.

2. Browning DJ (2002) Hydroxychloroquine and chloroquine retinopathy: screening for drug toxicity. *Am J Ophthalmol* 133: 649-656.
3. Quijada E, Pareja A, Mantolán C, Cordoves LM, Losada MJ, et al. (2007) Screening protocol side effects of anti-malarials. *Arch Soc Canar Oftal*.
4. Marmor MF (2004) Current recommendations on screening for hydroxychloroquine or chloroquine retinopathy. *Sociedad Iberoamericana de Información Científica (SIIC)*.
5. Rodríguez FJ (2000) Retinal toxicity and retinal pigment epithelium by chloroquine and hydroxychloroquine. *J Rheumatol* 7: 37-41.
6. Shroyer NF, Lewis RA, Lupski JR (2001) Analysis of the ABCR (ABCA4) gene in 4-aminoquinoline retinopathy: Is retinal toxicity by chloroquine and hidroxychloroquine related to Stargardt disease? *Am J Ophthalmol* 131: 761-766.
7. Jimenez-Palop M (2006) Malaria: an update of its use in rheumatic diseases. *Rev Spanish Soc Rheumatol* 2.
8. Orozco-Gomez LP, Ruiz-Morfin I (2005) Bull's-eye maculopathy. *Rev Mex Oftalmol* 79: 51-53.
9. Mavrikakis I, Sfrikakis P, Mavrikakis E, Rougas K, Nikolaou A, et al. (2003) The incidence of irreversible retinal toxicity in patients treated with hydroxychloroquine. *Ophthalmology* 110: 1321-1326.
10. Lyons JS, Severns ML (2007) Detection of early hydroxychloroquine retinal toxicity enhanced by ring ratio analysis of multifocal electroretinography. *Am J Ophthalmol* 143: 801-809.
11. Gaynes BI, Torczynski, Varro Z, Grostern R, Perlman J (2008) Retinal toxicity of chloroquine hydrochloride administered by intraperitoneal injection. *J Appl Toxicol* 28: 895-900.
12. Restrepo JF, Guzmán R, Iglesias A (2002) As anti-malarial drugs induce remission in rheumatoid arthritis. *J Rheumatol* 9: 62-68.
13. Ferreras A, Pinilla I, Abecia E, Pajarin AB, Honrubia FM (2007) Retinal toxicity secondary to treatment with chloroquine. *Arch Soc Esp Oftalmol* 82: 103-108.
14. Swanson WH, Cohen JM (2003) Color vision. *Ophthalmol Clin North Am* 16: 179-203.
15. Rodriguez-Padilla JA, Hedges III TR, Monson B, Srinivasan V, Wojtkowski M, et al. (2007) High-speed ultra-high-resolution optical coherence tomography findings in hydroxychloroquine retinopathy. *Arch Ophthalmol* 125: 775-780.

16. Lai TY, Chan WM, Li H, Lai RY, Lam DS (2005) Multifocal electroretinographic changes in patients receiving hydroxychloroquine therapy. *Am J Ophthalmol* 140: 794-807.
17. Marmor MF (2005) The dilemma of hydroxychloroquine screening: new information from the multifocal ERG. *Am J Ophthalmol* 140: 894-895.
18. Elder M, Rahman AM, Melay J (2006) Early paracentral visual field loss in patients taking hydroxychloroquine. *Archiv Ophthalmol* 124: 1729-1733.
19. Maturi RK, Yu M, Weleber RG (2004) Multifocal electroretinographic evaluation of long-term hydroxychloroquine users. *Arch Ophthalmol* 122: 973-981.