

Rehabilitation of Hemianopic Patients with Palomar Prisms

Fernando J Palomar-Mascaró^{1*}, M Virginia Palomar-Mascaró² and Pedro V de Miguel Simó²

¹Consultorio Oftalmológico Palomar and Centro Optométrico Palomar, Barcelona, Spain

²Centro Oftalmológico Palomar, Barcelona, Spain.

Received September 24, 2018; Accepted October 07, 2018; Published December 21, 2018

ABSTRACT

Purpose: To study if rehabilitation and partial recovery of the visual field is possible in the context of complete homonymous hemianopia (CHH) with Palomar's attached prisms. Demonstrate that with a precise calculation of placement and power, no diplopia and no central scotoma of visual field (VF) appears and no exophoria is induced.

Methods: The present study describes the rehabilitation of 48 patients with CHH with binocular Palomar prisms; all the patients had neuro-ophthalmologic symptoms with sector field loss characteristic of CHH. We tested the effectiveness of Palomar prism treatment for CHH, consisting in attaching prism strips to both lenses of the patient's glasses. A control was carried out at month of use, at six months and then annually, with a follow-up of 2 years.

Results: Results revealed that patients improved their ability to locate objects in the loss Field view, that is, by means of practice and adaptation. No diplopia and no central scotoma or exophoria induced appear in any case.

Conclusion: Successful fitting of binocular sectorial prisms was achieved through adjustment of prism power and location to ensure smooth transition between both hemifields of view and to avoid diplopia in primary gaze. Prism power was obtained through empirical calculation based on distance and near prism power requirements, as determined with trial lens prisms, which also allowed for determination of the best prism location and its power.

Keywords: Hemianopia, Low vision, Palomar prisms, Rehabilitation, Loss of visual field

INTRODUCTION

Homonymous hemianopsies (HH) can be defined as the absolute or partial loss of vision in the right or left hemispheres of the VF of both eyes [1,2].

Patients diagnosed with a complete hemianopsic defect, even with far distance and near visual acuity, complaint of significant difficulties in their daily activities, including inadequate mobility and frequent collision with unseen objects among others [3].

The prevalence of HH is of approximately 0.8% in the general population older than 49 years [1], with about 2 million stroke survivors in rehabilitation suffering from either HH or hemineglect in the United States annually [2,4]. HH from post-chiasmatic visual pathway injuries are primarily caused by posterior cerebral artery infarction and, to a lesser extent, by head trauma, tumors and surgery [1,2,4].

A number of studies [4-6] have reported that the use of prisms can be an effective treatment for CHH. Palomar-Petit [7] described how the central field could be restored by placing small prism strips on to the spectacle lenses of patients. Gottlieb et al. [8] have proposed the use of a monocular sector prism that was affixed to the side of the lens corresponding to the lost visual field (VF). He interpreted that confusion would arise due to the appearance

and visibility of an object which would be invisible without the prism. He also noted that diplopia occurred with the expansion of the resulting field of vision (FoV), which could be very disorienting and unpleasant for the patient.

Gottlieb et al. [8] examined the use of 15-diopter plastic press-on Fresnel prisms as a means of recovering the FoV in 18 patients with stroke and HH. The authors concluded that the treatment with 15-diopter Fresnel prisms improves visual perception test scores, but not the performance on the Barthel ADL test [9], in stroke patients with HH or unilateral visual neglect.

Gottlieb et al. [8] Zihl [10] and also Kasten et al. [11] suggested that regular training of the blind FoV using visual stimuli similar to those used in a computer-controlled

Corresponding author: Fernando J Palomar-Mascaró, Consultorio Oftalmológico Palomar and Centro Optométrico Palomar, Barcelona, Spain, E-mail: fpalomar@centrospalomar.com

Citation: Palomar-Mascaró FJ, Palomar-Mascaró MV & de Miguel Simó PV. (2018) Rehabilitation of Hemianopic Patients with Palomar Prisms. *Ophthalmol Clin Res*, 1(2): 28-34.

Copyright: ©2018 Palomar-Mascaró FJ, Palomar-Mascaró MV & de Miguel Simó PV. This is an open-access article distributed under the terms of the Creative Commons Attribution License, which permits unrestricted use, distribution, and reproduction in any medium, provided the original author and source are credited.

perimetry test could facilitate recovery of the FoV next to the midline and provide an expansion of the FoV.

Cohen and Waiss [12], also defend as a technique of rehabilitation of hemianopic patients, the binocular use of Fresnel prisms adapted sectorial. Despite this, they indicate that they reduce the FoV because they cause an optically induced scotoma in the center of the lens. They also suggest the use of twin binocular prisms, or full diameter, mounted on the eyeglass with the base towards the side of the loss, usually 20 diopters, which cause a repositioning of the entire visual field.

Pambakian and Kennard [13] addressed the issue of whether it was possible to restore visual function in patients with CHH. They emphasized the importance of several rehabilitation treatments, such as psychophysical techniques, for improving care in the blind half of the FoV. They also suggested the possibility of using optical aids, hemianopic mirrors and prisms, as well as cognitive techniques for improving eye movements. They acknowledged that the effectiveness of such treatments was not properly detailed, since there was insufficient research and most published studies suffered from some methodological flaw.

In a comprehensive review, Peli [14] classified the effects of the instruments used in the rehabilitation of hemianopia into two groups: those relocating the FoV and those producing expansion. He argues that the expansion effect of the FoV is preferred because the simultaneous FoV is wider and allows the patient to control the environment at all times, thus enabling safer mobility. However, relocation only changes the position of the lost FoV or its relative position with regard to the midline. This author also holds that the FoV changes when viewed through binocular sectors.

Peli [14] points out that patient have an optical loss of FoV in the centre of the FoV (scotoma) caused by the binocular sectorial prism.

Peli [15] has also developed a method consisting in a monocular sectorial prism fit on the eye with the side of the defect and limited to the top or bottom FoV or covering both peripheral FoV. This prism has to be placed across the entire width of the lens in order to be effective in all lateral positions of gaze. The prism expands the FoV by promoting peripheral diplopia, producing optically peripheral exotropia, while maintaining bifoveal alignment [14,15].

Peli [14] stated that this expansion of the FoV can be measured with standard binocular perimetry because it is effective in all positions of gaze, including the primary position. He uses 40-diopter Fresnel prisms, which give a spread of approximately 20° around the midline. However, since the prism only affects the peripheral vision, one could use another prism of greater power.

O'Neill et al. [16] proposed the use of monocular prisms on the side of the complete hemianopia, with bases at the

default address. In this way a peripheral exotropia is produced, which achieves the expansion of the FoV. With regard to the success of the rehabilitation process, Palomar-Mascaró et al. [17-19] emphasized the importance of ascertaining the prismatic power, as well as the need to ensure the correct position when attaching the binocular prism to the lens.

PARTICIPANTS

48 patients with HHC (18 female, 30 male), ranging in age from 18 to 76 years, participated in the study.

The etiology of the condition was due to different causes, 11 cases due to primary or secondary neoplasms of the cerebellum, 32 due to vascular alterations (66.66%), 3 due to trauma and 2 to inflammatory disorders of the central nervous system.

The inclusion criteria for the group of patients with CHH congruous (37 HHC left, 11 HHC right) were 1) diagnosis of CHH from more than one year, assessed by Dicon's computerized perimetry (Paradigm Medical) and confirmed neurologically by CT or MRI; 2) normal or corrected visual acuity (VA) between 20/20 and 20/40 in both eyes with normal intrinsic and extrinsic ocular motility.; 3) Treatments with attached prisms of Palomar, with a follow-up of more than two years and 4) no previous treatment aimed at others visual rehabilitation. Exclusion criteria for this group were 1) anosognosia for the hemianopia and evidence of mental disorder or serious physical impairment; 2) incongruous HHC; 3) not having a follow up of visits and visual fields for two years and 4) normal or corrected VA below 20/40.

Presbyopic participants wore the appropriate addition for 40 cm working distance.

Participants provided written informed consent after the nature of the study had been explained to them. The Declaration of Helsinki tenets of 1975 (as revised in October in 2008) were followed throughout the study, which received approval from the direction Palomar Centers.

Treatment description: Palomar prism

The overall goal of vision rehabilitation is to reduce the effects of visual disability resulting from hemianopia. The treatment makes use of Palomar binocular sectorial prisms that are attached vertically to the patient's glasses, with the bases of the prism oriented towards the anopic area (**Figure 1**). This accessory facilitates access to the patient's lost FoV, helping him/her with spatial orientation [3,18]. The power of the attached prisms was determined in order to ensure their appropriateness for both, distance and near vision. The prisms had 20-25 diopters for far visual distance and 15-20 diopters for near vision, and were attached to the centre of the glass lenses in vertical strips. The bases of the prism were oriented toward the side of the homonymous hemianopic defect. Depending on the homogeneity of the loss to central field of vision, the prisms were usually shifted

between 1 mm and 5.5 mm from the centre to the hemianopic side. To check participants' efficacy we used a computerized perimeter and presented the stimulus in a range around 30° eccentricity (**Figure 2**). The effectiveness was also checked by performing a 60° field to assess the expansion of the central field (**Figure 3**).



Figure 1. Top view (left panel) of the spectacles of a patient with right homonymous hemianopia, showing the Palomar attached prisms, whose bases are oriented towards the right and (right panel) the spectacles of a patient with left homonymous hemianopia.

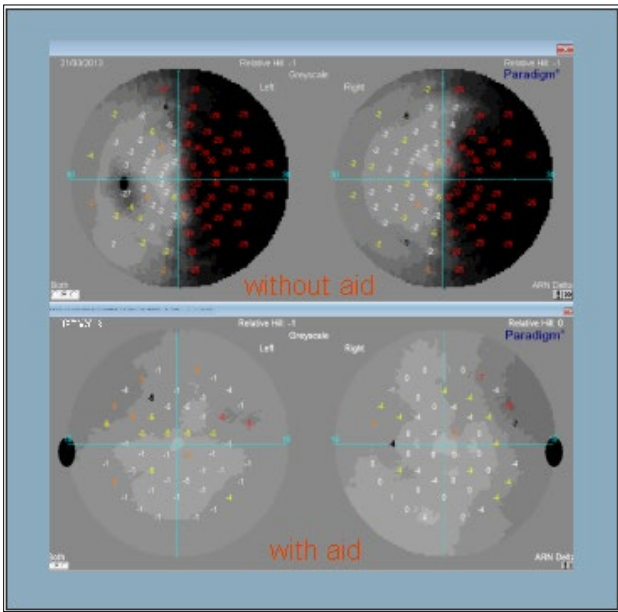


Figure 2. Visual field of 30° with and without prisms. The total recovery of the central visual field can be appreciated.

The patient simultaneously receives images from the FoV of the left and right eyes, projected onto the functional hemiretinas. Images corresponding to the FoV of the non-functional hemiretina were then captured through the prisms (**Figure 3**). Upon receiving these two different overlapped images, it is likely that the patient will have to sequentially process these images. Consequently, the visual system must perform a reconstruction of the visual space subtended for each eye, combining (merging) both reconstructed spaces. Thus, using the campimeter (perimeter) it is possible to assess the restored central FoV by comparing the spatial localization accuracy under both conditions that is, executed

with or without the aid of the attached prisms (**Figure 4**). In this way, any beneficial effects of treatment can be quantified.

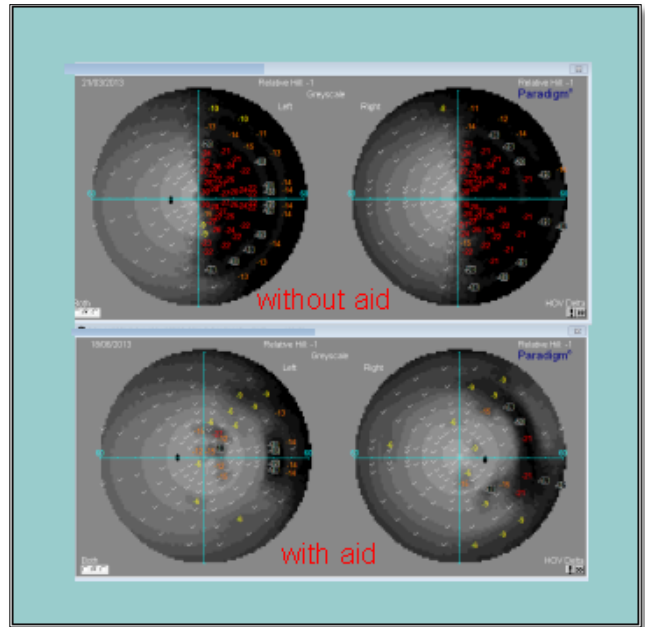


Figure 3. Visual field of 60° with and without prisms. The recovery of between 30° and 40° of the visual field can be observed.

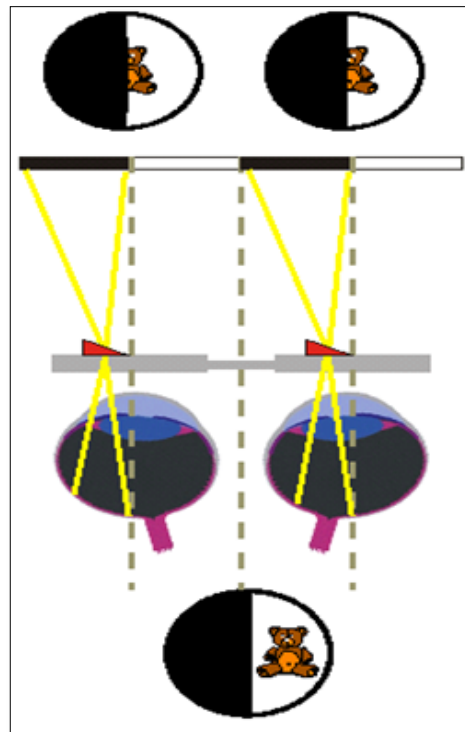


Figure 4. Diagram illustrating the functioning of the attached prisms in the case of a patient with left CHH.

PROCEDURE

The patients attended in our ophthalmology practice complaining of severe limitations in such habitual tasks as house care, reading, shopping or watching television, associated with a right visual field loss. Spatial orientation and mobility difficulties required constant assistance for walking and all out-of-home activities. A specifically designed questionnaire for HH visual impairment assessment, based on the 14-item visual function index questionnaire (VF-14) [20] was employed to investigate the difficulties in visually dependent daily activities encountered by the patient.

The patients underwent a complete exploration including extrinsic and intrinsic ocular motility, ocular deviations, Slit-lamp and ophthalmoscope examinations, refraction, confrontation fields, Bjerrum tangent screen test at 1 m.

Automatic threshold visual fields testings (Dicon LD400 auto-perimeter) of 60°, 30° and 10°. The respect of the middle line and the phenomenon of visual extinction were verified in all of them, by means of a computer application designed for this purpose.

We proceeded to adapt the Palomar's attached prisms. Prismatic lens power was obtained by calculation based on the empirical formula [3]:

$$PT=PD+2/5 PN$$

Where, PT is total prism power and PD and PN are required prism power for distance and near vision, respectively. Prism power for distance and near vision were determined with the aid of our trial case prisms (**Figure 5**) and a trial spectacle frame (**Figure 6**). Using the formula above, we determine the prismatic power appropriate for each patient. We place the prisms provisionally and check the exact position of centering.



Figure 5. Reduced trial case Palomar prisms, with prisms of 10, 15, 25 and 30 prism diopters.

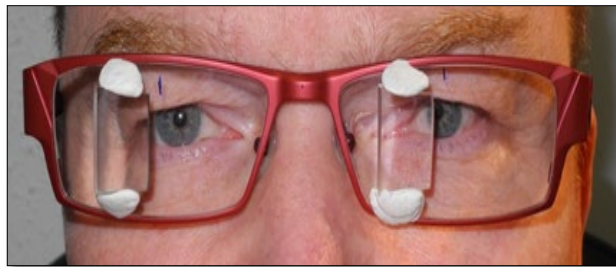

Figure 6. Detail of the Palomar prisms on her glasses with adhesive removable putty, to determine the necessary prismatic power by trial and error, in this case of right HH.

Making glasses with his prescription and with the prisms of Palomar, delivering it to the 15 days. Palomar prisms were oriented with their base towards the hemianopic side (base out on the temporal half of the right spectacle lens and base in on the nasal half of the left spectacle lens) and the apex of the prism is placed at a distance between 1.5 mm and 4 mm from the center of the pupil.

To facilitate the adaptation, they are advised to perform two localization exercises during the first exercise; the examiner (or a relative at home) sits in front of the patient with his/her hands placed at different distances and positions with reference to the patient and each other. The patient is then asked to use either his/her right or left hand to touch the examiner's right or left hand. The second exercise requires the patient to successively reach and grasp two objects (e.g. two pens) held by the examiner (or relative) at different distances and positions in front of the patient. This second exercise involves fine eye-hand coordination, thus being recommended only when the patient does not experience any difficulty with the first exercise (**Figure 7**).

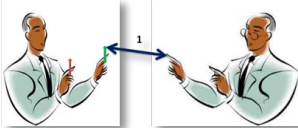
We note that initially have greater difficulty to go get the pen on the side of his hemianopia, notice the spatial displacement of restored vision. Gradually, however, he will learn to make getting accurate locations.

The patients underwent a control at month of use, at six months and then annually, with a follow-up of 2 years.

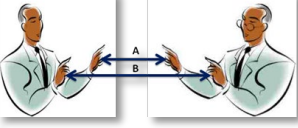
INSTRUCTIONS: EXERCISES OF SPACE LOCATION FOR PATIENTS HEMIANOPIA REHABILITATED © Doctor Fernando-J. Palomar-Mascaró

The therapist must be placed before the hemianopic patient with its new visual aid, and ask:

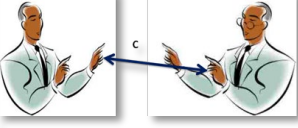
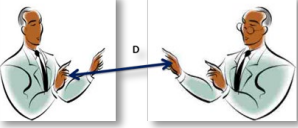
- Touches their hands with the examiner, once on each side.



- Touches their hands with the examiner, once crosswise.

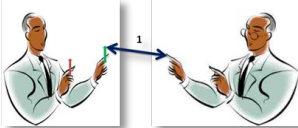


- To take frontally or direction crossed both hands (corresponding to the side of his hemianopia, you will notice the spatial displacement, and gradually will learn precise movements for location).

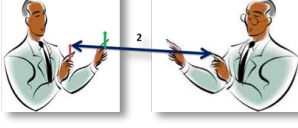



In a second phase, we do exercises, with a higher degree of difficulty. They consist in asking you to take with your fingers the tip of a pencil, the position will go varying, moving horizontally and vertically. We will put a red pen in his/her right hand, and a green one on the left. We ask:

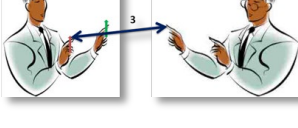
- Take the green pen (same side) with your right hand fingers.



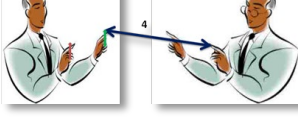
- Take the red pen (same side) with your left hand fingers.



- Take the red pen (opposite side) with your right hand fingers.



- Take the green pen (opposite side) with your left hand fingers.



We note that patients initially have greater difficulty to go get the pen on the side of his/her hemianopia, noticing the spatial displacement of restored vision. Gradually, however, he/she will learn to make accurate locations.

CENTROS PALOMAR
www.centrospalomar.com

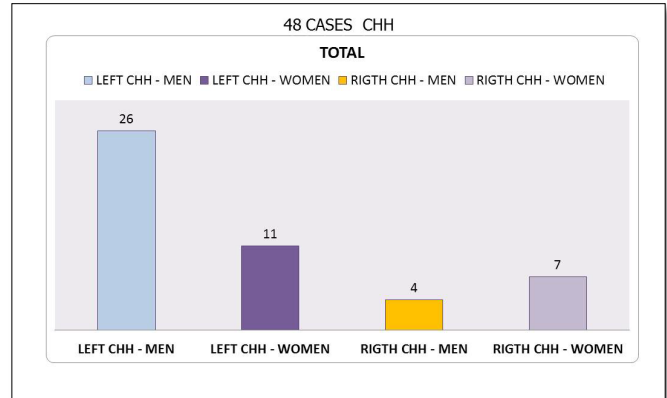
Figure 7. Instructions for the exercises.

RESULTS

48 patients with HHC participated (18 women, 30 men), aged between 18 and 76 years. The etiology of the condition was due to different causes, 11 cases due to primary or secondary neoplasms of the cerebellum (22.92%), 32 due to vascular alterations (66.66%), 3 due to trauma (6.25%), and 2 to inflammatory disorders of the central nervous system (4.17%).

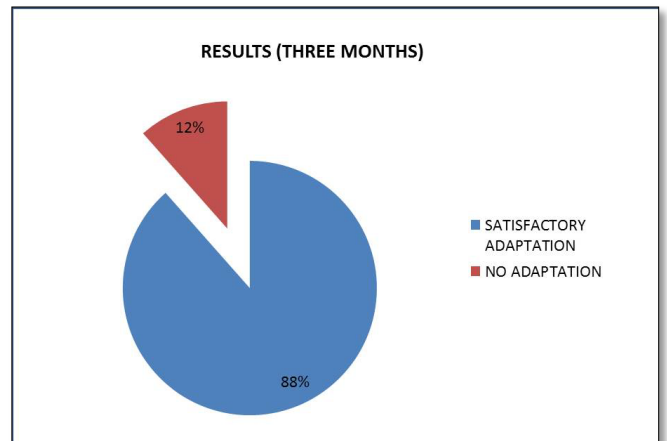
Of the 48 cases, 77.08% presented a complete left HH and a right 22.92%.

Studying the incidence by gender, we have a 54.16% complete homonymous left hemianopia in men, a 22.92% full left HH in women, a 14.58% full right homonymous hemianopia in men and a 8.33% complete right homonymous hemianopia (Graph 1).



Graph 1. Distribution of the chaos of CHH by sex.

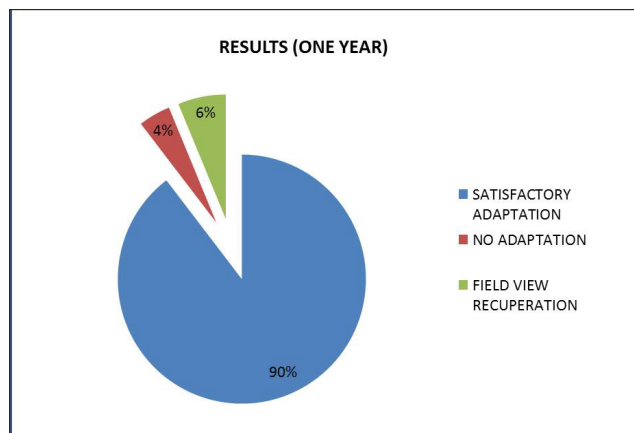
Initially in the three months control, 42 cases (88%) had adapted to the help, in 6 cases (12%) the adaptation was still not satisfactory having become accustomed to the spatial displacement of the restored field (Graph 2).



Graph 2. Results of adaptation to the three months of use.

Regarding the adaptation, in the control of a year, in 43 cases (90%) it was totally satisfactory to the Palomar attached prisms, in two cases (4%) that were not totally satisfactory, they used the aid sporadically throughout the day.

In three cases (6%) that had been adapted, recovery of their central VF field did not require the help should be noted that in none of the controls performed did the patients notice sharpness differences between field, right/left, referring in 46 case (96%) a total restitution of the central field, improving their quality of life (Graph 3).



Graph 3. Results of adaptation to the one year of use.

In no case was exotropia or central scotoma of FoV presented with the binocular prisms.

Regarding the perception of central double vision, or double vision at some point with the help, no patient reported having had it, even in two cases in which the adaptation of the help was not totally satisfactory.

DISCUSSION

A major problem that urgently needs to be addressed by the visual sciences concerns the extent to which rehabilitation and partial restoration of the FoV is possible in patients with CHH. It is also important to determine whether or not the acquisition of compensatory oculomotor strategies by these patients leads to improvement in their performance and normal functioning [19].

Different optical devices have been employed to treat HH patients, either providing a shifting (relocation) or an expansion of the field of view. Although field of view expansion is preferred over relocation, binocular ground-in sectorial prisms only provide image relocation for enhanced peripheral awareness [14]. The effect of binocular sector prisms has been described as being limited [21].

The present study describes the rehabilitation of 48 patients with HHC with binocular Palomar prisms, achieved through precise adjustment of prism power and location getting reduce disability resulting from the loss of FoV, to increase patients' confidence and to facilitate reintegration into their social and professional lives by restoring autonomy [3,19,23].

The objective of the study was to investigate the efficacy of Palomar's attached prisms and to verify whether or not the central diplopia reported by other authors occurred. Prism location is critical to avoid diplopia in primary gaze while allowing objects that would normally fall in the hemianopic field to be relocated to the residual field, thus becoming visible in primary gaze [18,22].

Having never found diplopia or the appearance of an exotropia as other authors refer, we think that it is due to a precise placement of the prisms, and in addition to doing it binocularly, the patient retains has binocular vision, which prevents it from appearing a foria by prismatic decompensating [3].

We consider that prism location and the exact calculation of its power is critical to avoid diplopia in primary gaze while allowing objects that would normally fall in the hemianopic field to be relocated to the residual field, thus becoming visible in primary gaze [17,23].

For it the evaluation of the 10° central field is essential to determine the congruency of the hemianopic lesion, that is, whether the homonymous defects in the fields of both eyes are identical [24], as well as to verify if the lesion follows a straight vertical meridian bisecting fixation between the blind and the normal halves of the visual field [18,23,25].

Our results raise the question of how (i.e., through what monocular mechanisms) such spatial reconstruction may occur. There are two possible scenarios that could explain the results. One explanatory hypothesis is based on the recovery of perception corresponding to the central-part FoV of the lost half-retina. This hypothesis assumes that cerebral neuro plasticity processes are induced in the patient and that this enables recovery of alternative visual processing pathways. One obvious way to test this idea would be to obtain neuro imaging recordings of brain regions involved in processing the target location when it is localized in positions corresponding to the lost FoV [19].

The results of the present study shed some light on the principles underlying the recovery of the visual field in patients affected by CHH. We propose that the main mechanism supporting this rehabilitation is one involving attention and automatic processing of images in the retina. Further research is now required to demonstrate the ability to dissociate automatically two images that are overlapped in the retina.

The three cases in which there was a spontaneous recovery of the visual field, we think that must be due to processes of neuroplasticity, which may have been due to the stimulation that creates the adaptation with the binocular prisms.

CONCLUSION

To conclude, the performance of this study with a large homogenous sample of patients and the results obtained demonstrate the clinical efficacy of binocular Palomar prisms, as a rehabilitation technique, for patients with complete homonymous hemianopia.

According to the results gathered in the present study, it can be asserted that hemianopic patients have the potential to improve their quality of life through rehabilitation procedures and visual aids. Thus, the diffusion of these techniques is of great importance to encourage other

professionals to work in this exciting field, in order to assist patients, who are too often left untreated.

REFERENCES

- Gilhotra JS, Mitchell P, Healey PR, Cumming RG, Currie J (2002) Homonymous visual field defects and stroke in an older population. *Stroke* 33: 2417-2420.
- National Center for Health Statistics (2008) Cerebrovascular disease or stroke. Available at: <http://www.cdc.gov/nchs/fastats/stroke.htm>
- Palomar-Mascaró FJ (2013) Tesis doctoral: Hemianopsias homónimas completas: Estudio de las técnicas de rehabilitación y calidad de vida. Barcelona. Available at: <http://hdl.handle.net/10803/117022>
- Rossi PW, Kheifets S, Reding MJ (1990) Fresnel prisms improve visual perception in stroke patients with homonymous hemianopia or unilateral visual neglect. *Neurology* 40: 1597-1599.
- Smith, JL, Weiner IG, Lucero AJ (1982) Hemianopic Fresnel prisms. *J Clin Neuroophthalmol* 2: 19-22.
- Perlin RR, Dziadul J (1991) Fresnel prisms for field enhancement of patients with constricted or hemianopic visual fields. *J Am Optom Assoc* 62: 58-64.
- Palomar-Petit F. Rehabilitación en las hemianopsias homónimas. *Arch Soc Esp Oftal* 1979; 39: 685-94.
- Gottlieb DD, Allen CH, Eikenberry J, Ingall-Woodruff SJM (1996) Living with vision loss. Atlanta: St. Barthelemy. Press, Ltd.
- Wade DT, Collin C (1988) The Barthel ADL Index: A standard measure of physical disability? *Int Disabil Stud* 10: 64-67.
- Zihl J (1995) Visual scanning behavior in patients with homonymous hemianopia. *Neuropsychologia* 33: 287-303.
- Kasten E, Wüst S, Behrens-Baumann W, Sabel BA (1998) Computer-based training for the treatment of partial blindness. *Nat Med* 4: 1083-1087.
- Cohen JM, Waiss B (1996) Visual field remediation. In: Cole RG, Rosenthal BP, eds. Remediation and Management of Low Vision. St. Louis: Mosby.
- Pambakian ALM, Kennard C (1997) Can visual function be restored in patients with homonymous hemianopia? *Br J Ophthalmol* 81: 324-328.
- Peli E (2000) Field expansion for homonymous hemianopia by optically induced peripheral exotropia. *Optom Vis Sci* 77: 453-464.
- Peli E (2008) Peripheral field expansion device. Patent No.: US 7,374,284 B2. Available from: <https://www.google.com.ar/patents/US7374284>
- O'Neill EC, Connell PP, O'Connor JC, Brady J, Reid I, et al. (2011) Prism therapy and visual rehabilitation in homonymous visual field loss. *Optom Vis Sci* 88: 263-268.
- Palomar-Mascaró FJ, Palomar-Mascaró MV, Cardona G, Quevedo L (2011) Successful rehabilitation of a homonymous hemianopia patient with binocular ground-in sectorial prisms: Considerations concerning prism power and location. *Neuro-Ophthalmology* 35: 138-143.
- Palomar-Mascaró FJ, Palomar Mascaró MV, Quevedo i Junyent L, Palomar-Mascaró L (2011) Study of visual rehabilitation techniques in CHH: Press-on prisms, adjacent Palomar's prisms and lateral-nasal-visor mirror. *Neuro-Ophthalmology* 35: 68-69.
- Palomar Mascaró F, Quevedo Junyent LL, Aznar Casanova JA (2017) Effective visual field rehabilitation in homonymous hemianopia by attaching binocular prisms to lenses. *Am Res J Ophthalmol Optom* 1: 1-11.
- Steinberg EP, Tielsch JM, Schein OD, Javitt JC, Sharkey P, et al. (1994) The VF-14: An index of functional impairment in patients with cataract. *Arch Ophthalmol* 112: 630-638.
- Giorgi RG, Woods RL, Peli E (2009) Clinical and laboratory evaluation of peripheral prism glasses for hemianopia. *Optom Vis Sci* 86: 492-502.
- Woo GC, Mandelman T (1983) Fresnel prism therapy for right hemianopia. *Am J Physiol Opt* 60: 739-743.
- Palomar-Mascaró FJ (2018) Rehabilitation of left homonymous hemianopia with adjacent palomar prism technique and visual therapy on line. *J Intellect Disabil Diagn Treat* 6: 31-35. Available at: <https://doi.org/10.6000/2292-2598.2018.06.02.1>
- Kedar S, Zhang X, Lynn MJ, Newman NJ, Biousse V (2007) Congruency in homonymous hemianopia. *Am J Ophthalmol* 143: 772-780.
- Palomar Mascaró V, Palomar-Mascaró FJ, De Miguel Simó PV, Palomar Mascaró L (2000) Investigación y Actualidad de Ayudas visuales para la rehabilitación de las hemianopsias homónimas laterales completas. *Anales Instituto Barraquer* 29: 79-99.