

## A Non-Extraction Treatment Approach Using Damon Self Ligating Brackets for A Buccally Placed Canine: A Case Report

Athira Muraleedharan<sup>1\*</sup>, Gaurav Sharma<sup>2</sup>, Rashmi Puri<sup>3</sup>, Garima<sup>4</sup> and Rajan Nikumbh<sup>5</sup>

<sup>1</sup>Post Graduate Student, Vyas Dental College and Hospital, Rajasthan University of Health Sciences, India

<sup>2</sup>MDS-Orthodontics, Professor and Head, Vyas Dental College and Hospital, Rajasthan University of Health Sciences, India

<sup>3</sup>Senior Lecturer, Vyas Dental College and Hospital, Rajasthan University of Health Sciences, India

<sup>4</sup>Senior Lecturer, Vyas Dental College and Hospital, Rajasthan University of Health Sciences, India

<sup>5</sup>MDS Orthodontics, Alumni, Vyas Dental College and Hospital, Rajasthan University of Health Sciences, India.

Received July 17, 2023; Revised July 27, 2023; Accepted July 31, 2023

### ABSTRACT

Ectopic canine teeth develop displaced from their normal position and is usually a cause of class I malocclusion. Orthodontic treatment is justified because ectopic canine teeth can migrate in the jaw bone and may damage the adjacent teeth roots and bone. In this article we have presented the case report of a young Indian female treated with a non-extraction treatment plan using Damon self-ligating bracket for correction of buccally placed maxillary canine.

**Keywords:** Ectopic canine, Damon self-ligating brackets, Non-extraction

**Abbreviations:** FMA: Frankfort Horizontal Mandibular Plane Angle; SNA: Sella-Nasion, Point A Angle; SNB: Sella-Nasion, Point B Angle; UI-SN: Upper Incisor, Sella-Nasion Plane; IMPA: Incisal Mandibular Plane Angle; NiTi: Nickel Titanium; CuNiTi: Copper, Nitckel, Titanium

### INTRODUCTION

Ectopic buccally erupted maxillary canines are one of the most frequently encountered conditions in orthodontic practice. The prevalence of permanent maxillary canine impaction or ectopic eruption in the general population is approximately 1-2% [1]. With the advancing technologies in orthodontic practice, brackets, arch wires and other materials have emerged. In the era of variable transformation temperature orthodontics, correction of crowding using extraction modality is not the only option available to orthodontist. Self-ligating brackets have etched their name in the history of orthodontics because of their time saving ability during appointment times, very low friction and increased efficacy of treatment [2]. The Damon System, which uses passive self-ligating brackets in conjunction with complementary Damon Copper NiTi arch wires, is capable of increasing arch width while keeping the teeth perfectly centered in the alveolar bone [3]. Damon braces system is the most popular self-ligating bracket with passive system (Ormoc Corp., 1332 South Lone Hill, Ave., Glendora, CA, USA). It is a passive self-ligating system introduced by Dwight Damon in 1996 (Damon, 2004). Damon talked about a new expansion method provided by the brackets he designed. This method is called "Damon bracket system";

the straight wire technique is based on the principle of using super elastic NiTi wires together with passive self-ligating braces [4].

In this case report we have used Damon Clear 2 Self ligating brackets to correct the buccally erupted maxillary canine without extraction.

### CASE REPORT

A 13-year-old female patient presented with the chief complaint of irregularly placed upper front teeth. No relevant medical and dental history was recorded.

On extraoral examination she exhibited a convex facial

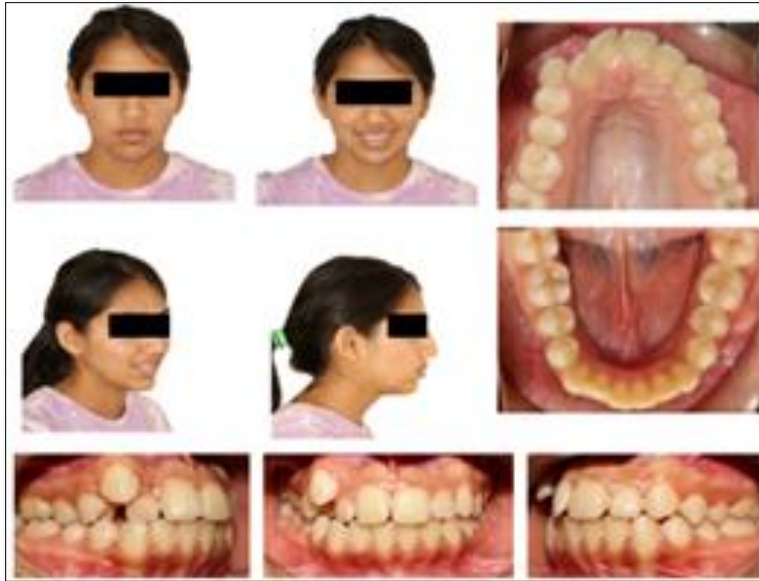**Corresponding author:** Athira Muraleedharan, Post Graduate Student, Vyas Dental College and Hospital, Rajasthan University of Health Sciences, India, Tel: +91- 9074146319; E-mail: athiramurali124@gmail.com

**Citation:** Muraleedharan A, Sharma G, Puri R, Garima & Nikumbh R. (2024) A Non-Extraction Treatment Approach Using Damon Self Ligating Brackets for A Buccally Placed Canine: A Case Report. J Oral Health Dent, 7(1): 585-590.

**Copyright:** ©2024 Muraleedharan A, Sharma G, Puri R, Garima & Nikumbh R. This is an open-access article distributed under the terms of the Creative Commons Attribution License, which permits unrestricted use, distribution, and reproduction in any medium, provided the original author and source are credited.

profile with a posterior facial divergence with a brachycephalic head shape and leptoprosopic facial form, no gross asymmetry, average nasolabial angle, deep

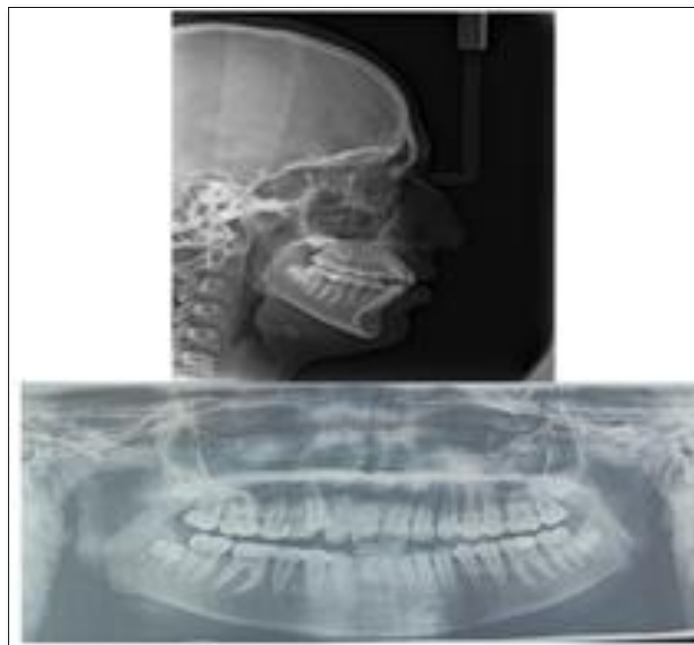
mentolabial sulcus, potentially competent lips (**Figure 1**). TMJ examination shows no history of tenderness, clicking or crepitus on palpation.



**Figure 1.** Pretreatment photographs.

On intraoral examination she had a class I molar relation on both side, Canine relation class I on the left side and not recordable canine relation on right side, lower dental midline shifted 1.5 mm towards left, non-consonant smile with 60% incisal display, overbite of 1mm, overjet of 2mm. Ovoid upper and lower arch forms with buccally placed 13, mild crowding in lower anteriors, mesiolabial rotation of 11, crossbite with 12 & 43 (**Figure 1**).

Cephalometric finding showed skeletal Class I jaw bases with orthognathic maxilla (SNA-83) and mandible (SNB-79), hyperdivergent growth pattern (FMA-32), Proclined maxillary (UI-SN-115) and mandibular incisors (IMPA 104) (**Figure 2**).



**Figure 2.** Pretreatment radiographs.

On Model analysis the Arch length perimeter analysis shows a tooth material excess of 8mm in the upper arch and 4 mm tooth material excess in the lower arch.

#### Problem List

- Crossbite with 12 & 43
- Buccally placed 13
- Crowding in upper and lower arches
- Decreased overbite

#### Treatment Objective

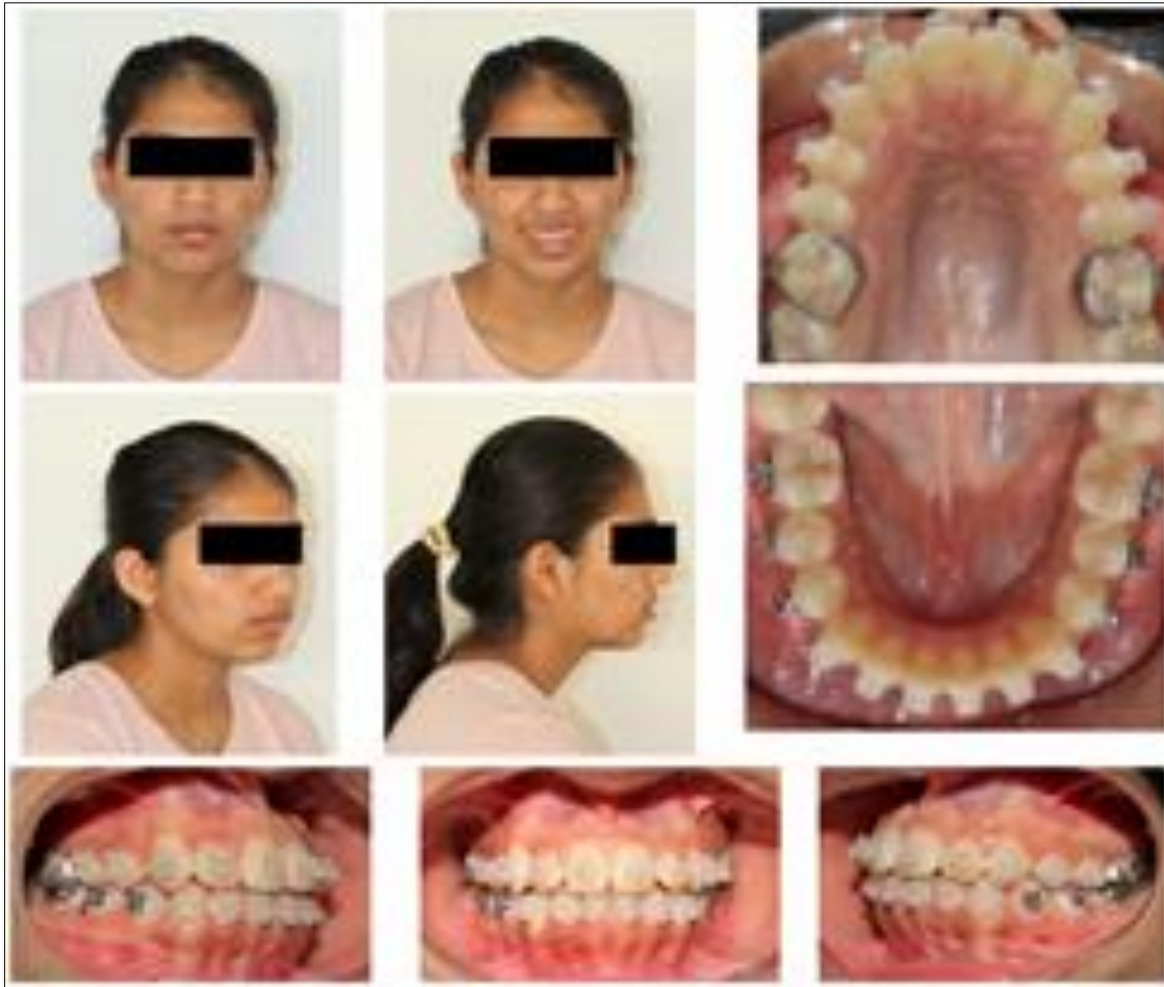- Leveling and aligning the teeth in both the arches.
- Crossbite correction
- Correction of buccally placed 13
- Establishing proper overbite and overjet
- Establish proper occlusion

- Achieve esthetic harmonious profile

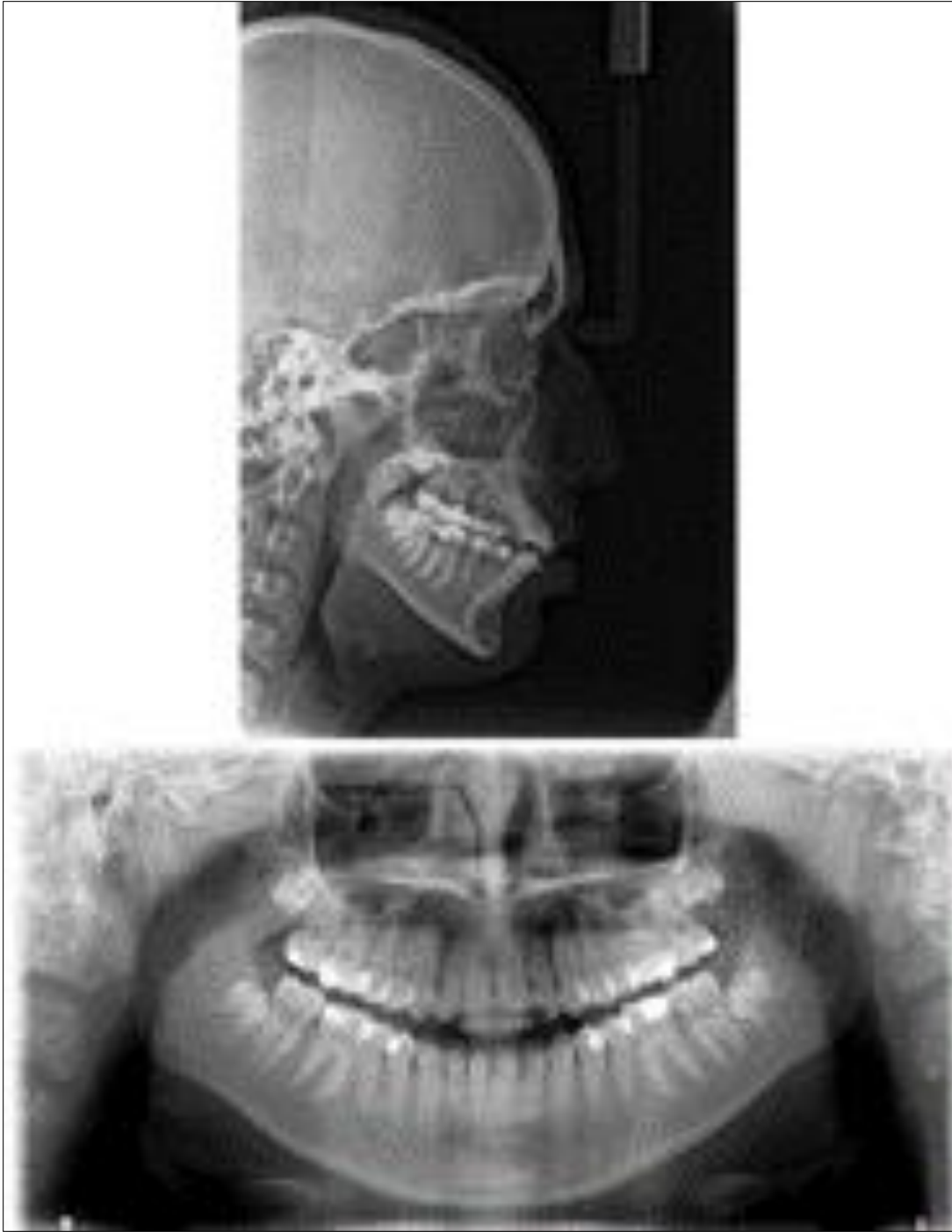
#### Treatment Plan

Appliance used: pre-adjusted edgewise appliance with 0.022-inch slot (Damon TM Clear 2) self-ligating bracket prescription.

For the beginning of arch form development and initial leveling, 0.013-inch light round copper NiTi wires were used in both upper and lower arches (4 months) (**Figure 3**). Further, 0.014 × 0.025-inch copper NiTi, a great transition wire was used (3 months). Later, 0.018 × 0.025-inch copper NiTi wire was used which is an excellent wire to prepare for insertion of the working rectangular stainless-steel transition wire (2 months). For maintaining the integrity of the arch, 0.019 × 0.025-inch SS wires were used during anteroposterior correction and final settling (4 months). Interproximal reduction was carried out in the upper and lower anterior during the working phase to reduce the incisor proclination (**Figure 4**).



**Figure 3.** Mid treatment Photographs.



**Figure 4.** Mid treatment Radiographs.

#### **TREATMENT RESULT**

In this case, buccally placed maxillary canine was corrected using DAMON™ Clear 2 self-ligating bracket system. Class I molar and canine relationship was achieved with 2 mm of overjet and 2 mm of overbite. The comparative cephalometric evaluation showed that SNA was decreased

by 2° and SNB angle was reduced by 1° showing a stable Class I skeletal base (**Figure 5**). No significant changes were seen in facial divergence. Upper Incisor proclination reduced by 6°, lower incisor proclination reduced by 8°. Favorable esthetic profile was achieved even with the non- extraction treatment modality. (**Figure 6, Table 1**).

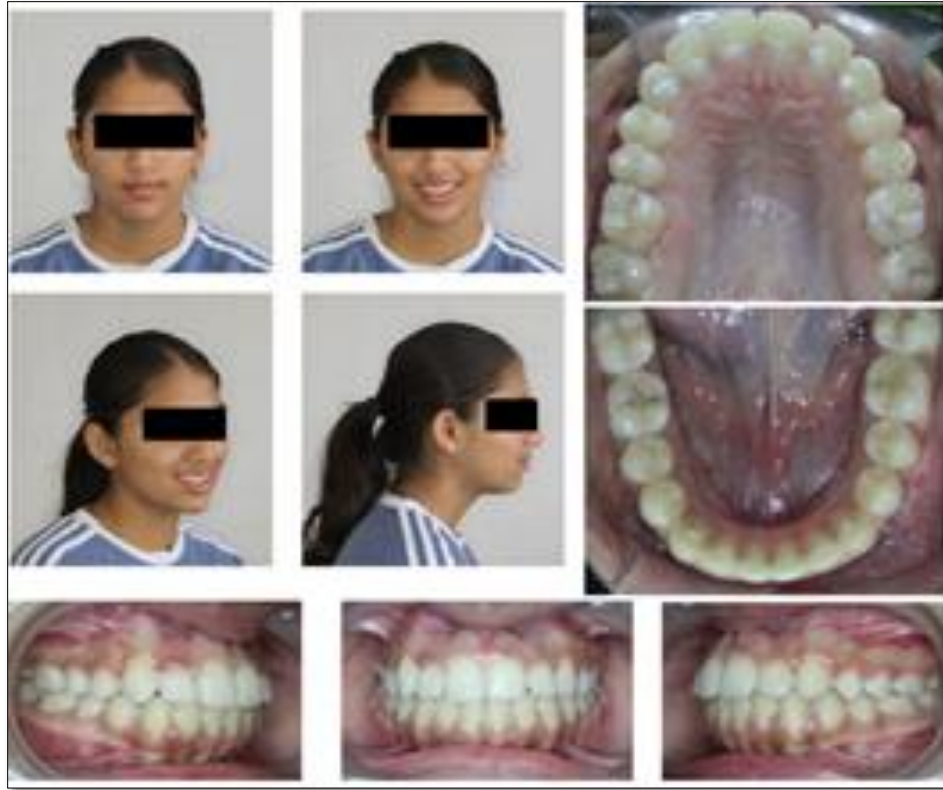

Figure 5. Post treatment Photographs.

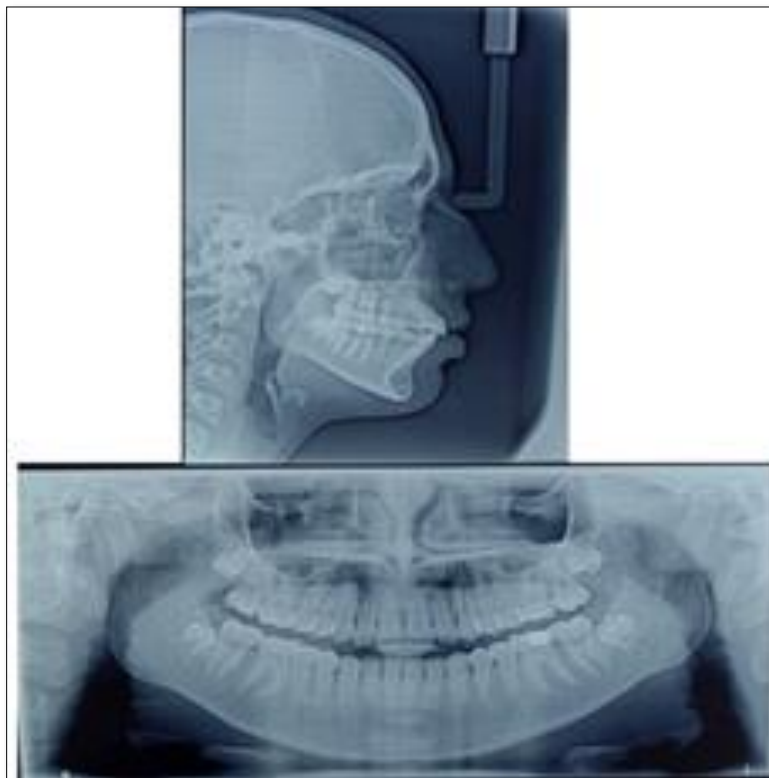


Figure 6. Post treatment Radiographs.

**Table 1.** Pre and Post Cephalometric Value.

Parameters	Pre-treatment	Post-treatment
SNA	83	80
SNB	79	78
ANB	4	2
Wits (AO-BO)	1mm	0mm
UI-SN	115	109
IMPA	107	99
FMA	32	32
Nasolabial angle	112	106
Mentolabial sulcus	117	118

## DISCUSSION

Buccally placed maxillary canines are commonly seen in practice. The usual treatment plan suggested for such cases are extraction of premolar in tooth material excess. But the patient insisted on a non-extraction approach due to which Damon self-ligating bracket was used to utilize its property of arch development. The space for a buccally placed canine can be obtained by expansion of maxillary arch, proclination of incisors or extraction of premolars [1].

Compared with conventional pre-adjusted edgewise appliances, it is suggested that the use of passive self-ligation results in a significant reduction in the need for extractions to facilitate orthodontic mechanics because alignment is not hindered by frictional resistance from ligatures and can therefore largely be achieved with small diameter copper nickel titanium arch wires [5]. Damon system creates natural strength systems compatible with normal growth and development in every phase of treatment. Damon believes that posterior expansion causes the tongue to be positioned above and further back, allowing a new balance with the cheeks and lips. This expansion causes an increase in arch length. Damon thinks that during the development of this new balance, the teeth will expand physically. While the mechanics of the Damon bracket system enable expansion, this new balance also provides the stability of the expansive arch [6]. In our cases, this expansive effect of the Damon system was used to gain space. In the Damon system, the treatment time is shorter than the traditional treatment method, and fewer appointments are required during the treatment. Our case was completed in a span of 1.1 year with good occlusion achieved. The final results showed an esthetically favorable profile.

## CONCLUSION

Damon self-ligating brackets can be taken as a valuable type of bracket system to achieve a good treatment outcome for non-extraction treatment plan. In our case we have achieved a good occlusion with favorable esthetic profile and patient satisfaction. For ectopic eruptions and mild to moderate crowding self-ligation brackets can be of choice to preserve all teeth.

## REFERENCES

1. Sachan A, Chaturvedi TP (2012) Orthodontic management of buccally erupted ectopic canine with two case reports. *Contemp Clin Dent* 3(1): 123.
2. Shyamali TR, Doshi J (2018) Correction of Severely Crowded Lower Anterior Teeth Using Self-Ligating Bracket System: A Case Report. *Iran J Orthod* 13(1): e9472De.
3. Lima DV, Freitas KM, De Freitas MR (2020) No extraction Treatment of Severe Crowding with a Self-Ligating Appliance. *J Clin Orthod* 54(12): 765-762.
4. Buyukcavus MH (2021) Non-extraction Orthodontic Treatment with Damon System: Two Case Reports. *Black Sea J Health Sci* 4(1): 44-47.
5. Birnie D (2008) The Damon passive self-ligating appliance system. In: *Seminars in Orthodontics*. Philadelphia, PA: WB Saunders; Vol: 14; pp: 19-35.
6. Damon D (2004) *Damon system: the workbook*. Orange County, CA, USA.