

## Evaluation of Anesthetic and Analgesic Effect of Hematoma Block for Distal End Radius Fracture Reduction

Nayna Solanki<sup>1\*</sup>, Shilpin Solanki<sup>2</sup>, Pooja Patel<sup>1</sup>, Kaushal Kalotra<sup>3</sup> and Hiral Solanki<sup>3</sup>

<sup>1</sup>Department of Anesthesia, GCS Medical College, Naroda, Ahmedabad, Gujarat, India

<sup>2</sup>Department of Anesthesia, GMERS Medical College, Dharpur-patan, Gujarat, India

<sup>3</sup>Department of Anesthesia, GCSMCH & RC, Gujarat, India.

Received November 26, 2019; Accepted December 11, 2019; Published April 26, 2020

### ABSTRACT

**Background:** Distal radius fractures are the most common orthopedic injury, It accounts for 17.5% of all fractures in adults, more common in females (male:female=2-3:1).

**Aim:** Treatment is based on fracture pattern and stability. The most common method of management is closed reduction and immobilization. The aim of the study is to evaluate the aesthetic and analgesic effects of hematoma block for closed reduction of distal radius fracture reduction.

**Materials and methods:** After ethical committee approval a prospective observational study was carried out among 60 patients of age >15 and <60 years of either sex who had fracture distal radius. The patients having multiple fractures, pathological fractures and those who were allergic to local anesthesia drugs were excluded from the study. After taking informed written consent, reduction of fracture was done following after infiltration with 2% lignocaine into fracture hematoma site. Pain score was compared by VAS before, during and after manipulation. Time of onset and duration of analgesia is noted.

**Results:** 60 patients of mean age 55.1 years, male: female 28:32 with fracture distal radius were studied. Mean time from admission to fracture reduction was 2.05 h. Mean time for onset of analgesia is 5 min. Discharge time from hospital after reduction of fracture 2.0 h. Average VAS during reduction was 0.94. VAS 10 min after reduction VAS was 0.20.

**Conclusion:** For closed reduction of distal radius fracture, hematoma block with lignocaine is safe and effective alternative to other form of anesthesia.

**Keywords:** Distal end radius fracture reduction, Hematoma block

### INTRODUCTION

Distal radius fractures are the most common fracture of the upper extremity with bimodal peak incidence in both the pediatric and elderly population [1]. Manipulation of a displaced distal radius fracture is routinely performed in the Emergency Department (ED). This manipulation is performed using a variety of anesthetic techniques, such as hematoma block (HB), intravenous block (Bier block), general anesthesia and nerve block. Each of these methods has potential complications and may also result in inadequate anesthesia, analgesia and/or muscle relaxation, which could compromise the treatment process and results. Adverse drug reactions could also result from any of the agents used [2,3]. The hematoma block is a technique to inject a local anesthetic solution into the hematoma between the fractured bone fragments. Fracture manipulation can then often be undertaken painlessly or with significantly

reduced pain. Hematoma blocks of the distal forearm are considered safe in children and adults. It is very simple alternative method of providing rapid pain relief during reduction of distal radius fracture, easy to perform, readily available. Its potential benefits include avoidance of procedural sedation analgesia-associated risks, high cost-effectiveness and time-sparing procedure. The disadvantages

**Corresponding author:** Nayna Solanki, Assistant Professor, Department of Anesthesia, GCS Medical College, Naroda, Ahmedabad, Gujarat, India, Tel: 9624163313; E-mail: drnaynasolanki@gmail.com

**Citation:** Solanki N, Solanki S, Patel P, Kalotra K & Solanki H. (2020) Evaluation of Anesthetic and Analgesic Effect of Hematoma Block for Distal End Radius Fracture Reduction. Int J Anaesth Res, 3(1): 99-103.

**Copyright:** ©2020 Solanki N, Solanki S, Patel P, Kalotra K & Solanki H. This is an open-access article distributed under the terms of the Creative Commons Attribution License, which permits unrestricted use, distribution, and reproduction in any medium, provided the original author and source are credited.

of the hematoma block include the discomfort and anxiety resulting from injecting into the fracture site and risk of local anesthetic toxicity.

### AIM

To evaluate hematoma block as a method of anesthesia for distal end radius fracture reduction to identify the level of pain relief, frequency of adverse effects and reduction failure.

### MATERIALS AND METHOD

It is a prospective randomized cross-sectional study performed in 60 subjects who presented at GCS Medical College Hospital and Research Centre within a day or two of injury with distal end radius fracture in a year 2017-2018.

#### Inclusion criteria

Patient of age group 15-60 time of presentation within 48 h of injury.

#### Exclusion criteria

Age group <15 and >60 years delayed presentation pregnancy patients with other injuries requiring GA history of cardiorespiratory disease history of seizures.

This was prospective cross sectional study done in 60 patients of 15 to 60 years age group and either sex posted for distal end radius fracture reduction in a year 2017-2018. After taking written informed consent patients were taken inside operation theatre. All patients were evaluated for Pre anesthetic checkup. 22 g intacath taken. Parameters like pulse, blood pressure, SpO<sub>2</sub> observed and noted.

A hematoma block is an analgesic technique used to allow painless manipulation of fractures while avoiding the need for full anesthesia. This procedure is normally only appropriate for fractures of the radius and ulna and occasionally for fractures of the lower ends of the tibia and fibula.

#### Steps

After proper aseptic precaution a 22 g 1.5 inch needle inserted into the fracture site from the dorsum and then aspirated to confirm the presence of hematoma 10 ml of 2% lignocaine is injected. Maximum dose that can be given is 5 mg/kg the time for latency is noted and the effectiveness was evaluated by visual analog score (VAS) after 10-15 min, closed reduction with casting is performed.

Patients were followed for 1 h after procedure to observe side effects.

The time till wean off of the effect was noted.

### RESULTS

Out of 60 patients, mean age was 55.1 years, male:female ratio was 28:32. Mean time from admission to fracture reduction was 125 min. Mean time for onset of analgesia is 5 min. Discharge time from hospital after reduction of fracture 120 min. Average VAS during reduction was 0.94. 10 min after reduction VAS was 0.20. As it's a day care procedure, mean discharging time was 125 min.

**Table 1** shows age distribution of patients and **Table 2** shows gender distribution of patients.

**Table 1.** Age distribution.

20-40 years	18
40-60 years	30
60-80 years	12

**Table 2.** Sex distribution.

Male	28
Female	32

All 60 patients were discharged within 2 h of hematoma block (**Table 3**).

**Table 3.** Time taken from admission to reduction and reduction to discharge of patients.

Time	Admission to reduction (No. of patients)	Reduction to discharge (No. of patients)
<30 min	10	6
30 min to 1 h	16	10
1-2 h	34	44
>2 h	0	0

22 out of 60 patients had analgesia within 5 min of hematoma block (Table 4).

Table 4. Onset of analgesia.

Time	0-5 min	5-10 min	10-15 min	15-20 min
No. of Pts.	4	22	26	8

Average faces scale pain rating scale was 1 (Table 5).

Table 5. Face's pain rating scale.

Scale	0	1	2	3	4	5
No. of Pts.	18	20	10	6	4	2

14 patients had 3 VAS score and 8 patients had 1 VAS score (Figure 1).

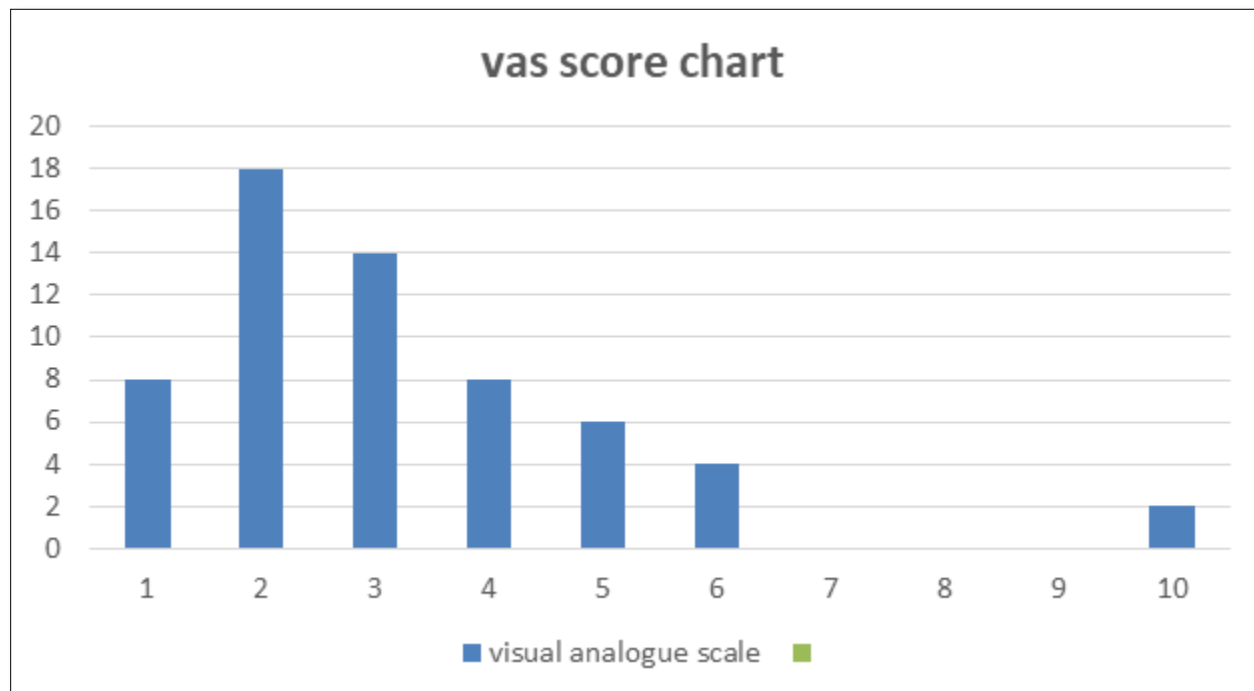


Figure 1. Chest X-ray showing a disappearance of the left diaphragmatic dome.

**DISCUSSION**

Pain control is achieved by different methods in patients with distal radius fracture reduction referring to emergence departments to receive analgesia for manipulation and fixation. Regarding background diseases, general anesthesia is accompanied by concerns about its side effects. Evaluation and comparison of various methods have been performed in previous studies on people with distal radius fracture, but elderly people are of special importance.

Analgesia method which is easy, efficient and requires short hospitalization is especially important for the elderly. There are concerns about the safety of analgesia methods. There is as much chance of infection, local anesthetic toxicity, and

compression by volume of local anesthetic leading to compartment syndrome. Thus, little attention has been paid to hematoma block. However, the probability of such events is very low.

But no complication was observed in the patients studied in our study. Depending on the type of treatment including reduction and percutaneous fixation, these adverse effects are likely to occur in patients under general anesthesia. Except for the blood toxicity by Lidocaine, the other side effects are not dedicated to hematoma block anesthesia [4].

Efficacy of hematoma block in reducing Colles' fracture was studied by Kendall et al. [5] in which an increasing awareness of cost and time within the National Health

Service contributes to a marked change in the aesthetic management of Colles' fractures and demonstrates the increasing popularity of the hematoma block compared with 5 years ago.

Singh et al. [2] studied about analgesia for reduction of Colles' fracture by double blind randomized comparative study between conventional sedation and hematoma Group. Sixty six out of 80 consecutive cases with the fracture were studied.

Pain scores during reduction in the Xylocaine group (i.e., Hematoma Group) were acceptably low, that is <3 (median=1.8) as compared to the unacceptably high, that is >3 pain scores in the conventionally practiced sedation group (median=8.7), at a very high level of clinical and statistical significance.

Therefore they concluded that hematoma block by local anesthesia is a safe and effective alternative to sedation in reduction of Coles' fracture. This sole study favors the hematoma block for the reduction in distal radial fractures [5]. A meta-analysis conducted included 18 studies with 1200 patients regarding different anesthetic methods for manipulation of displaced distal radius fractures reduction. They concluded that there was some indication that HB was a poorer analgesic effect than other methods [6-10].

Found the preferred method for manipulating displaced distal radius fractures is HB because of its simplicity and availability. Unfortunately this procedure is painful for few of their patients [11-13]. One more study done by Gaur and Kachhawah [14] for closed reduction of distal radius fracture concluded that hematoma block with lignocaine is safe and effective alternative to other form of anesthesia raised concerns still over the complications including pain at the tourniquet site, local anesthetic toxicity and instant recurrence of pain at surgical site following tourniquet deflation and the serious dangers of leakage of anesthetic after accidental deflation of the tourniquet in their study. They also stated that anesthesia with Hematoma Block, instead of Procedural Sedation Analgesia, is beneficial for maintaining the effect of pain relief after fracture reduction. In the pediatric patients, treatment by Hematoma Block also revealed less pain severity compared with that by Procedural Sedation Analgesia. Additionally, the adult patients treated by PSA suffered most adverse effects, including nausea, vomiting and respiratory distress [8]. However, numerous studies have suggested Hematoma Block as the treatment of choice over general anesthesia because of its simplicity and safety and reduced need of narcotics for postoperative pain relief [9]. Ogunlade et al. [9] studied reduction of the fracture under hematoma block using 10 ml of 2% lignocaine on 35 patients who presented in the Accident and Emergency Department of University College Hospital with displaced distal radial fracture between January 2000 and March 2001. There was significant reduction of the pain following infiltration of the fracture site with lignocaine and

during manipulation. All the patients had satisfactory reduction of the fracture. The fracture was mobilized in Plaster of Paris 6 weeks in patients with Colleens' fracture and 3 weeks in patients with distal radial epiphyseal injury. All patients had good range of movement at 8 weeks after removal of Plaster of Paris and patients expressed satisfaction with this method. They recommended the use of Hematoma block for patients of 15 years and above with displaced distal radial fracture reduction in the Accident and Emergency Department [10]. Another study also demonstrated pain lowering effect of hematoma block for close reduction of distal radius fractures [11]. Suraj et al. [10] studied hematoma block versus brachial plexus block and stated that hematoma block can be used and is very useful in managing fractures like isolated radius or ulna fracture, minimally displaced fracture demonstrated that the pain of local anesthetic administration can be dramatically reduced by buffering the local anesthetic prior to its infiltration. They found significantly increased patient acceptance without compromised anesthetic efficacy [13]. During hematoma block by infiltration, the close fracture maybe converted to an open fracture giving way for the entry of microorganisms thereby causing infection. Johnson and Noffsinger [11] revealed no incidence of infection in either group in their study. So, if appropriate precautions are taken, hematoma block does not increase the risk of infection [14]. Similarly in our study, we did not witness any such complication, which could be because of strict aseptic protocol being followed [15].

#### LIMITATIONS

Because of small sample size we could not find incidence of infection, so further study with large volume required to study rate of infection in hematoma block.

#### CONCLUSION

We conclude that hematoma block for reduction of distal fracture radius is a safe, simple, easily available and effective alternative to other type of anesthesia. It also has advantage of causing lesser side effects, which enables early discharge of patients from hospital.

#### REFERENCES

1. Alluri RK, Hill JR, Ghiassi A (2016) Distal radius fractures: Approaches, indications and techniques. *J Hand Surg Am* 41: 845-854.
2. Singh B, Singh S, Singh GK, Singh M, Bajracharya T (2008) The efficacy of the hematoma block for fracture reduction in the distal forearm fractures: A double blind randomized controlled trial. *Int J Anesthesiol* 17: 1-7.
3. Graham CA, Gibson AJ, Goutcher CM, Scollon D (1997) Anesthesia for the management of distal radius fractures in adults in Scottish hospitals. *Eur J Emerg Med* 4: 210-212.

4. Handoll HH, Madhok R, Dodds C (2002) Anesthesia for treating distal radial fracture in adults. *Cochrane Database Syst Rev* 3.
5. Kendall JM, Allen P, Younge P, Meek SM, McCabe SE (1997) Hematoma block or Bier's block for Colles' fracture reduction in the accident and emergency department - Which is best? *J Accid Emerg Med* 14: 352-356.
6. Orbach H, Rozen N, Rinat B, Rubin G (2018) Hematoma block for distal radius fractures - Prospective, randomized comparison of two different volumes of lidocaine. *J Int Med Res* 46: 4535-4538.
7. Tseng PT, Leu TH, Chen YW, Chen YP (2018) Hematoma block or procedural sedation and analgesia, which is the most effective method of anesthesia in reduction of displaced distal radius fracture? *J Orthop Surg Res* 13: 62.
8. Tabrizi A, Mirza Tolouei F, Hassani E, Taleb H, Elmi A (2017) Hematoma block versus general anesthesia in distal radius fractures in patients over 60 years in trauma emergency. *Anesth Pain Med* 7: e40619.
9. Ogunlade SO, Omololu AB, Alonge TO, Salawu SA, Bamgboye EA (2002) Hematoma block in reduction of distal radial fractures. *Afr J Med* 21: 282-285.
10. Suraj B, Tamanna B, Sriraj S (2018) Hematoma block for fracture reduction. *J Soc Surg Nepal* 21.
11. Johnson PQ, Noffsinger MA (1991) Hematoma block of distal forearm fractures. Is it safe? *Orthop Rev* 20: 977-979.
12. Afsar SS, Idrees M, Gulzar M (2014) Pain lowering effect of hematoma block for close reduction of distal radius fractures. *Gomal J Med Sci* 12: 1-4.
13. Christoph RA, Buchanan L, Begalla K, Schwartz S (1988) Pain reduction in local anesthetic administration through pH buffering. *Ann Emerg Med* 17: 117-120.
14. Gaur TNS, Kachhawah V (2017) Reduction of distal radius fractures under hematoma block. *Biomed J Sci Tech Res* 1: 1780-1782.
15. White JS (2013) Fractures of the distal radius. *Adv Emerg Nurs J* 35: 8-15.