

## Plant Foreign Bodies into Orbit with Complications

Duong Dieu \*

\*Faculty of Medicine, Nguyen Tat Thanh University, Ho Chi Minh City, Vietnam.

Received July 15, 2019; Accepted August 29, 2019; Published November 06, 2019

### ABSTRACT

Two plant foreign bodies into the orbit were reported: One was diagnosed lately and this extracted foreign body on the 24<sup>th</sup> day of onset. The other was extracted the foreign body on the 22<sup>nd</sup> day of onset. Some considerations on prevention, on primary eye care, paraclinical and clinical features, medical and surgical treatments were discussed especially for helping medical doctor in district hospital level.

**Purpose:** Report of two cases of plant foreign body:

- A branch of eucalyptus tree is perforated into the lower eyelid, next to the globe complicated orbital abscess and diplopia. This case was diagnosed and was operated for removing of the foreign body on day 24<sup>th</sup> from onset.
- A twig which is perforated the upper eyelid complicated orbital abscess and ptosis was delayed 3 weeks from the onset because of closed unhealed wound. The surgery of removal foreign body on day 22<sup>nd</sup> from onset and improve complications.

**Design:** Report of two cases of clinical diagnosis and intervention.

**Diagnosis:** Main measures: clinical signs, paraclinical and patient's history.

**Paraclinical:**

- X-ray: No sign is detected as twigs did not opacity in X-ray.
- Ultrasound: Showed foreign bodies in the orbit, but does not specify the shape, the size of the object.

**Diagnosis:**

- Case 1: Foreign body into the orbit through lowerlid caused abscess and diplopia
- Case 2: Foreign body into the orbit through upper lid caused abscess and ptosis.

**Interventions: Surgery and results:**

Case 1: Foreign body into the orbit through lower lid.

On day 24<sup>th</sup> since foreign body into the eye: Local anesthesia and conjunctiva. Surgical exploration was performed by through wounded site extending along the outer eyeball, in positions 3-4 O' clock, freeing abscess pus. After pus cleaning, strabismus hook was used for detecting foreign body that is located directly beneath the lower rectus muscle, stabbed in the globe and orbit. Then the foreign body was extracted by strabismus hook. Foreign objects is a twig tree with size: 5 mm (diameter) × 15 mm (length). One week after surgery: the abscess collapse, decreased conjunctiva hyperemia, less bruising lid, no diplopia. Three weeks after the removal of foreign right eye completely back to normal, vision 1/10, IOP 17 mm Hg.

Case 2: Foreign body into the orbit through upper lid.

On day 22<sup>nd</sup> since foreign body into the eye: Patients with moderate ptosis with lid slit 25 mm, tumor on lower lid with 5 mm (diameter) × 10 mm (length). Local anesthesia. Abscess liberation to remove pus and foreign bodies. Foreign body is a dry tree twig with size 5 mm (diameter) × 10 mm (length). One week after surgery: lid slit 4 mm, 8 mm 2 weeks: 2 eyes open near normal.

**Conclusion:**

1. The initial management and closely monitor patients every day has an important role to remove the foreign bodies as soon as possible, to minimize complications contribute to the success of treatment.

**Corresponding author:** Duong Dieu, Faculty of Medicine, Nguyen Tat Thanh University-Ho Chi Minh City, Add 300A NguyenTatThanh Street- Dist 4- HCM City, Vietnam, E-mail: duongdieumd@gmail.com

**Citation:** Dieu D. (2019) Plant Foreign Bodies into Orbit with Complications. Int J Surg Invasive Procedures, 3(2): 115-118.

**Copyright:** ©2019 Dieu D. This is an open-access article distributed under the terms of the Creative Commons Attribution License, which permits unrestricted use, distribution, and reproduction in any medium, provided the original author and source are credited.

2. Patients with complications and delay in hospital admission and whether did not find any traces of foreign bodies or not:
  - Careful detail patient's history object is especially small sized such as twigs of tree.
  - Combining the clinical signs: deeply abscess orbit, using strong pressing on the wound to detect the pus out, hyperemia of conjunctivitis, diplopia, ptosis...after trauma.
3. Perform surgery for abscess debridement as well as detect foreign body helping remove foreign bodies sooner with results expected.

**Keywords:** Plant foreign body, Orbital abscess, Ptosis, Diplopia, Surgical treatment

## INTRODUCTION

Penetrating eye injuries due to foreign body often cause serious damage to the eyes and vision. In the case of contrast object can be determined by x-rays [1]. In the case of object cannot be determined by x-rays, ultrasound image [2,3], computerized tomography (CT) can be used to confirm [4]. The treatment consists of surgical removal of foreign body, damage recovery and medical treatment of complications such as infection [5,6]. The initial management is removed of foreign intervention as soon as possible to minimize complications. In most of the cases the patient with plant foreign body into orbit to delay in hospital admission cannot be diagnosed by x-ray need to be closely monitored to avoid forgotten foreign body. These are contributing to the success treatment [6-8].

Two cases of plant foreign bodies were reported in this paper.

## CASES REPORT

### Case 1: RE=Foreign body into orbit through lower lid [8]

Three weeks ago, a 64 year old male patient, farmer, while working to cut eucalyptus trees and suddenly a dry tree twigs snapped and crashed heavily in his right eye. Patients with bleeding in the eye and was taken to an eye specialist for treatment locally. According to the family of the patient, this staff can get here is a very small piece of branch tree (twig) from patient's eye and medical treatment for more than 2 weeks. During this time the patient's condition did not reduce that tend to increase such as: touching the lower eyelid a tumors with tenderness, pus through the wound hole intermittent then continuous, visual acuity blurred, diplopia relief but patient's feeling was more uncomfortable. Patient had seeked himself referral to treatment.

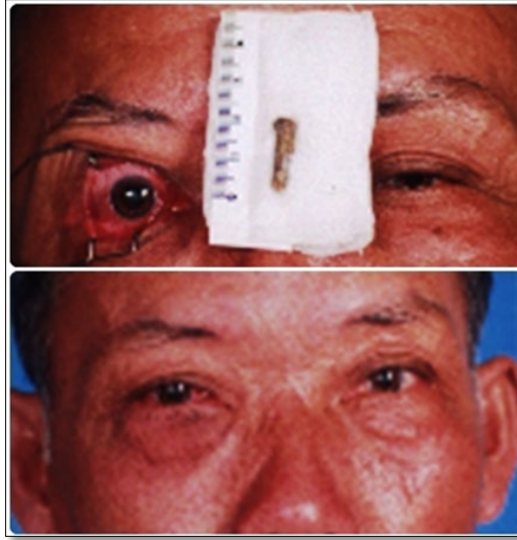
**Examination:** Right eye: Visual acuity 1/10, intraocular pressure 17 mm Hg (Schiotz). Upper lid: normal, lower lids:

a bruise wound at the 1/3 corners of the nose lid with a hard tumor, about 2 mm in diameter, pressing against the yellow pus appeared through the wound hole. The conjunctiva was intact. There was not any traces of foreign bodies in the conjunctiva. Oculomotor: movement somewhat limited and diplopia. The pupil was 3 mm in diameter, round, regular, direct light reflex (+). The anterior chamber and crystalline lens were clear. Fudus examination was normal. Left eye: Visual acuity 3/10, intraocular pressure 17 mm Hg. Oculomotor: normal. The other part of the eye was normal. X-ray: no sign is detected [1]. Ultrasound: A wave showed for strange body, but does not specify the shape, the size of the object [2,3].

**Diagnosis:** RE= Foreign body into orbit through lower lid caused abscess and diplopia complications.

**Treatment:** Ciprofloxacin 500 mg × 2/day-combined methylprednisolone 16 mg/day for 1 week.

**Surgery:** Day 24<sup>th</sup> since foreign body into the eye: Local anesthesia and conjunctiva. Surgical exploration by an incision extending hole along the outer wall of the eyeball, in positions 3-4 O' clock, freeing abscess pus was done. After pus cleaning clearly, strabismus hook was used to detecting foreign body that was located directly beneath the globe, the lower rectus muscle. Then this foreign body was extracted by hook through this hole. From the mouth hole to located foreign object is about 25 mm. Foreign object is a dry twig of tree with size, size: 5 mm diameter, 15 mm length. After surgery a week: abscess collapse, less conjunctival hyperemia, less bruising eyelid, no diplopia. Three weeks after the removal of foreign body the wound was healed. By 3 weeks after treatment right eye completely back to normal, vision 1/10, IOP=17 mm Hg (**Figure 1** and the patient's right eye).



**Figure 1.** F1=Preop=Diplopia. RE= Plant foreign body 5 × 15 mm.

**Case 2: LE=Foreign body into the orbit through upper lid**

Three weeks ago, a 34 year old male patient while working he had fallen and a twig of dry coconut tree had suddenly perforated into the orbit through upper lid of his left eye. The patient visited at the health village station several times with chief complain: the eye lid dropping and difficult to open and an unsealed wound with pus while pressing. Patient was sent to eye doctor after 3 weeks from here. On the eye examinations: Patients with moderate ptosis, lid slit 25 mm - tumor size = 5 mm diameter. Visual acuity RE = 10/10-LE = 10/10 but feel uncomfotable in daily activities because of ptosis. X-ray: no sign is detected [1].

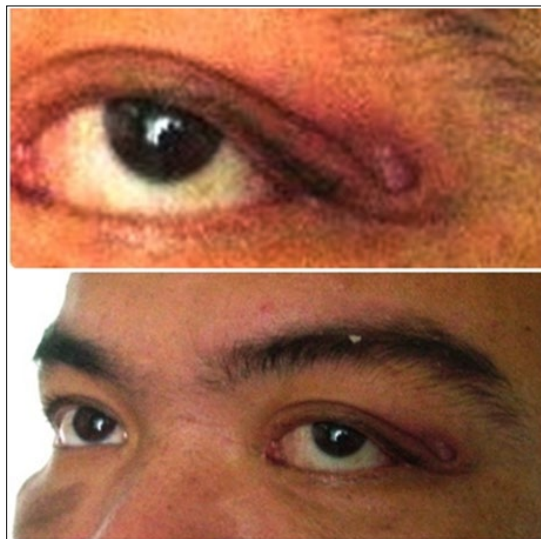**Ultrasound:** A wave showed for strange body, but does not specify the shape, the size of the object [2,3].

**Diagnosis:** LE= Foreign body into orbit throught upper lid caused abscess and moderate ptosis complications.

**Treatment:** Antibiotics: Ciprofloxacin 500 mg × 2/day combined methylprednisolone 16 mg/day for 1 week [5-7].

**Surgery:** Local anesthesia eyelid. An incision through the tumor 12 mm was opened and a strabismus hook was used for detecting foreign body. After abscess debridement, a foreign body located at internal rectus muscle and was removed by this hook. The depth position of foreign body was about 22 mm. Foreign body is a dry branch of coconut with size 5 mm × 10 mm.

One week after surgery: lid slit=4 mm, no diplopia. 2 weeks latter: lid slit=8mm and both eyes open normally (**Figure 2** and the patient's left eye).



**Figure 2.** F2=LE=Mild ptosis. Foreign body 5 × 10 mm.

**PREVENTION**

Two cases are accidents of working without wearing glasses for protecting eyes because of famers living in rural area.

It is recommended to wear safety spectacles in work as it is necessary to minimize this accident.

**CONCLUSION**

- The initial management and close monitoring of patients each day with the foreign body into the orbital eye have an important role in order to remove the foreign as soon as possible, to minimize complications contribute to the success of treatment.

- In case of the patient came lately with complications: Take carefully the patient’s history as well as using paraclinical signs must be necessary for confirm foreign body. In the case of object is twig of tree, x-ray is not useful, a combination of clinical signs and a probe of ultrasound may be useful in diagnosis.
- Perform abscess debridement and liberate pus as well as to remove foreign bodies with results expected (**Table 1**).

**Table 1.** Some characteristics of patients on the hospital admission.

	Days before admission	Clinical presentation	X-ray	Ultrasound	Pus culture and antibiogram	Antibiotics + Anti-inflammatory
Case 1	24	Orbital abscess Diplopia	(-)	(+)	Bacteria Gram (-) Sensitive to ciprofloxacin	Ciprofloxacin 500 mg × 2/day plus Methylprednisolone 4 mg × 4/day
Case 1	22	Orbital abscess Moderate ptosis	(-)	(+)	Bacteria Gram (-) Sensitive to ciprofloxacin	Ciprofloxacin 500 mg × 2/day plus Methylprednisolone 4 mg × 4/day

**REFERENCES**

1. Lloyd G (1987) Radiology and the orbit. In: Clinical Ophthalmology. Wright: Bristol, pp: 87-96.
2. Kendall CJ (1990) Ophthalmic echography. Slack.
3. Restori M (1987) Ultrasonography of the eye and orbit. In: Clinical Ophthalmology. Wright: Bristol, pp: 81-86.
4. De Potier P (1998) Orbital imaging. In: Ophthalmology Secrets. Henley & Belfus, pp: 231-233.
5. Vander JF, Gault JA (1998) Ophthalmology secrets. Henley & Belfus, pp: 76-83.
6. Maus (1998) Orbital inflammations marton. In: Ophthalmology Secrets. Henley & Belfus, pp: 244-247.
7. Dieu D (2003) Case report: An orbital foreign body case. Vietnam Ophthalmology Journal - Eye Institute Hanoi 10: 90-92.
8. Dieu D (2018) The plant foreign body into orbit: Diagnosis and treatment. Int J Res Publication 3: 3.