

Anesthetic Implications during Off-Pump Coronary Artery Bypass Surgery

Manjula Sarkar*

*Department of Cardiac Anesthesia, Seth G. S. Medical College & KEM Hospital, Mumbai, Maharashtra, India.

Received January 03, 2019; Accepted March 11, 2019; Published April 05, 2019

ABSTRACT

Off-pump coronary artery bypass has emerged as a popular method of coronary revascularization to mitigate the harmful effects of cardiopulmonary bypass. It requires surgical and anesthetic expertise for good results. Newer minimally invasive approaches to off pump coronary bypass provide attractive alternatives to conventional off pump surgery, especially in achieving better cosmetic results and early extubation. They require good perioperative pain management, with epidural and paravertebral block being good choices. Emergency conversion of off-pump bypass to on-pump bypass is associated with poor outcomes, so preventive measures to avoid it should be employed.

Keywords: Off-pump coronary artery bypass, Anesthetic implications

INTRODUCTION

Off-pump coronary artery bypass (OPCAB) has become popular since 1990; the rationale being to avoid the deleterious effects of cardiopulmonary bypass machine. OPCAB can be done via either a full sternotomy or minimally invasive approach. Minimally invasive OPCAB requires one-lung ventilation and the access for multiple vessel revascularizations may be difficult. Conventional OPCAB avoids these limitations.

Till date there is no definitive data to suggest the benefit of OPCAB over conventional CABG with regard to long-term graft patency rates, need for repeat revascularization, stroke and mortality [1-3]. The main reason being the surgical expertise, however, patients with renal, or liver dysfunction, and those with calcified/atheromatous aorta are at advantage during OPCAB. Since this surgery involves high level of vigilance on the part of the anesthesiologist; this article intends to focus on anesthetic implications during OPCAB.

POTENTIAL ADVANTAGES OF OPCAB [1-3]

1. Reduced systemic inflammatory response, renal dysfunction, short-term neurocognitive dysfunction.
2. Reduced need for transfusion, reoperation for bleeding.
3. Reduced incidence of atrial fibrillation.
4. Reduced need for inotropes.
5. Shorter period of postoperative ventilation.
6. Reduced intensive care unit (ICU) and hospital stay, costs.

LIMITATIONS

Intracardiac thrombus, malignant arrhythmias, deep intramyocardial bridging coronaries and potential for undergrafting diseased coronary arteries.

PREOPERATIVE ANESTHESIA ASSESSMENT

Apart from routine assessment, preoperative assessment includes a review of the angiogram and a discussion with the surgeon regarding the surgical plan including the order of grafting. The CPB machine, perfusionist and facilities for defibrillation, cardiac pacing and IABP should be available. Preoperative prophylactic intra-aortic balloon pump (IABP) insertion may be considered in high-risk patients with severe LV dysfunction and left main disease as it has been shown to decrease postoperative low cardiac output syndrome and risk of death [4].

Routine monitoring for OPCAB includes 5-lead electrocardiogram (ECG) with automated ST segment analysis, pulse oximetry, invasive blood pressure, central venous pressure, end-tidal carbon-dioxide, urine output, transesophageal echocardiography (TEE) and temperature. If the cardiac surgical plan includes radial artery harvesting,

Corresponding author: Dr. Manjula Sarkar, Professor and Head, Department of Cardiac Anaesthesia, Seth G. S. Medical College & KEM Hospital, Mumbai, Maharashtra, India, E-mail: drmanjusarkar@gmail.com

Citation: Sarkar M. (2019) Anesthetic Implications during Off-Pump Coronary Artery Bypass Surgery. Int J Anaesth Res, 2(1): 22-25.

Copyright: ©2019 Sarkar M. This is an open-access article distributed under the terms of the Creative Commons Attribution License, which permits unrestricted use, distribution, and reproduction in any medium, provided the original author and source are credited.

alternative sites of pressure monitoring should be obtained. Additional monitoring like depth of anesthesia and neuromuscular monitoring can help in fast-tracking of extubation. Normothermia is essential too. Warming mattress and fluid warmer are used for this purpose.

TEE is done to confirm preoperative cardiac diagnoses, monitor preload, ventricular function, valvular regurgitation and regional wall motion abnormalities (RWMA). During heart displacement, TEE views may be lost. The use of stabilizers can produce artifacts of RWMAs. After revascularization, TEE may show new RWMAs which may be associated with reperfusion injury and myocardial stunning. Persistent and severe new RWMAs are correlated with postoperative cardiac complications [5].

Pulmonary artery catheter can be inserted in selected patients with severe LV dysfunction (ejection fraction <30%), pulmonary hypertension and right-sided heart failure to provide information regarding pulmonary artery pressure (PAP), cardiac output (CO) and mixed venous oxygen saturation. Large waves on the pulmonary capillary wedge pressure (PCWP) tracing may indicate myocardial ischemia or severe mitral regurgitation.

ACT is maintained between 250-300 s, with an initial heparin dose of 2 mg/kg. During proximal coronary anastomosis, arterial pressure should be reduced to 90 mm Hg to reduce the risk of dissection on application of aortic side-biting clamps. The left internal mammary to left anterior descending artery (LAD) anastomosis is done first as the LAD supplies a large myocardial territory and requires minimal displacement of the heart. Ventilation with low tidal volumes is required during left internal mammary artery (LIMA) harvesting and distal anastomoses to improve exposure. This may cause atelectasis in the postoperative period. Excessive tidal volumes can cause graft compression, especially when bilateral mammary arteries are used.

Access to the coronary arteries on the posterior and inferior surfaces requires the heart to be elevated by using slings, pericardial sutures, surgical packs or a suction device like the Starfish Heart Positioner. Concerns about hemodynamic status when the heart is first positioned should be communicated to the surgeon because once the coronary artery is opened; the surgical options become limited until completion of the anastomosis. Access also requires the Trendelenburg position, which beneficially increases venous return. Tissue stabilizers like the Octopus device (**Figure 1**) use suction to fix the target coronary artery to facilitate distal anastomosis. Blood flow can be controlled using a suture applied around the coronary artery proximal to the graft site. A blower using humidified carbon dioxide is used to prevent blood obscuring the arteriotomy site. Once opened, a shunt can be inserted into the artery, reducing blood in the surgical field and allowing perfusion of the distal myocardium.

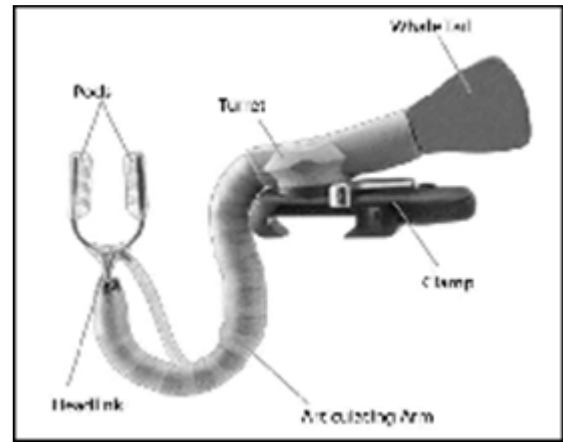


Figure 1. Medtronic octopus tissue stabilizer.

The ECG may be distorted during cardiac displacement; the axis, amplitude and ST segment changes may be reduced. Causes of hemodynamic compromise are impairment of venous return, impaired ventricular filling, valvular regurgitation, compression of thin-walled right ventricle against the interventricular septum and ischemia due to occlusion of the target artery. The amount of hemodynamic compromise usually is greatest during rotation of the heart for grafting the circumflex artery and its branches. The surgeon may open the right pleura to reduce compression. Resistant bradycardia especially during grafting of the proximal right coronary artery (RCA) can indicate sinoatrial node ischemia and epicardial pacing is urgently indicated. Hypotension could be due to hypovolaemia caused by occult blood loss into the pleural spaces. Severe mitral regurgitation, which can also be due to myocardial ischemia can cause a fall in oxygen saturation. Early repositioning of the heart is required. Cardiac displacement increases the risk of arrhythmias. Electrolytes, particularly potassium and magnesium should be kept normal in order to avoid reperfusion arrhythmias. Optimizing preload, and the use of vasopressors, inotropes will improve cardiac output. Choice of inotropes/vasopressors includes noradrenaline, adrenaline, dopamine, dobutamine, milrinone and levosimendan, which should be guided by patient hemodynamics and institutional protocol. At our institution, we start an infusion of non-adrenaline and levosimendan post-intubation if deemed necessary. In selected patient with left main disease and/or severe LV dysfunction, we have started levosimendan on the night prior to surgery with good results. Levosimendan [6] offers the advantage of increasing contractility and decreasing afterload without significantly increasing myocardial oxygen consumption. CVP and PCWP may not accurately reflect LV filling pressures, especially in patients with valvular pathology and diastolic dysfunction. TEE can help in guiding fluid management during OPCAB surgery. Minimally invasive cardiac output monitors utilizing pulse contour analysis have shown good correlation with intermittent thermodilution [7] and transesophageal

echocardiography [8] measured cardiac output. They can be used to guide fluid management and optimize preload during OPCAB. Post anastomosis, protamine may be partially or fully reversed [9-11].

Minimally invasive OPCAB

Minimally invasive OPCAB involves a thoracotomy, partial sternotomy or subxiphoid incision in contrast to a full sternotomy. It can be performed via direct, endoscopic or robotic access. Avoidance of full sternotomy which is required in conventional OPCAB is beneficial in patients with a prior sternotomy or bypass grafts. The disadvantages of minimally invasive approaches are less adequate exposure to achieve multivessel revascularization and increased duration of surgery. The advantages include potential for improved cosmesis and wound healing along with reduced morbidity, pain, cost, transfusion and length of stay in the ICU [12]. Patient selection is crucial in ensuring success of these techniques due to limited access to surgical site, requirement of one-lung ventilation, potential for incomplete revascularization and postoperative pain management. Provision for external defibrillation is a must in minimally invasive cardiac surgery. Endoscopic CABG will require insufflation of carbon-dioxide along with one-lung ventilation. Continuous monitoring of insufflation pressure, airway pressure and central venous pressures is required. One-lung ventilation has potential to cause hypoxia and may require use of permissive hypercarbia. This may necessitate use of inotropes and cause heart irritability, both of which are undesirable in performing revascularization on a beating heart.

PAIN MANAGEMENT

Adequate control of pain is crucial for fast-tracking extubation of cardiac surgery patients. Thoracotomy is considered to be more painful than median sternotomy. Regional anesthetic techniques are known to reduce opioid consumption, reduce stress response, improve coronary blood flow and pulmonary function, and facilitate early ambulation [7-12]. Commonly used regional techniques include epidural block, paravertebral block, intrathecal opioids, intercostal nerve block and intrapleural block. Catheters for regional analgesia should be inserted the day before surgery or at least an hour prior to heparinization. Surgery should be delayed for 24 h in the event of a traumatic tap. Standard guidelines should be followed to ensure safe removal of these catheters post-surgery if the patient is receiving heparin.

Complications of epidural blockade are hypotension, intravascular injection and epidural hematoma. Thoracic paravertebral block is comparable to thoracic epidural anesthesia in procedures involving unilateral thoracotomy incision [13]. It can decrease the risk of epidural hematoma while avoiding the hemodynamic effects of the sympathectomy seen with neuraxial blockade [14-16].

Complications of paravertebral block are vascular puncture and pleural puncture with pneumothorax. Despite proven benefits and the low risk of epidural hematoma, these techniques are yet to gain widespread acceptance. NSAIDs and paracetamol are important adjuncts in multimodal analgesia.

Complications and conversion to on-pump complications of OPCAB are severe hypotension unresponsive to inotropes, malignant arrhythmias, new regional wall motion abnormalities or complete cardiovascular collapse. They require emergency conversion to on-pump CABG. Conversion to CPB has been shown to increase morbidity and mortality with operative mortality ranging from 8.5 to 18%. Congestive heart failure, redo surgery, low ejection fraction, recent myocardial infarction, mitral regurgitation, and chronic obstructive pulmonary disease have been reported as independent predictors of emergency conversion to CPB.

SUMMARY

Cardiopulmonary bypass is a safe technology that has led to innovations in cardiac surgery with better outcomes. Knowledge of complications associated with it is important to avoid catastrophes. Good communication between the entire surgical team is vital. OPCAB, with good surgical and anesthetic experience can provide similar results to on-pump CABG, along with certain specific advantages.

REFERENCES

1. Cheng DC, Bainbridge D, Martin JE, Novick RJ (2005) Does off-pump coronary artery bypass reduce mortality, morbidity and resource utilization when compared with conventional coronary artery bypass? A meta-analysis of randomized trials. *Anesthesiology* 102: 188.
2. Raja SG, Dreyfus GD (2004) Off-pump coronary artery bypass surgery: To do or not to do? Current best available evidence. *J Cardiothorac Vasc Anesth* 18: 486.
3. Sellke FW, Di Maio JM, Caplan LR, Ferguson TB, Gardner TJ (2005) Comparing on-pump and off-pump coronary artery bypass grafting: Numerous studies but few conclusions: A scientific statement from the American Heart Association Council on Cardiovascular Surgery and Anesthesia in collaboration with the Interdisciplinary Working Group on Quality of Care and Outcomes Research. *Circulation* 111: 2858.
4. Yang F, Wang J, Hou D, Xing J, Liu F, et al. (2016) Preoperative intra-aortic balloon pump improves the clinical outcomes of off-pump coronary artery bypass grafting in left ventricular dysfunction patients. *Sci Rep* 6: 27645.
5. Gurbuz AT, Hecht ML, Arslan AH (2007) Intraoperative transesophageal echocardiography

- modifies strategy in off-pump coronary artery bypass grafting. *Ann Thorac Surg* 83: 1035-1040.
6. Zenati M, Domit TM, Saul M, Gorcsan J, Katz WE, et al. (1997) Resource utilization for minimally invasive direct and standard coronary artery bypass grafting. *Ann Thorac Surg* 63: S84-S87.
 7. Blomberg S, Curelaru I, Emanuelsson H, Herlitz J, Pontén J (1989) Thoracic epidural anesthesia in patients with unstable angina pectoris. *Eur Heart J* 10: 437.
 8. Gramling-Babb P, Miller MJ, Reeves ST, Roy RC, Zile MR, et al. (1997) Treatment of medically and surgically refractory angina pectoris with high thoracic epidural analgesia: Initial clinical experience. *Am Heart J* 133: 648.
 9. Olausson K, Magnusdottir H, Lurje L, Wennerblom B, Emanuelsson H, et al. (1997) Anti-ischemic and anti-anginal effects of thoracic epidural anesthesia versus those of conventional medical therapy in the treatment of severe refractory unstable angina pectoris. *Circulation* 96: 2178.
 10. Overdyk FJ, Gramling-Babb PM, Handy JR Jr (1997) Thoracic epidural anesthesia as the last option for treating angina in a patient before coronary artery bypass surgery. *Anesth Analg* 84: 213.
 11. Gramling-Babb PM, Zile MR, Reeves ST (2000) Preliminary report on high thoracic epidural analgesia: Relationship between its therapeutic effects and myocardial blood flow as assessed by stress thallium distribution. *J Cardiothorac Vasc Anesth* 14: 657.
 12. Onan IS, Onan B, Korkmaz AA, Oklu L, Kilickan L, et al. (2011) Effects of thoracic epidural anesthesia on flow and endothelium of internal thoracic artery in coronary artery bypass graft surgery. *J Cardiothorac Vasc Anesth* 25: 1063.
 13. Davies RG, Myles PS, Graham JM (2006) A comparison of the analgesic efficacy and side-effects of paravertebral vs. epidural blockade for thoracotomy - A systematic review and meta-analysis of randomized trials. *Br J Anesth* 96: 418-426.
 14. Mehta Y, Arora D, Sharma KK, Mishra Y, Wasir H, et al. (2008) Comparison of continuous thoracic epidural and paravertebral block for postoperative analgesia after robotic-assisted coronary artery bypass surgery. *Ann Card Anesth* 11: 91-96.
 15. Dhole S, Mehta Y, Saxena H, Juneja R, Trehan N, et al. (2001) Comparison of continuous thoracic epidural and paravertebral blocks for post-operative analgesia after minimally invasive direct coronary artery bypass surgery. *J Cardiothorac Vasc Anesth* 15: 288-292.
 16. Ganapathy S, Murkin JM, Boyd DW, Dobkowski W, Morgan J, et al. (1999) Continuous percutaneous paravertebral block for minimally invasive cardiac surgery. *J Cardiothorac Vasc Anesth* 13: 594-596.