

## Multimodal Imaging Approach for the Diagnosis of a Challenging Case of Bilateral Chronic Central Serous Retinopathy

Almamoori Fawwaz\*, Farid H Al-Zawaideh and Hara Mutaz

*Department of Medical Retina, Sharif Eye Center, Amman, Jordan.*

*Received February 11, 2020; Accepted February 18, 2020; Published August 19, 2020*

### ABSTRACT

Central serous retinopathy is one of the relatively common clinical conditions, it is an idiopathic disorder characterized by a localized serous detachment of the sensory retina at the macula due to leakage from the choriocapillaris through focal or diffuse retinal pigment epithelial defects. It usually affects the middle age group. Risk factors include type A personality, use of systemic steroids, stress, pregnancy and autoimmune diseases. The acute course of the disease (ACSR) usually spontaneously resolves within 3-6 months in 80% of cases, while the chronic course (CSCR) lasts more than 12 months. Multimodal new imaging techniques like Swept Source OCT (SS-OCT), FAF (fundus auto fluorescence), FA (fluorescein angiography) & ICG (indocyanine green) are necessary to diagnose atypical cases of CSCR that may be misdiagnosed as inflammatory sensory detachments leading to inappropriate treatment and visual loss.

**Keywords:** Central serous retinopathy, Multimodal imaging, Choroiditis, Posterior uveitis

### INTRODUCTION

Central serous chorioretinopathy (CSR) is the fourth most common vision threatening retinopathy after age related macular degeneration, diabetic retinopathy and retinal vascular diseases [1]. It is defined as serous retinal detachment most often in the macula, with or without pigment epithelial detachment (PED) [2]. The clinical presentation includes blurring of vision, metamorphopsia, reduced contrast sensitivity and dyschromatopsia [3].

Atypical and chronic CSCR may be misdiagnosed as chorioretinal inflammatory conditions leading to inappropriate treatment. This usually leads to worsening of CSCR with irreversible retinal damage and visual impairment.

In our case, we use multimodal retinal imaging for the diagnosis of a case of atypical bilateral CSCR which was treated previously as posterior uveitis.

### CASE REPORT

A 45-year old male, medically free, presented with decreased vision in both eyes of 8-month duration starting in the right eye (RE) and later involving the left eye (LE) in the following six months.

The patient was diagnosed initially as a case of idiopathic bilateral posterior uveitis (multifocal choroiditis, harada, serpiginous choroiditis, etc) based on negative work up for infectious and non-infectious uveitis and on OCT (optical coherence tomography) which showed bilateral multifocal

areas of neurosensory detachment with sub-foveal turbid fluid and thick choroid.

The patient was treated with several courses of oral steroids and one intravitreal triamcinolone injection in the right eye with no improvement.

On examination, his best corrected visual acuity (BCVA) was 20/100 in the right eye (RE) and 20/40 in the left eye (LE). Anterior segment examination was negative with no signs of anterior uveitis.

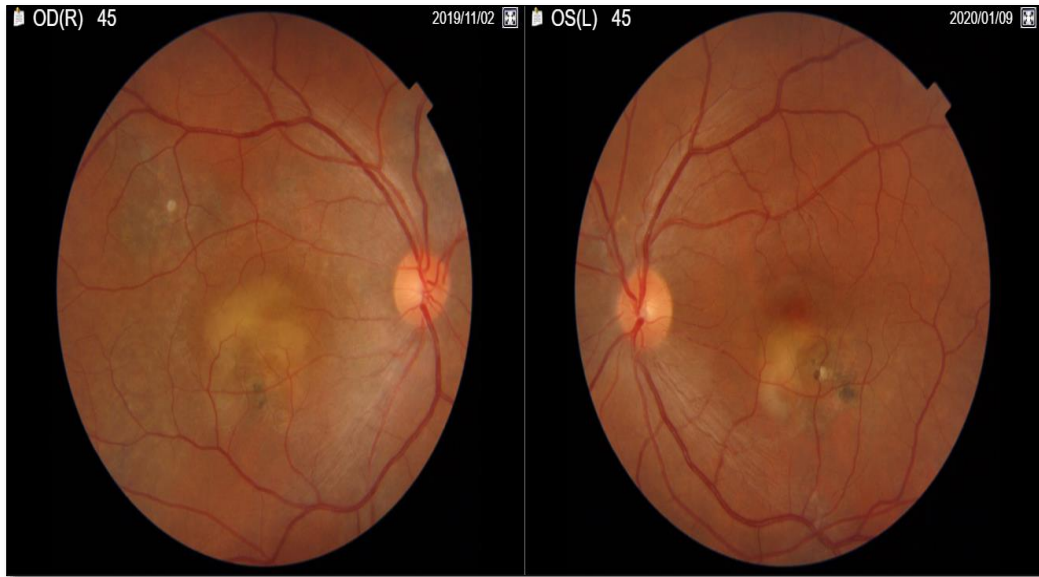
Dilated fundus exam of both eyes showed bilateral normal optic discs, bilateral sub-foveal yellowish fibrin deposition with areas of retinal pigmentary epithelial changes. The vitreous in both eyes was clear with no signs of vitritis (**Figure 1**). DRI Triton (TOPCON, Tokyo, Japan) multimodal imaging camera was used to evaluate the case.

The Triton Swept Source OCT technology using 1050 nm light enables better tissue penetration and clear image of the vitreous, retina and choroid in a single capture.

**Corresponding author:** Almamoori Fawwaz, Department of Medical Retina, Sharif Eye Center, Amman, Jordan, E-mail: fawzalmamoori@gmail.com

**Citation:** Fawwaz A, FAI-Zawaideh FH & Mutaz H. (2020) Multimodal Imaging Approach for the Diagnosis of a Challenging Case of Bilateral Chronic Central Serous Retinopathy. *Ophthalmol Clin Res*, 3(2): 157-161.

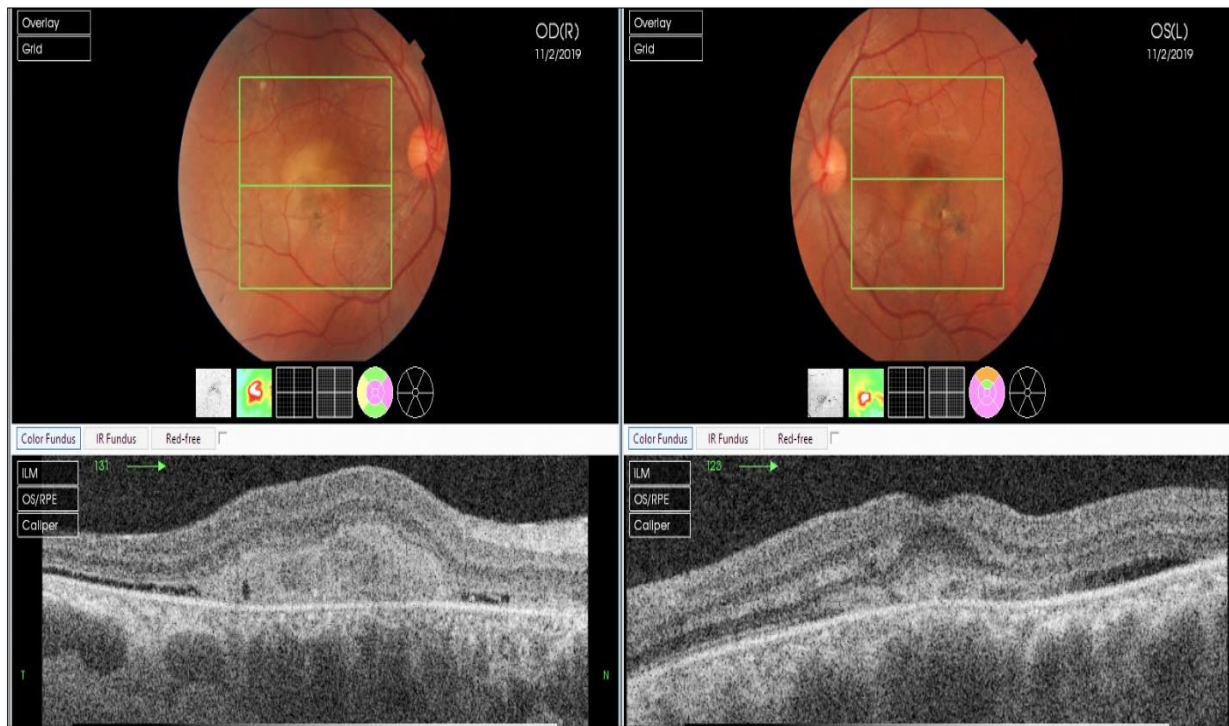
**Copyright:** ©2020 Fawwaz A, FAI-Zawaideh FH & Mutaz H. This is an open-access article distributed under the terms of the Creative Commons Attribution License, which permits unrestricted use, distribution, and reproduction in any medium, provided the original author and source are credited.



**Figure 1.** Color fundus image of the right and left eye, showing bilateral foveal fibrinous exudation with RPE pigmentary changes.

Swept Source Optical Coherence Tomography (SS-OCT) images showed bilateral sub-foveal hyperreflective fibrin deposition with adjacent areas of shallow hypo reflective sub

retinal fluid and foci of (RPE) retinal pigment epithelial detachment (**Figure 2**).

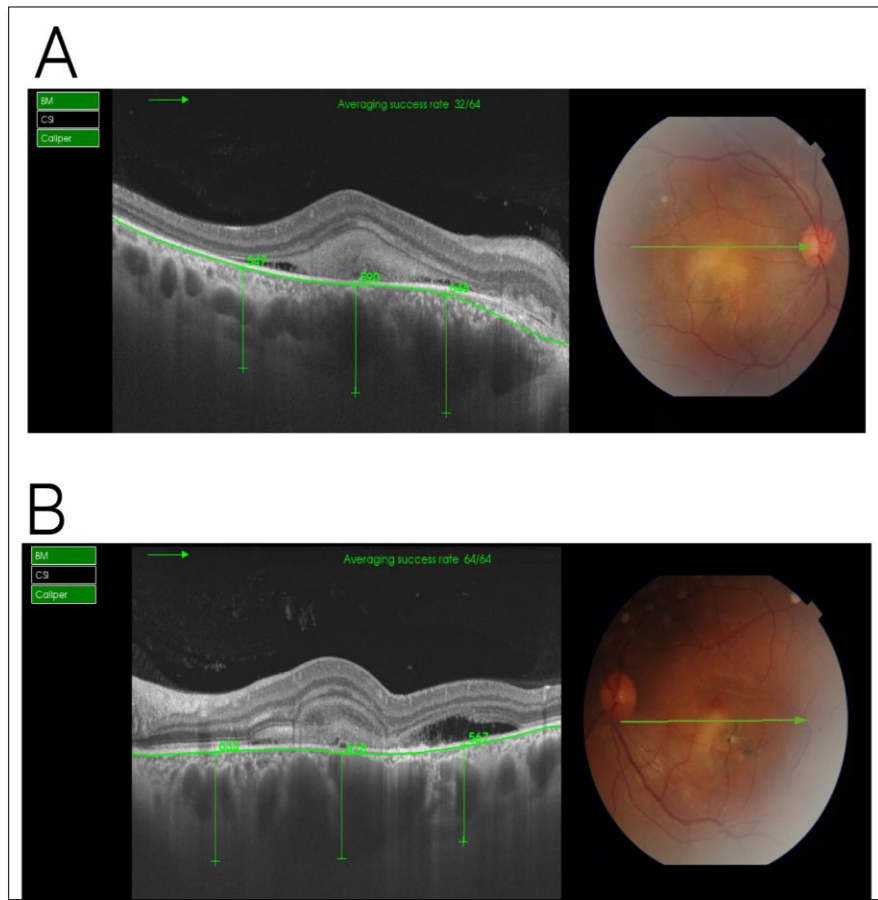


**Figure 2.** SS-OCT imaging, showing bilateral hyper reflective sub-foveal material (fibrin) with adjacent hypo reflective spaces of neurosensory detachments.

We evaluated the choroidal thickness by using a line scan mode in DRI SS-OCT that generates a B scan image

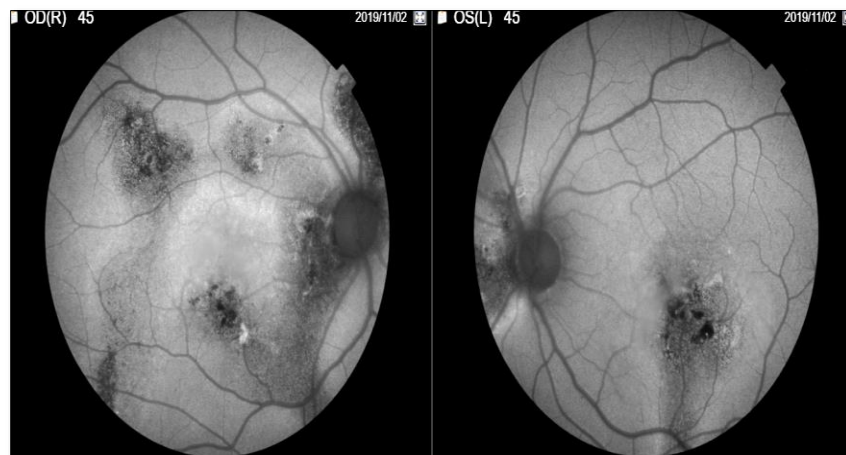
computed from 96 scans for the same line to give a high definition image of the vitreous, retina and choroid.

One-line SS-OCT B scan images showed an increase in the choroidal thickness in both eyes, which was [590  $\mu\text{m} \pm 50$ ] (Figure 3A) in the right eye and [618  $\mu\text{m} \pm 50$ ] in the left eye (Figure 3B).



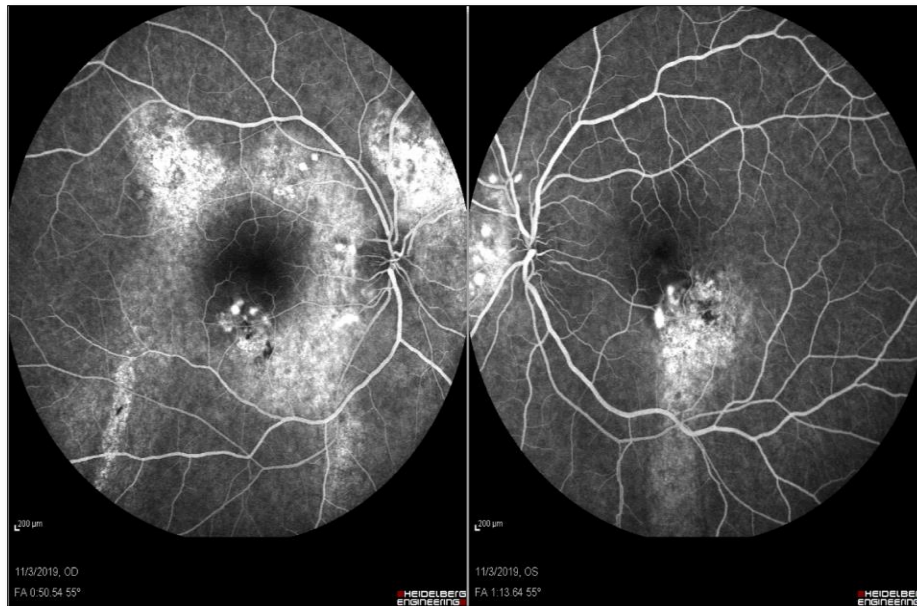**Figure 3.** 3A, 3B) One line HD scan OCT images of the right and left eye showing sub foveal hyper reflective material with increase choroidal thickness.

Fundus Auto fluorescence (FAF) showed bilateral speckled areas of hyper auto fluorescence as shown in **Figure 4**.



**Figure 4.** FAF: Fundus Auto fluorescence showing bilateral speckled areas of hyper auto fluorescence at the macular and peri macular areas in both eyes.

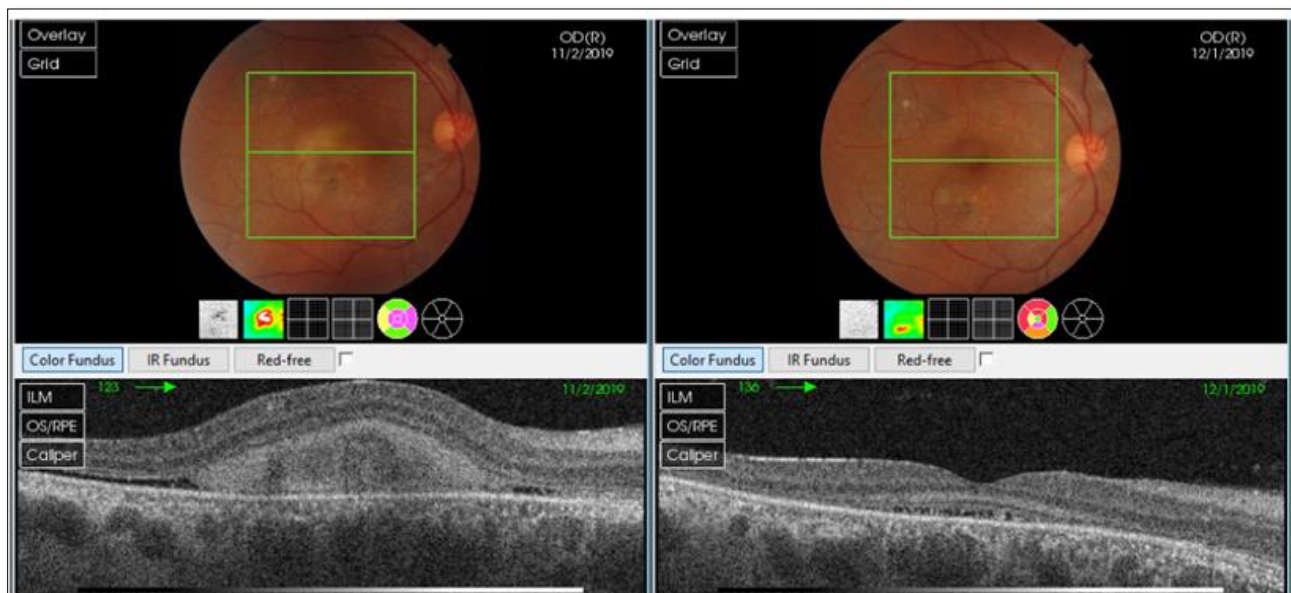
Fluorescein angiography (FA) revealed bilateral perifoveal multifocal pinpoint hyperfluorescent leakage areas with a classical “gravitational tract” (Figure 5).



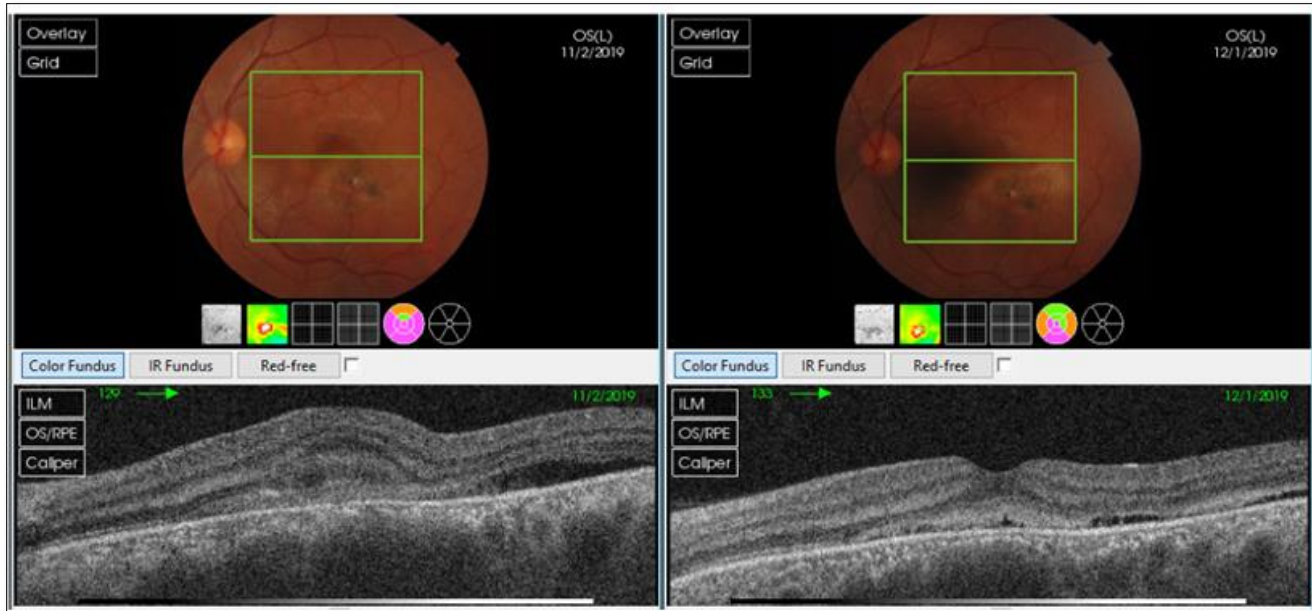
**Figure 5.** Fluorescein Angiography images of the right and left eye (late venous phase), showing bilateral perifoveal hyper fluorescent (ink dots) leaking areas with gravitational tracks.

Indocyanine green angiography was not included, because the dye is not registered in Jordan. Based on FAF and FA findings, the case was diagnosed as chronic CSR, the corticosteroids were stopped. As photodynamic therapy was not available in our clinic, a single intravitreal injection of aflibercept was performed in the both eyes [4] followed 4

weeks later by 577 nm yellow micropulse laser treatment which was applied to the active focal RPE leaking areas on FA [5]. One month later, BCVA in the right eye improved from 20/100 to 20/30 and in the left eye from 20/40 to 20/25 with improvement in the foveal anatomy on OCT (Figure 6 and 7).



**Figure 6.** OCT image of right eye before and after treatment with a flibercept and micropulse laser.



**Figure 7.** OCT image of left eye before and after treatment with a flibercept and micropulse laser.

## DISCUSSION

Atypical cases of CSCR may represent a diagnostic challenge. Such cases may be misdiagnosed as posterior uveitis like multifocal choroiditis, Vogt Koyanagi Harada, posterior scleritis---etc. The dependence on one image modality like (OCT) to diagnose such cases is inappropriate.

The use of systemic or intraocular steroids in these cases is not only ineffective, but it may lead to worsening of CSCR and severe drop of vision [6].

A transient increase in choroidal thickness is associated with acute posterior uveitis like multifocal choroiditis, VKH and white dot syndrome, this entity often occurs in eyes with CSCR and is called pachychoroid [7,8].

The increase in the choroidal thickness in our case of CSCR is a part of the pathophysiology of this disease which includes choroidal congestion and hyperpermeability as well [9] and this sometimes represents a diagnostic dilemma especially with the other cases of posterior uveitis which manifest similarly with increase in choroidal thickness.

The use of multimodal imaging OCT, FA, FAF can provide us clues for correct approach and diagnosis, the speckled hyper auto fluorescence on FAF and gravitational zones on FA were helpful for us to reach to the correct diagnosis and treatment.

## CONCLUSION

Atypical cases of CSCR need a careful approach and good analysis. The use of multimodal imaging is the best way to differentiate CSCR from other chorioretinal inflammatory cases to avoid visual loss resulting from misdiagnosis or mismanagement.

## REFERENCES

1. Wang M, Munch IC, Hasler PW, Prunte C, Larsen M (2008) Central serous retinopathy. *Acta Ophthalmol* 86: 126-145.
2. Liegl R, Ulbig MW (2014) Central serous retinopathy. *Ophthalmologica* 232: 65-76.
3. Schachat AP (2018) *Ryan's Retina*. Elsevier.
4. Padrón-Pérez N, Arias L, Rubio M, Lorenzo D, García-Bru P, et al. (2018) Changes in the choroidal thickness after intravitreal injection of Anti-vascular endothelial growth factor in Pachychoroid Neovascularopathy. *Invest Ophthalmol Vis Sci* 59: 1119-1124.
5. Yadav NK, Jayadev C, Mohan A, Vijayan P, Battu R, et al. (2015) Subthreshold micro pulse yellow laser (577 nm) in chronic central serous chorioretinopathy: Safety profile and treatment outcome. *Eye (Lond)* 29: 258-264.
6. Khairallah M, Kahloun R, Tugal-Tutkun I (2012) Central serous chorioretinopathy, corticosteroids and uveitis. *Ocul Immunol Inflamm* 20: 76-85.
7. Maruko I, Lida T, Sugano Y, Oyamada H, Sekiryu T, et al. (2011) Subfoveal choroidal thickness after treatment of Vogt-Koyanagi-Harada disease. *Retina* 31: 510-517.
8. Lehmann M, Bousquet E, Beydoun T, Behar-Cohen F (2014) PACHYCHOROID: An Inherited condition? *Retina* 35: 10-16.
9. Gass JD (1967) Pathogenesis of disciform detachment of neuroepithelium. *Am J Ophthalmol* 63: 1-139.