

Laparoscopic Cholecystectomy Accompanied by Simultaneous Umbilical Hernia Repair

Salih Tosun, Oktay Yener* and Ozgur Ekinici

*Istanbul Medeniyet University, Goztepe Educational Hospital, Istanbul, Turkey.

Received July 13, 2018; Accepted September 10, 2018; Published January 05, 2019

ABSTRACT

Background: Umbilical defects may cause technical problems for general surgeons in patients during laparoscopic cholecystectomy (LC) operations and may increase the incidence of incisional hernia.

Aim: The objectives of this study were to determine the optimal repair method for umbilical hernias during LC. Medical records of patients who had received simultaneous umbilical hernia repair with LC were investigated retrospectively.

Methods: Gall bladder stones was accompanied by umbilical hernia in 90 (6.1%) out of 1464 patients who underwent LC and umbilical hernia repair simultaneously in our hospital between January 2015 and July 2017.

Results: LC was followed by umbilical hernia repair using primary suture in 65 patients (Group 1), progrid mesh repair in 25 patients (Group 2). Progrid mesh repair was performed in Mean body mass indexes (BMI) greater than 30.0 kg/m² (Group 2).

Conclusion: The outcomes of the umbilical hernia repair with mesh after laparoscopic surgeries appear to be better for BMI greater than 30.0 kg/m² than primary suture techniques in recurrence rates.

Keywords: Combined procedures, Laparoscopic cholecystectomy

INTRODUCTION

Laparoscopic cholecystectomy (LC) is “gold standard” for the treatment of cholelithiasis. Short length of hospital stay, immediate regaining of physical activity, low rates of postoperative pain, morbidity and mortality and good cosmetic outcomes make LC advantageous [1].

Umbilical hernias comprise 6% of all abdominal hernias in adults [2]. Several surgical methods have been used in the treatment of umbilical hernias. However, there is no consensus yet on the best method for umbilical hernia repair [3,4].

METHODS

With advancement in laparoscopic surgery a number of surgical procedures can be performed combined with laparoscopic cholecystectomy in a single surgery.

It is a retrospective clinical study performed in the department of surgery in İstanbul Medeniyet University Göztepe Educational Hospital Department of General Surgery.

A retrospective review of all patients who had undergone combined procedures with laparoscopic cholecystectomy during January 2015 to July 2017 was performed.

Gallbladder Stones simultaneous umbilical hernia patients was enrolled in these study.

These study exclusion criteria as follows, Patients with strangulated Umbilical Hernia(UH), abdominal malignity, severe cardiopulmonary disease, ascites and recurrent UH. Patient’s demographic data, operation time, hospital stay, complications, size of the defect, operation technic and recurrence rate were evaluated in hospital records database. We evaluate the safety and efficiency of those surgeries.

Patients were assigned to two groups: LC+ primary repair (Group 1, n=65, 72.2%), LC+ progrid mesh repair (Group 2, n=25, 27.7%). All patients received elective operations under general anesthesia. The choice of the operative technique depended on the umbilical defect size and patients

Corresponding author: Oktay Yener, İstanbul Medeniyet University, Goztepe Educational Hospital, Beach Road 35/6 Caddebostan, İstanbul, Turkey, Tel: 009005337088469; E-mail: oktayener@gmail.com

Citation: Tosun S, Yener O & Ekinici O. (2019) Laparoscopic Cholecystectomy Accompanied by Simultaneous Umbilical Hernia Repair. Int J Surg Invasive Procedures, 2(1): 23-25.

Copyright: ©2019 Tosun S, Yener O & Ekinici O. This is an open-access article distributed under the terms of the Creative Commons Attribution License, which permits unrestricted use, distribution, and reproduction in any medium, provided the original author and source are credited.

BMI.

Under general anesthesia, we performed an incision at the level of the hernia. Hernia sac was isolated. It is inserted open laparoscopic port (Hasson Trocar) and prevents visceral injury beyond hernia sac. If the hernia size lower than 3 cm and BMI lower than 30 kg/m² primary suture was performed.

If the patients BMI greater than 30 kg/m² Progrid mesh was inserted routinely (**Figure 1**).

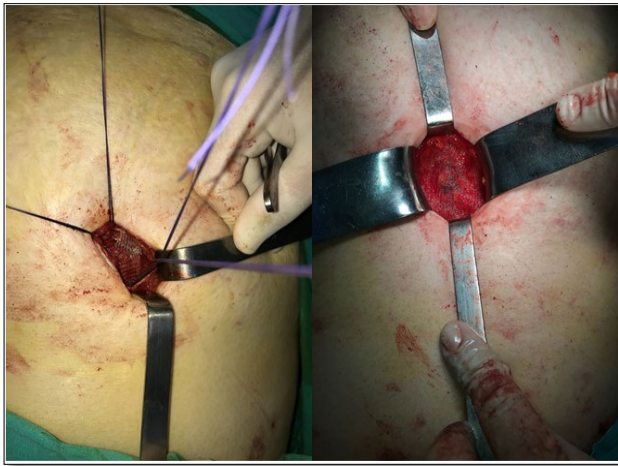


Figure 1. Progrid insertion technic.

Table 1. Demographics and characteristics of patients in treatment groups.

	Group 1	Group 2
Age (years)	25-72	33-75
Male:Female	45:20	20:5
Body mass index (kg/m ²)	<30	>30
Operative time (min)	40-75	45-85
Visual analogue scale first day	11-42	20-55
Mean hospital stay	2 ± 1.3	2 ± 1.5

Median VAS pain scores measured on the postoperative first day in two groups. There were not statistically significant differences between two groups.

We had no recurrence of the hernias during our follow up period (range 6 months to 3 years).

Combined procedures provide patients with all the benefits of minimal invasive surgery and also give the benefit of single time anesthesia without adding to post-operative morbidity and hospital stay.

DISCUSSION

Its more than 2 decades since Muhe performed the first laparoscopic cholecystectomy in 1985 [5]. Laparoscopy has

RESULTS

1464 cholecystectomies were performed in the period from January 2015 to July 2017. Of these, 90 patients were performed combined surgery. The mean operative time was 45 min (range 35-125 min). The mean hospital stay was 2.1 days (range 1-3 days).

A study was done of 1464 patients with umbilical hernia and gallbladder stone (65 undergoing laparoscopic cholecystectomy with simultaneous herniorrhaphy (first group) and 25 patients undergoing standard laparoscopic cholecystectomy with herniorrhaphy plus progrid mesh repair (second group). Patients in first group had the same time of hospitalization 2 ± 1.3 days (first group) vs. 2 ± 1.5 days (second group), the same therapy costs, without increased mortality or morbidity rates (**Table 1**).

come a long way since then and today myriad procedures are performed laparoscopically. Each of the procedure performed laparoscopically benefits from decreased post-operative pain, early ambulation, and early return to oral feeds, early discharge and early return to work [6]. Patient benefits from the single exposure to anesthesia, single hospital stay and single break from work. The procedures when combined have proved equally safe and efficacious as when done singularly.

Open umbilical hernioplasty by primary closure of the fascial defects, considered the standard repair by most surgeons, high recurrence rate can be seen after primary suture repair (11%) [7]. Synthetic mesh has a more favorable recurrence rate (1%), but may not be an appropriate option

when combined with laparoscopic procedures that violate a biliary or enteric lumen. Laparoscopic transfascial suture repair of these defects, an approach that allows wider fascial closure, may offer an attractive alternative in these cases.

Many studies have investigated LC and its complications (incisional hernia from umbilical port) or UHR and its complications (recurrence rates). However, only a limited number of studies have reported short- and long-term outcomes of UHR performed simultaneously with LC in the same session. Prevalence of cholelithiasis accompanied by umbilical hernia varies between 4.7-18% (in our study, 6.1%) [8,9].

We have found no significant increase in the hospital stay or post-operative complications in the combined procedures. Combined procedures follow the trend of the more extensive procedure with regard to the postoperative course and postoperative pain.

In addition to the benefits of minimal access, patient gets the additional advantage of single hospital stay and single anesthesia exposure. Thus it is more convenient for the patient and also more cost effective.

In effect, procedures combined with laparoscopic cholecystectomy 'kills two pathologies with one scope'.

SUMMATIVE DISCLOSURE

This article reports our experience with laparoscopic umbilical hernia suture repair when combined with another laparoscopic procedure.

DECLARATION OF CONFLICT OF INTEREST

No conflict of interest.

REFERENCES

1. Berggren U, Gordh T, Grama D, Haglund U, Rastad J, et al. (1994) Laparoscopic versus open cholecystectomy: Hospitalization, sick leave, analgesia and trauma responses. *Br J Surg* 81: 1362-1365.
2. Lau H, Patil NG (2003) Umbilical hernia in adults. *Surg Endosc* 17: 2016-2020.
3. Wright BE, Beckerman J, Cohen M, Cumming JK, Rodriguez JL (2002) Is laparoscopic umbilical hernia repair with mesh a reasonable alternative to conventional repair? *Am J Surg* 184: 505-509.
4. Nguyen NT, Lee SL, Mayer KL, Furdui GL, Ho HS (2000) Laparoscopic umbilical herniorrhaphy. *J Laparoendosc Adv Surg Tech A* 10: 151-153.
5. Jani K, Rajan PS, Sendhilkumar K, Palanivelu C (2006) Twenty years after Erich Muhe: Persisting controversies with the gold standard of laparoscopic cholecystectomy. *J Min Access Surg* 2: 49-56.
6. Wadhwa A, Chowbey PK, Sharma A, Khullar R, Soni V, et al. (2003) Combined procedures in laparoscopic surgery. *Surg Laparosc Endosc Percutan Tech* 13: 382-386.
7. Arroyo A, Garcia P, Perez F, Andreu J, Candela F, et al. (2001) Randomized clinical trial comparing suture and mesh repair of umbilical hernia in adults. *Br J Surg* 88: 1321-1323.
8. Nassar AH, Ashkar KA, Rashed AA, Abdulmoneum MG (1997) Laparoscopic cholecystectomy and the umbilicus. *Br J Surg* 84: 630-633.
9. Nguyen NT, Lee SL, Mayer KL, Furdui GL, Ho HS (2000) Laparoscopic umbilical herniorrhaphy. *J Laparoendosc Adv Surg Tech A* 10: 151-153.