

COVID-19 in Sarcoidosis Patients

Attapon Cheepsattayakorn^{1,2,3,4*}, Porntep Siriwanarangsun¹ and Ruangrong Cheepsattayakorn⁵

^{*1}Faculty of Medicine, Western University, Pathumtani Province, Thailand

^{*2}Faculty of Medicine Vajira Hospital, Navamindradhiraj University, Bangkok, Thailand

^{*3}10th Zonal Tuberculosis and Chest Disease Center, Chiang Mai, Thailand

^{*4}Department of Disease Control, Ministry of Public Health, Thailand

⁵Department of Pathology, Faculty of Medicine, Chiang Mai University, Chiang Mai, Thailand.

Received January 03, 2024; Revised February 16, 2024; Accepted February 19, 2024

Several post-COVID-19 inflammatory disorders and autoimmune diseases have been discovered [1] since global COVID-19 pandemic started [2]. Association between these diseases is still to be investigated [2]. Common genes between COVID-19 and sarcoidosis are demonstrated in **Figures 1 & 2** [3]. Nevertheless, sarcoidosis organ involvement, demographics, and type of sarcoidosis treatment at the time of COVID-19 diagnosis are related to hospital admission, non-invasive ventilation or high flow oxygenation, intubation [4]. A retrospective hospital-based cohort study of 585 French sarcoidosis patients in 2017,

demonstrated an estimate of a 5 % frequency of severe infections that resulting in hospital admission and death [5]. A typical HRCT feature in sarcoidosis is the presence of well-defined micronodules scattered along the broncho-vascular bundle, veins, fissures and pleura in a characteristic lymphatic distribution. Occasionally, “galaxy sign”, a highly suggestive of pulmonary sarcoidosis (predominance of a mid-to-upper lung zones) may demonstrates conglomerate masses that are surrounded by a multitude of micronodules (**Figure 3**) [6].

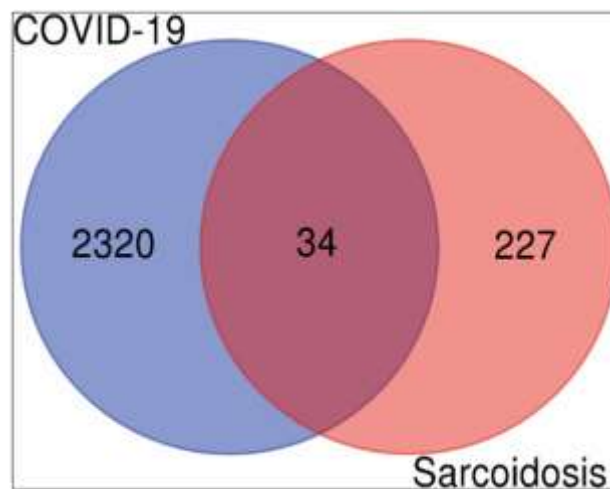


Figure 1. Demonstrating a Venn diagram of commonly differentially expressed upregulated genes. Common 34 upregulated genes were identified from 2320 upregulated genes of COVID-19 infection and 227 upregulated genes of sarcoidosis [3].

Corresponding author: Attapon Cheepsattayakorn, 10th Zonal Tuberculosis and Chest Disease Center, 143 Sridornchai Road Changklan Muang Chiang Mai, 50100, Thailand, Tel: 66 53 140767, 66 53 276364; Fax: 66 53 140773, 66 53 273590; E-mail: Attapon1958@gmail.com

Citation: Cheepsattayakorn A, Siriwanarangsun P & Cheepsattayakorn R. (2024) COVID-19 in Sarcoidosis Patients. *J Infect Dis Res*, 7(1): 348-352.

Copyright: ©2024 Cheepsattayakorn A, Siriwanarangsun P & Cheepsattayakorn R. This is an open-access article distributed under the terms of the Creative Commons Attribution License, which permits unrestricted use, distribution, and reproduction in any medium, provided the original author and source are credited.

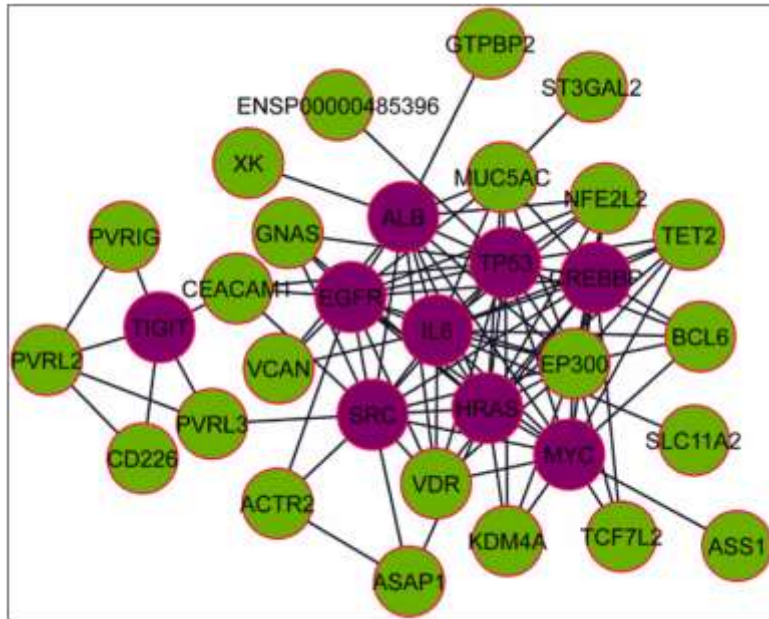


Figure 2. Demonstrating protein-protein interactions (PPIs) network for common upregulated genes from COVID-19 and sarcoidosis. The light green color nodes indicate common upregulated genes. Network consists of 32 nodes and 102 edges [3].

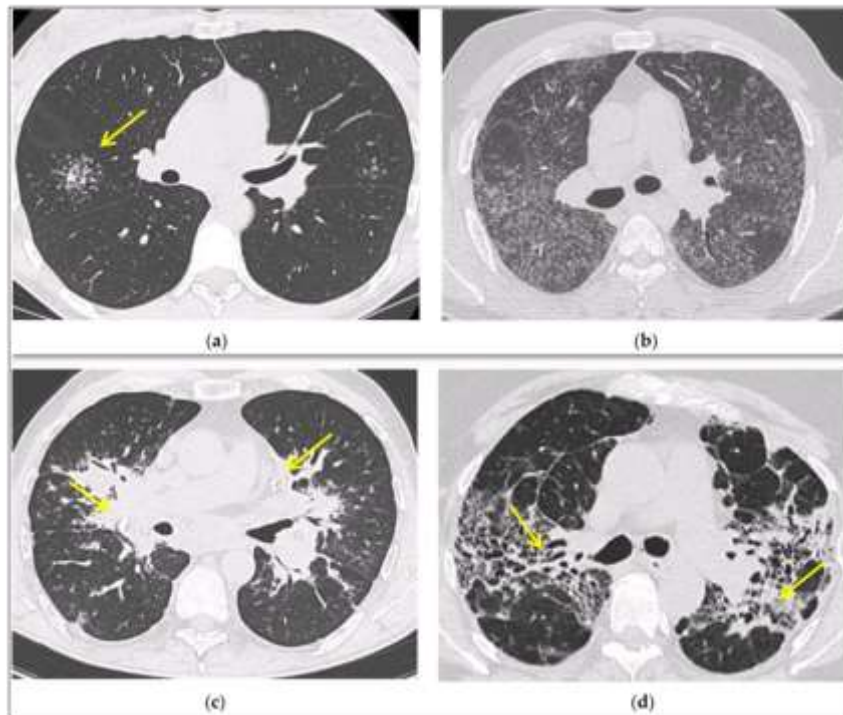


Figure 3: Demonstrating irregularly marginated nodule surrounded by multiple small nodules (“Galaxy sign”, yellow narrow), this is typical of sarcoidosis (a); ground-glass-like increased attenuation resulting from diffuse micronodules randomly distributed (“Miliary sarcoidosis”) (b); enlarged and partially calcified (yellow narrows) bilateral hilar lymph nodes (c); fibrotic sarcoidosis with cystic changes and traction bronchiectases (yellow narrows) predominantly in the perihilar region and upper lobes. Nodular abnormalities are minimal/absent, but the appearance and the location of the fibrosis are very suggestive of the diagnosis of sarcoidosis (d) [6].

Where VDR dominantly connected to 14 different kinds of drug, protein drug interaction network collected from DrugBank provides proper treatment. Vitamin D and some

of its analogous compounds might play significant roles in modulating both COVID-19 and sarcoidosis conditions is indicated by this network (**Figure 4**) [3].

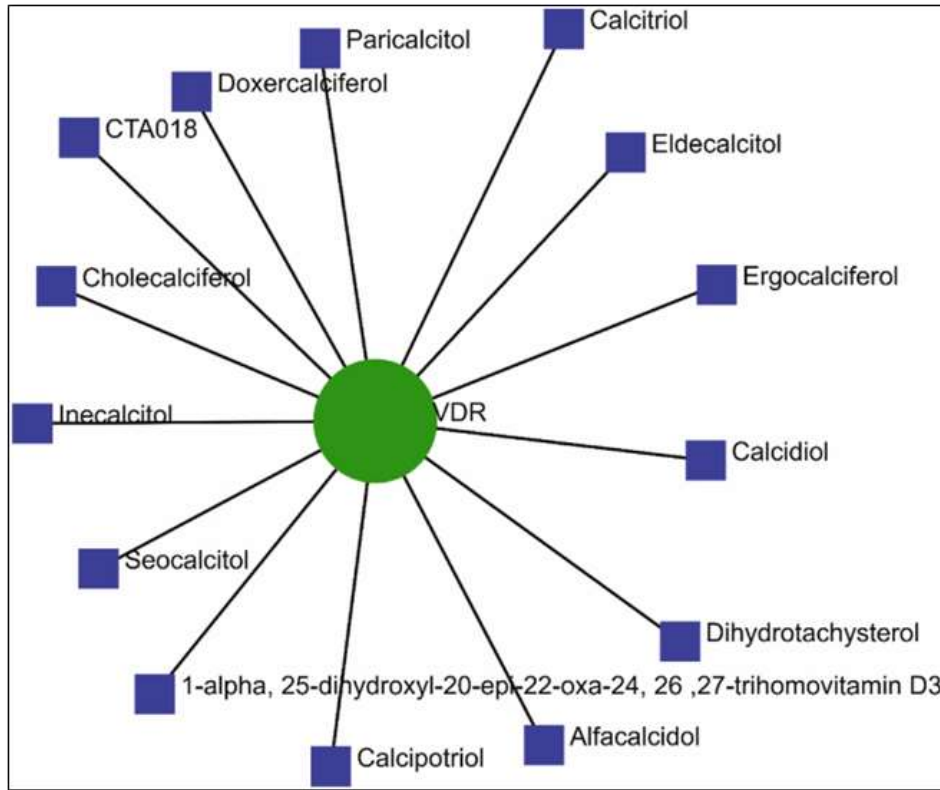


Figure 4. Demonstrating drugs protein interaction network [3].

Besides sarcoidosis of lungs, symptomatic and accidental extrapulmonary sarcoidosis is also found around the world (**Figures 5-7**) [7-9].

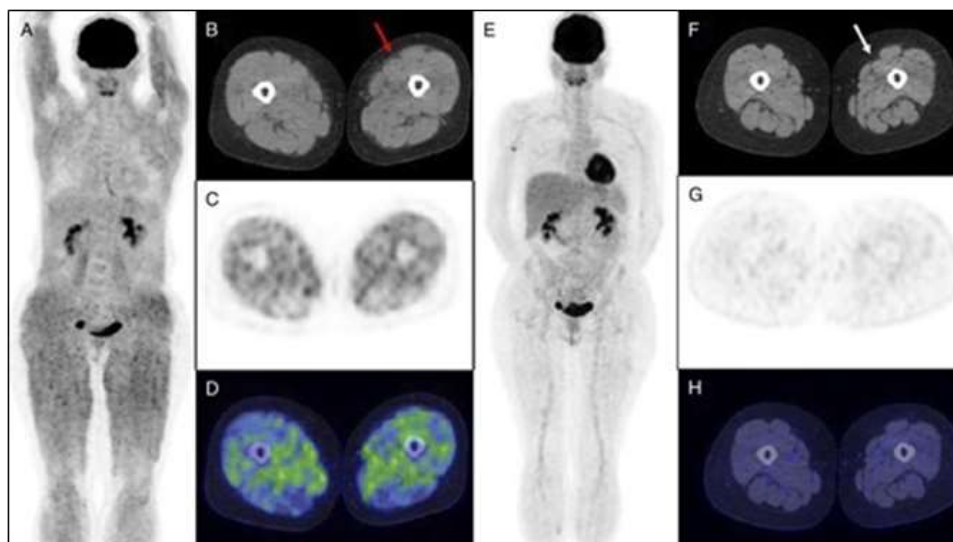


Figure 5. Demonstrating isolated muscular sarcoidosis, revealed by hypercalcemia and 18F-FDG PET/CT [7].

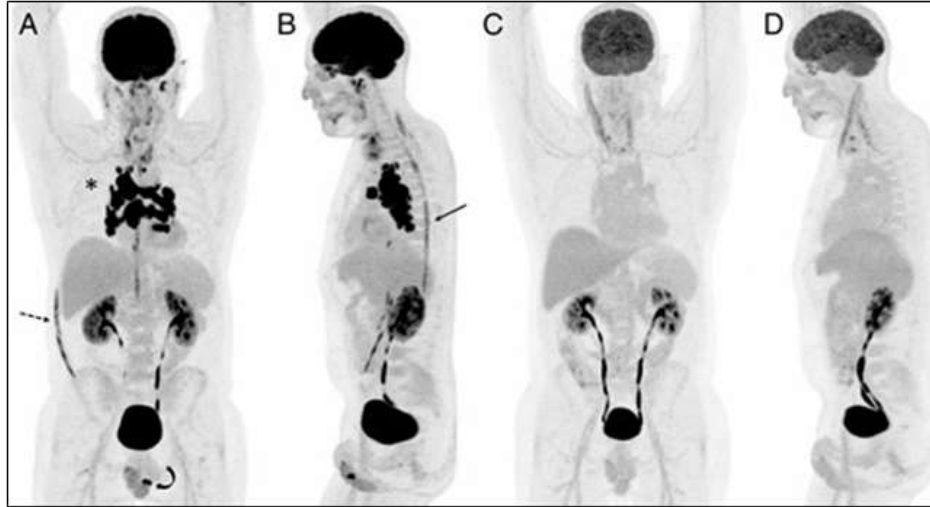


Figure 6. ¹⁸F-FDG PET/MRI for Diagnosis and Treatment Efficacy Evaluation of Spinal Sarcoidosis [8].

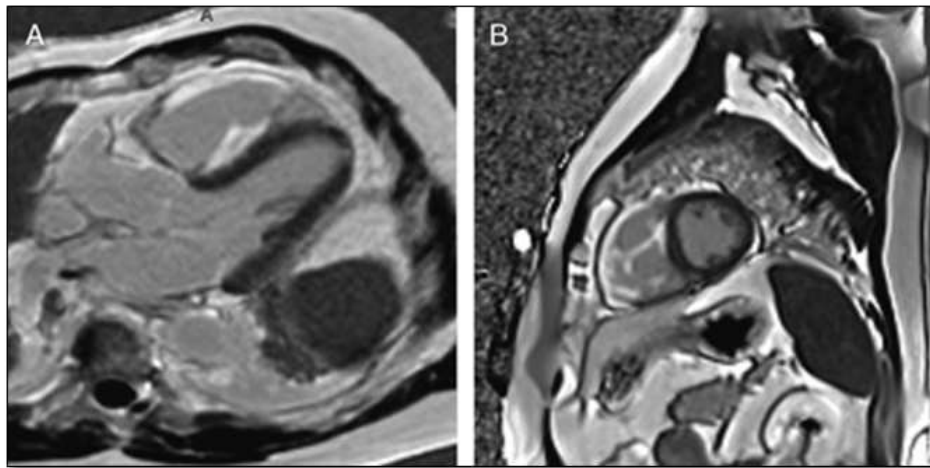


Figure 7. Demonstrating FDG PET of Isolated Right Ventricular Sarcoidosis [9].

In conclusion, hub gene identification might have significant roles in modulating sarcoidosis and COVID-19 infection. In the literature, cases with sarcoid-like granuloma have been reported very few. Sarcoid-like immune response to COVID-19 could be noncaseating granulomas due to short time from disease to develop granuloma.

REFERENCES

1. Galeotti C, Baryl J (2020) Autoimmune and inflammatory diseases following COVID-19. *Nat Rev Rheumatol* 16(8): 413-414.
2. Racil H, Znegui T, Maazoui S, Touil A, Habibech S, Henda N, et al. (2023) Can coronavirus disease 2019 induce sarcoidosis: A case report. *Thorac Res Pract* 24(1): 45-48.
3. Mogal R, Sovupa SA, Junayed A, Mahmud R, Abedin Z, Sikder S (2022) Common genetic aspects between

- COVID-19 and sarcoidosis: A network-based approach using expression data. *Biochem Biophys Res* 29: 101219.
4. Nadeem O, Sharma A, Alaouie D, Bradley P, Ouellette D (2021) Outcome in patients with sarcoidosis diagnosed with COVID-19. Presentation at Chest 2021 Annual Meeting, pp: 17-20.
5. Dureault A, Chapelon C, Biard L, Domont F, Savey L, et al. (2017) Severe infections in sarcoidosis: Incidence, predictors and long-term outcome in a cohort of 585 patients. *Medicine (Baltimore)* 96: e8846.
6. Bernardinello N, Petrarulo S, Balestro E, Cocconcelli E, Veltkamp M, Spagnolo P (2021) Pulmonary Sarcoidosis: Diagnosis and Differential Diagnosis. *Diagnostics (Basel)* 11(9):1558.

7. Dhomps A, Thibault F, Streichenberger N, Andrea S, Jeremie T (2019) Isolated muscular sarcoidosis revealed by hypercalcemia. *Clin Nucl Med* 44(10): 824-825.
8. Ashjan K, Darejan B, Lea F, Mathilde H, Vincent P, Imperiale, et al. (2024) ¹⁸F-FDG PET/MRI for diagnosis and treatment efficacy evaluation of spinal sarcoidosis. *Clin Nucl Med* 49(1): e28-e30.
9. Alan S, Dagmar HS (2023) FDG PET of Isolated Right Ventricular Sarcoidosis. *Clin Nucl Med* 48(2): 184-185.