

The Behavior, Prognosis and Management of Ovarian Mature Cystic Teratomas during Pregnancy: A Literature Review

Liang-Hsuan Chen and Hsien-Ming Wu*

*Department of Obstetrics and Gynecology, Chang Gung Memorial Hospital, Taoyuan, Taiwan.

Received June 28, 2018; Accepted July 05, 2018; Published September 25, 2018

ABSTRACT

Mature cystic teratomas (MCTs) are the most common ovarian tumors in pregnancy. They may require surgical intervention due to the pregnancy complication such as torsion, rupture or obstruction of labor. Most references recommend elective extirpation of the mass in midgestation, either by laparotomy or laparoscopy. By the better understanding of clinical features and prognosis of ovarian MCTs during pregnancy; the purpose of this article is to provide the physician with the information to counsel their patients preoperatively.

Keywords: Mature cystic teratomas, Pregnancy, Ovarian tumors

INTRODUCTION

The adnexal masses during pregnancy are detected incidentally in early pregnancy; with the preference ranging from 1 in 81 to 1 in 8000 pregnancies [1,2]. Under regular antenatal exam, most of the functional cysts will spontaneously regression in second trimester. The overall incidence of malignancy in an adnexal mass is about 1-8% [1-3]. The persisting ovarian tumors may cause pregnancy complication such as torsion, rupture and obstructive labor.

Most of ovarian masses discovered during pregnancy are mature cystic teratomas, which account for one fourth of ovarian neoplasms [1-3]. Based on the review of literature, we present the current concepts on the management of ovarian mature cystic teratomas during pregnancy.

CLINICAL MANIFESTATION

Mature cystic teratomas (MCTs) in pregnancy are usually asymptomatic unless complications such as torsion or rupture occur. With the efficacy of ultrasound, MCTs can be detected in first trimester. During the pregnancy, MCTs are slow-growing and most are unilateral; approximately 10% of cases are bilateral [4]. Tumors less than 6 cm are not expected to grow or cause complications during pregnancy [5]. However, several cases were reported that MCTs grew rapidly from a small tumor to a huge mass toward the end pregnancy [6-9]. There was no relationship between the clinical features and histopathological contents of MCTs [10]. Two case reports of progressive mediastinal teratomas

during pregnancy were found with positive estrogen and progesterone receptors. This disclosed a theory that the change in hormone levels after pregnancy may stimulated the sensitive tumor cells leading to rapid growth of MCTs [8,9].

With the persistent ovarian tumors in pregnancy, closely surveillance is indicated for the risk of torsion (1-22%), rupture (0-9%), obstruction of labor (2-17%) or the possibility of malignant transformation [11]. In a study retrospectively collected data from 212 patients with adnexal tumors of 4 cm in diameter or larger during pregnancy, a significant higher risk of torsion was reported of the tumor with sizes between 6 and 8 cm (odds ratio 2.8, 95% confidence interval (CI), (1.1, 6.6)); moreover, sixty percent of the torsion happened between the 10th and 17th weeks of gestation and only 5.9% happened after 20 weeks [12].

Corresponding author: Hsien-Ming Wu, Chang Gung Memorial Hospital, No. 5, Fusing St., Gueishan Township, Taoyuan County 333, Taiwan (R.O.C.), Tel: 886-3-3281200; Ext. 8984; Fax: 886-3-3288252; E-mail: danielwu@cgmh.org.tw

Citation: Chen LH & Wu HM. (2018) The Behavior, Prognosis and Management of Ovarian Mature Cystic Teratomas during Pregnancy: A Literature Review. Arch Obstetr Gynecol Reprod Med, 1(1): 17-19.

Copyright: ©2018 Chen LH & Wu HM. This is an open-access article distributed under the terms of the Creative Commons Attribution License, which permits unrestricted use, distribution, and reproduction in any medium, provided the original author and source are credited.

Current consensus recommend elective extirpation of the masses in the second trimester if they grow beyond 6 cm in diameter [11].

SURGICAL INTERVENTION

Laparotomy approach was long-thought to be standard surgery in pregnancy. Following the update evidence, the concerns of unknown effect of pneumoperitoneum on the gravid uterus are eradicated; and also, the risk of uterus penetration is minimized by the open Hassan technique for the initial abdominal entry [11]. Some studies demonstrate the laparoscopic extracorporeal oophorectomy and ovarian cystectomy in mid-gestation, which avoids endoscopic instrumental maneuver in the abdomen and requires less abdominal insufflation pressure [13]. With similar maternal and fetal outcomes comparing to the traditional laparotomy, the laparoscopic management of MCTs in pregnancy is preferable route because of the potential benefits of the reduction in blood loss [14,15], postoperative pain [14-16], hospital stay [14-17] and therefore total cost [14].

When considering fertility preservation, it is advisable to offer cystectomy rather than oophorectomy. However, intraoperative spillage of MCT contents may lead to postoperative chemical peritonitis (clinically presented with postoperative fever and ileus associated with deposits on the peritoneum and adhesion formation) [18]. A regression analysis reported an increase in cyst spillage rates only with surgeon inexperience while others including cyst size, laparoscopy versus laparotomy and the presence of adhesions have found no difference [19]. Last but not least, the patient with cystectomy should be informed that a prompt second staging operation will be required if the definitive pathology reveals an unexpected malignancy.

PREGNANCY OUTCOME AND RECURRENCE

An overall increased risk for preterm delivery is up to 22% compared with those not undergoing surgery, regardless of the surgical route [20]. Furthermore, there is a higher risk of fetal compromise in emergent surgery due to maternal illness [21].

The incidence of postoperative recurrence on the same ovary is 3-4% [22]. Some animal models have shown that trauma (laparoscopic port sites and previous cesarean delivery scars) and cytogenetic abnormalities are presumed associated with the development of MCTs [23]. In a retrospective study, a patient with young age (<30 years old), large cyst (≥ 8 cm in diameter) or bilateral cysts is at high risk of recurrence, which is even higher in those with more than one of the predictive factors [24] (**Figure 1**).

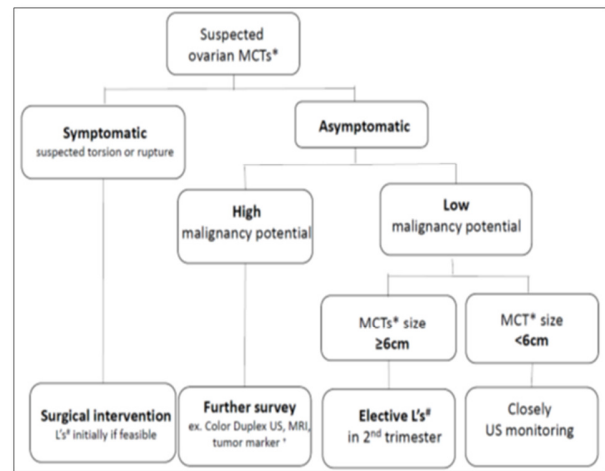


Figure 1. Algorithm chart.

*MCTs: Mature Cystic Teratomas; #L's: Laparoscopy; +A limited diagnostic value when used alone

CONCLUSION

MCTs comprise one fourth of all ovarian tumors encountered in pregnancy. Elective extirpation of the tumors which grow beyond 6 cm is recommended in mid-gestation due to the risk of pregnancy complication and malignant potential. A laparoscopic approach should be considered when surgeons with appropriate skills and training are available. After surgical excision, younger patients and patients with bilateral or large size of dermoid cysts should be followed up closely.

FUNDING

We did not use any fund for this study.

COMPLIANCE WITH ETHICAL STANDARDS

Conflict of interest

We declare that we have no conflict of interest.

Ethical approval

This article does not contain any studies with human participants or animals performed by any of the authors.

REFERENCES

1. Leiserowitz G (2006) Managing ovarian masses during pregnancy. *Obstet Gynecol Surv* 61: 463-470.
2. Whitecar P, Turner S, Higby K (1999) Adnexal masses in pregnancy: A review of 130 cases undergoing surgical management. *Am J Obstet Gynecol* 181: 19-24.
3. Schmeler K, Mayo-Smith W, Peipert J, Weitzen S, Manuel M, et al. (2005) Adnexal masses in pregnancy: surgery compared with observation. *Obstet Gynecol* 105: 1098-1103.

4. Kim MJ, Kim NY, Lee DY, Yoon BK, Choi D (2011) Clinical characteristics of ovarian teratoma: Age-focused retrospective analysis of 580 cases. *Am J Obstet Gynecol* 205: 32.e1-32.e4.
5. Caspi B, Levi R, Appelman Z, Rabinerson D, Goldman G, et al. (2000) Conservative management of ovarian cystic teratoma during pregnancy and labor. *Am J Obstet Gynecol* 182: 503-505.
6. Chen LH, Chang SD, Huang HY, Wang HS, Soong UK, et al. (2017) Repeated pregnancy with concomitant presence of ovarian teratoma: A case report and literature review. *Taiwan J Obstet Gynecol* 56: 694-696.
7. Donnadiou AC, Deffieux X, Le Ray C, Mordefroid M, Frydman R, et al. (2006) Unusual fast-growing ovarian cystic teratoma during pregnancy presenting with intracystic fat "floating balls" appearance. *Fertil Steril* 86: 1758-1759.
8. Kanlioglu Kuman N, Cokpinar S, Yaman E, Meteoglu I, Karadag F (2012) Teratoma during pregnancy with positive estrogen and progesterone receptors and elevated Ca19-9 antigen levels. *Case Rep Surg*, pp: 1-4.
9. El Hammoumi M, Benosman A, Kabiri EH (2015) Giant teratoma presenting with pregnancy and causing respiratory failure. *Arch Bronconeumol* 51: 250-251.
10. Cakmak B, Nacar M, Ozsoy Z, Aliyev N, Koseoglu D (2015) Mature cystic teratomas: Relationship between histopathological contents and clinical features. *Niger J Clin Pract* 18: 236.
11. Hoover K, Jenkins TR (2011) Evaluation and management of adnexal mass in pregnancy. *Am J Obstet Gynecol* 205: 97-102.
12. Yen CF, Lin SL, Murk W, Wang CJ, Lee CL, et al. (2009) Risk analysis of torsion and malignancy for adnexal masses during pregnancy. *Fertil Steril* 91: 1895-1902.
13. Chung MK, Chung RP (2001) Laparoscopic extracorporeal oophorectomy and ovarian cystectomy in second trimester pregnant obese patients. *JSLs* 5: 273-277.
14. Howard FM (1995) Surgical management of benign cystic teratoma. *J Reprod Med* 40: 495-499.
15. Morgante G, Ditto A, La Marcia A, Trotta V, De Leo V (1998) Surgical treatment of dermoid cysts. *Eur J Obstet Gynecol Reprod Biol* 81: 47-50.
16. Lin PL, Falcone T, Tulindi T (1995) Excision of ovarian dermoid cyst by laparoscopy and by laparotomy. *Am J Obstet Gynecol* 173: 769-771.
17. Zanetta G, Ferrari L, Mignini-Renzini M, Vignali M, Fadini R (1999) Laparoscopic excision of ovarian dermoid cysts with controlled intraoperative spillage. Safety and effectiveness. *J Reprod Med* 44: 815-820.
18. Templeman CL, Fallat ME, Lam AM, Perlman SE, Hertweck SP, et al. (2000) Managing mature cystic teratomas of the ovary. *Obstet Gynecol Surv* 55: 738-745.
19. Milad MP, Olsen E (1999) Factors that increase the risk of leakage during surgical removal of benign cystic teratomas. *Hum Reprod* 14: 2264-2267.
20. Moore R, Smith WG (1999) Laparoscopic management of adnexal masses in pregnant women. *J Reprod Med* 44: 97-100.
21. Yuen P, Ng P, Leung P, Rogers M (2004) Outcome in laparoscopic management of persistent adnexal mass during the second trimester of pregnancy. *Surg Endosc* 18: 1354-1357.
22. Pepe F, Panella M, Pepe G, Panella P, Pennisi F, et al. (1986) Dermoid cysts of the ovary. *Eur J Gynaecol Oncol* 7: 186-191.
23. Doss N Jr, Forney JP, Vellios F, Nalick RH (1977) Covert bilaterality of mature ovarian teratomas. *Obstet Gynecol* 50: 651-653.
24. Harada M, Osuga Y, Fujimoto A, Fujii T, Yano T, et al. (2013) Predictive factors for recurrence of ovarian mature cystic teratomas after surgical excision. *Eur J Obstet Gynecol Reprod Biol* 171: 325-328.