

A Case Report Discussing Differential Diagnosis and the Treatment of Sacroiliitis in a Patient Undergoing Peritoneal Dialysis

Benchérifa S*, Amine B, El Binoune I, Rostom S and Bahiri R

*Department of Rheumatology A, El Ayachi Hospital-Salé, CHU Ibn Sina, University Mohammed V- Rabat, Morocco.

Received October 09, 2019; Accepted October 27, 2019; Published January 27, 2020

ABSTRACT

Background: The occurrence of buttock inflammatory pain in a patient who undergoes peritoneal dialysis will gradually take us in different diagnosis. Thus, a full review is required to guide the diagnosis selection.

Case presentation: It's about a 43 year old Moroccan male patient, who has been diagnosed for type I diabetes using insulin for 24 years complicated in April 2011 by diabetic nephropathy with severe renal insufficiency. Due to the progressive decline in kidney function, the patient presented, in March 2017, an end-stage renal disease and started the peritoneal dialysis as renal replacement therapy. The diabetes was also complicated by bilateral retinopathy and bilateral distal arteriopathy. He was presenting since April 2018, a buttock inflammatory pain in the left side at the first time, which became bilateral 3 months later without peripheral articular signs, without enthesitis signs and without extra-articular signs. The clinical examination revealed positive sacroiliac joint tests provocation. Our patient presented a diagnostic and a therapeutic problem. Therefore, the laboratory analysis, radiographic and magnetic resonance imaging assessments were requested. Etiologic investigation was conducted concluding to bilateral sacroiliitis in relation with ankylosing spondylitis in its axial radiographic form according to the laboratory analysis and the magnetic resonance imaging features. In such cases, the treatment with non-steroidal anti-inflammatory drugs is limited because of their nephrotoxic effects. The suggested therapeutic alternative was the anti-TNF α agents based on the encouraging results reported in the literature.

Conclusion: The discovery of radiographic sacroiliitis in a patient on long-term renal replacement therapy poses a real problem of differential diagnosis. In our case, the sacroiliitis was related to the active axial ankylosing spondylitis arising in a patient receiving peritoneal dialysis. In this article, we report also the efficacy and the safety of etanercept that was suggested as a treatment.

Keywords: Peritoneal dialysis, Sacroiliitis, Ankylosing spondylitis, Etanercept

Abbreviations: ESR: Erythrocyte Sedimentation Rate; CRP: C-Reactive Protein; MCV: Mean Corpuscular Volume; HLA: Leukocyte Antigen; MRI: Magnetic Resonance Imaging; AS: Ankylosing Spondylitis; ASAS-OMERACT: Assessment of SpondyloArthritis International Society-Outcome Measures in Rheumatology Clinical Trials; BASDAI: Ankylosing Spondylitis Disease Activity Index; BASFI: Bath Ankylosing Spondylitis Disease Functional Index; ASDAS-CRP: Ankylosing Spondylitis Disease Activity Score-CRP; EULAR: European League Against Rheumatism; SFR: French Society of Rheumatology; NSAIDs: Non-Steroidal Anti-Inflammatory Drugs; RA: Rheumatoid Arthritis; HD: Hemodialysis; PD: Peritoneal Dialysis

INTRODUCTION

The sacroiliitis in a patient receiving peritoneal dialysis can be caused by infectious, rheumatic or metabolic diseases but the clinical, radiographic and magnetic resonance imaging data allow making a difference between the several entities [1-3]. When the diagnosis is related to the active axial ankylosing spondylitis as the case report that we will discuss in this article, the therapeutic management problem arises. In those patients with end-stage renal disease who undergo renal replacement therapy, especially peritoneal dialysis and according to the recent international recommendations, the

Corresponding author: Dr. Sara Benchérifa, Department of Rheumatology A, El Ayachi Hospital-Salé, CHU Ibn Sina, University Mohammed V- Rabat, Morocco, E-mail: sara.bencherifa@gmail.com

Citation: Benchérifa S, Amine B, El Binoune I, Rostom S & Bahiri R. (2020) A Case Report Discussing Differential Diagnosis and the Treatment of Sacroiliitis in a Patient Undergoing Peritoneal Dialysis. J Rheumatol Res, 2(2): 107-112.

Copyright: ©2020 Benchérifa S, Amine B, El Binoune I, Rostom S & Bahiri R. This is an open-access article distributed under the terms of the Creative Commons Attribution License, which permits unrestricted use, distribution, and reproduction in any medium, provided the original author and source are credited.

non-steroidal anti-inflammatory drugs are the first line treatment, but their use is limited due to their nephrotoxicity [4,5]. In this case, the treatment by the anti-TNF α as second line treatment is indicated, but a little is known about treating this population with anti-TNF α agents, except a few published cases in the literature that we will describe [6,7].

CASE PRESENTATION

A 43-year-old Moroccan male patient was diagnosed for type I diabetes using insulin for 24 years complicated in April 2011 by diabetic nephropathy with severe renal insufficiency. Due to the progressive decline in kidney function, the patient presented in March 2017, an end-stage renal disease with creatinine clearance less than 15 ml/min. Therefore, he started the peritoneal dialysis as renal replacement therapy. The diabetes was also complicated by bilateral retinopathy that was treated by laser and bilateral distal arteriopathy. Our patient was presenting since April 2018, a buttock inflammatory pain in the left side at the first time, which became bilateral 3 months later with visual analogue scale of pain intensity at 8/10, several night awakenings and morning stiffness estimated at 45 min. With the exception of buttock pain, the patient did not present peripheral arthritic and enthesitic involvements, without associated signs, such as uveitis, psoriasis or bowel inflammatory diseases. The clinical symptomatology has evolved in apyrexia and the clinical examination revealed positive sacroiliac joint tests provocation and the body mass index was at 33.4 kg/m². The patient presented a diagnostic and a therapeutic problem. In that case, the laboratory

analysis, radiographic and magnetic resonance imaging assessments were requested.

The laboratory analysis revealed an erythrocyte sedimentation rate (ESR) at 65 mm, C-reactive protein (CRP) at 39.7 mg/l, a microcytic anemia with an hemoglobin level at 10.8 g/dl, a mean corpuscular volume (MCV) at 82 μ^3 and leukocytes were at 10900/mm³ with neutrophil count at 6867/mm³. The glycated hemoglobin level was at 10.9%, urea at 1.67 g/l and creatinine at 68.2 mg/l with creatinine clearance at 9.2 ml/min. Corrected serum calcium level was at 89 mg/l, serum phosphorus level at 35.5 mg/l, parathyroid hormone level at 165.94 pg/ml, alkaline phosphatase level at 85 UI/l and vitamin D level at 20 ng/ml. The patient had a negative procalcitonin and negative leukocyte antigen (HLA) B27.

The radiographic assessment revealed in the pelvic X-ray, a bilateral radiographic sacroiliitis grade 3 (sclerosis on both sides of the joint and irregularity of the joint space) in the right sacroiliac joint and grade 4 (complete ankylosis) in the left sacroiliac joint using the modified New York criteria (**Figure 1**). The skull (**Figure 2**), the hands, the wrists (**Figure 3**) and the lumbar spine (**Figure 4**) x-rays were normal. The magnetic resonance imaging (MRI) of the sacroiliac joints revealed in T1 sequence, a low-intensity signal of subchondral bone with irregularity and narrowing of the bilateral sacroiliac joints space and in STIR sequence, a high-intensity bilateral signal in the iliac and sacrum bone sides compatible with subchondral bone marrow edema (**Figures 5A and 5B**). The bone scintigraphy and the bone densitometry were normal.

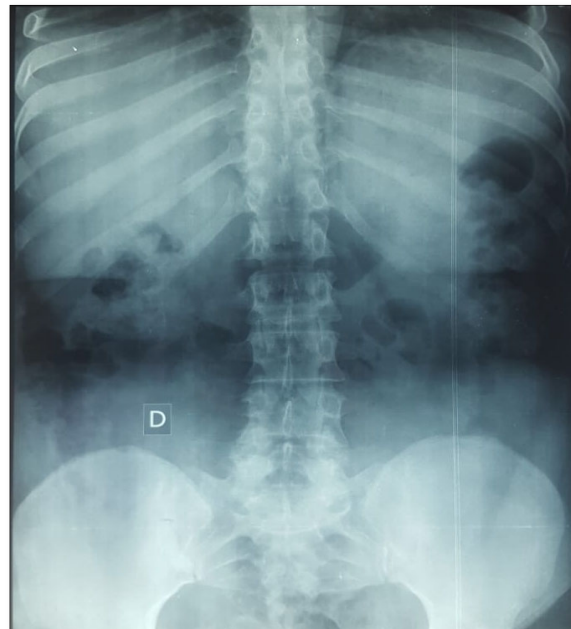


Figure 1. The pelvic X-ray that showed bilateral sacroiliitis, grade 3 in the right sacroiliac joint and grade 4 in the left sacroiliac joint.

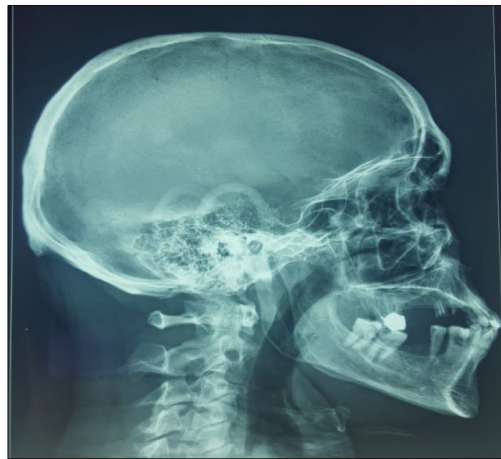


Figure 2. The normal skull x-ray.

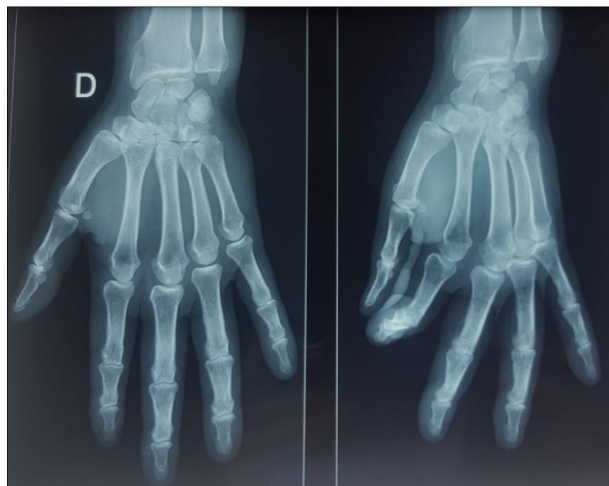


Figure 3. The normal hands and wrists x-ray.

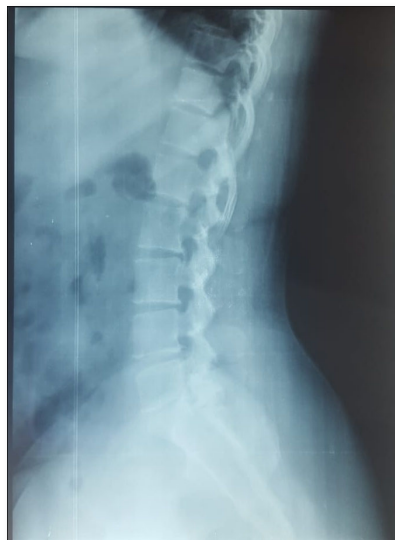

Figure 4. The normal lumbar spine x-ray.

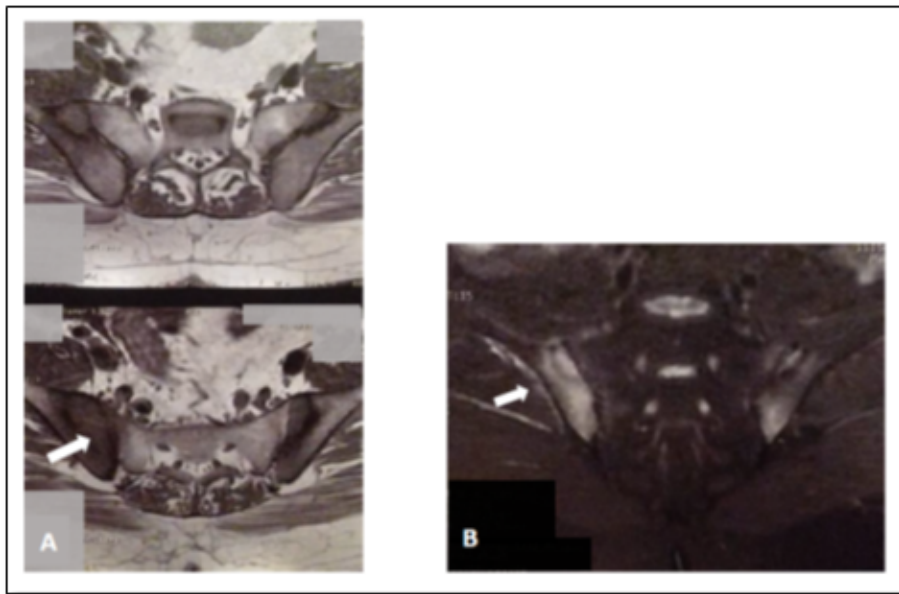


Figure 5. A) T1-weighted coronal oblique image showing periarticular hypo-intensity with greater affecting of the right sacroiliac joint. B) On the STIR sequence, a hyper-intense zone compatible with bone marrow edema.

DISCUSSION

In our case, the first raised diagnosis was the infectious sacroiliitis because the patient was complaining of unilateral inflammatory buttock pain that became bilateral 3 months later with a radiographic sacroiliitis in the pelvic X-ray. Other arguments supporting this diagnosis were the young age of the patient, his status of immunosuppression caused by the imbalanced diabetes and the peritoneal dialysis. This diagnosis was not selected since the patient's overall health status was good, the leukocytes at a normal level in the blood cell count, the level of CRP was not very high at 39.7 mg/l, the procalcitonin was negative and the MRI features were inconsistent with those of infectious sacroiliitis which usually revealed by the periarticular muscle edema, the most important predictor described in the studies and also by an inflammatory enhancement after the injection of Gadolinium [8,9]. Stürzenbecher et al. [10] reported that on MRI, the infectious sacroiliitis shows sub-periosteal infiltrations, which are transcapsular infiltrations of juxta-articular muscle layers and they proposed that these features can be used to differentiate infectious sacroiliitis from other sacroiliitis seen in other disease entities.

The second evoked diagnosis was the secondary hyperparathyroidism caused by chronic kidney failure. It was not selected because of the normal calcium and phosphorus levels, the correlated level of the parathyroid hormone with renal insufficiency and the no abnormalities in the skull, hands, wrists and spine X-rays besides the normal bone scintigraphy and the normal bone densitometry. Hyperparathyroidism may lead to subchondral resorption and pseudo-widening of sacroiliac joint space usually

bilateral, symmetrical and greater on the iliac side which was incompatible with our case [1]. Furthermore, the sacroiliac MRI lesions in secondary hyperparathyroidism are revealed by bone marrow edema that may lead to confusion with the axial spondyloarthritis but without enthesitis, synovitis and periarticular erosions [1,11]. The MRI data obtained in this obese patient can lead to confusion with mechanical diseases such as the sacroiliac osteoarthritis and the osteitis condensans ilii. These diagnoses were eliminated due to the inflammatory buttock pain, the morning stiffness and the increased inflammatory markers. Another diagnosis related to a rare disease, which is the Paget disease was also eliminated considering the normality of alkaline phosphatase level, the normality of the skull radiography and the normality of the bone scintigraphy and also because of the inconsistency of the MRI features with Paget disease.

The last proposed diagnosis that was selected, was the Ankylosing Spondylitis (AS) in his axial radiographic form fulfilling the assessment of SpondyloArthritis International Society-Outcome Measures in Rheumatology Clinical Trials (ASAS-OMERACT) criteria based on the bilateral aspect of the sacroiliitis, the inflammatory syndrome and the specific character of bone marrow edema in sacroiliac MRI, which is compatible with the diagnosis of AS. The four MRI finding of active sacroiliitis are osteitis or bone marrow edema, enthesitis, capsulitis and synovitis. Among these findings, bone marrow edema is the most important criterion in making the diagnosis of AS [1,9].

As a conclusion, it is about a 43-year-old Moroccan male patient with active axial AS who is undergoing peritoneal dialysis since March 2017 due to renal failure, which was

the consequence of diabetic nephropathy. The AS was assessed by different scores reflecting the disease activity with the Bath Ankylosing Spondylitis Disease Activity Index (BASDAI) at 5.07, the Bath Ankylosing Spondylitis Disease Functional Index (BASFI) at 7.7 and the Ankylosing Spondylitis Disease Activity Score-CRP (ASDAS-CRP) at 3.65.

Concerning the therapeutic management, the primary goal is to improve quality of life through the control of inflammation and prevention of structural damage [12]. According to the recent international recommendations of the ASAS (Assessment of SpondyloArthritis International Society)/EULAR (European League Against Rheumatism) 2016 [5] and SFR (French Society of Rheumatology) 2018 [4], the non-steroidal anti-inflammatory drugs (NSAIDs) are the first line drug treatments for the patients with axial AS but their potential for nephrotoxicity limits their use in AS patients with renal insufficiency which is why the anti-tumor necrosis factor-alpha (anti-TNF α) are recommended as a second line treatment [4,5]. The anti-TNF α has been considered as an effective therapy to treat AS patients with high disease activity [12]. In our case, the anti-TNF α represent the most decent drugs and should be the most commonly preferred ones for the treatment of patients with active AS who undergo dialysis but their pharmacokinetics and their metabolism in patients receiving peritoneal dialysis have not been well studied [7].

The international guidelines recommended the administration of intravenous anti-TNF α agents after the session of hemodialysis and for those injected in subcutaneous, the dialysis would not have any effect [13].

Hueber et al. [14] reported the efficacy and safety of the anti-TNF α agents in 11 patients with renal insufficiency: 9 patients with rheumatoid arthritis (RA), 1 patient with psoriatic arthritis, and 1 patient with juvenile rheumatoid arthritis, who were treated with infliximab, etanercept and adalimumab. During the follow-up period of 24 months, no significant increases in serum creatinine were detected and no severe infections or other adverse events were described [6,14]. Don et al. [15] noted the safety of etanercept in six patients with end-stage renal disease receiving hemodialysis (HD) and indicated that the pharmacokinetics of etanercept was similar to those with normal renal function. Etanercept was tolerated by the patients, as there were no side effects noted during the 3 months of the treatment phase and the 6 months of follow-up [7,15]. Hammoudeh have demonstrated that the infliximab was a safe and effective treatment for patients with active RA who were undergoing HD during 6 months [16]. Sugioka et al. [17] showed the effectiveness of etanercept in patients with active RA refractory to conventional treatment without any side effect during 12 weeks of treatment. Saougou et al. [18] suggested that infliximab treatment in a patient with psoriatic arthritis undergoing HD could be safe, effective and well tolerated.

Shimajima et al. [19] reported the effectiveness of adalimumab as a therapeutic option in a patient with psoriatic arthritis undergoing HD for chronic renal failure. Concerning the peritoneal dialysis (PD), Kobak [20] reported the efficacy of adalimumab in 65-year-old male patient with active AS receiving PD over a treatment period of 12 weeks.

In 2013, Choi et al. [7] demonstrated the safety and efficacy of etanercept in a 40-year-old male AS patient undergoing PD. During 9 months of treatment, there were significant improvements in disease activity scores without any side effects.

In our case, based on the results of the literature, we opted for etanercept as a treatment. The assessment before the anti-TNF α therapy was normal and the patient received etanercept at a 25 mg dose twice weekly administered subcutaneously. Improvements were noted in clinical and laboratory findings at the follow-up visits performed at 12 and 26 weeks after the initial drug administration. At the ninth month of treatment, buttock pain was relieved, the duration of morning stiffness was reduced to less than 10 min and significant improvement was noted in disease activity scores without any adverse effect on kidney function. The Erythrocyte Sedimentation Rate (ESR) was at 30 mm, C-reactive protein (CRP) at 4.8 mg/l, BASDAI at 3.02, BASFI at 4.1 and ASDAS-CRP at 1.8. Further clinical studies are required to assess the use of etanercept in long-term.

CONCLUSION

This clinical case raised two issues in a patient who complained of buttock inflammatory pain receiving peritoneal dialysis with radiographic and MRI sacroiliitis. The first issue was the diagnosis because many diseases can involve sacroiliac joints in patients with end-stage renal disease. The second issue, after having retaining the diagnosis of active axial ankylosing spondylitis, was the therapeutic management. Taking into account the recent international recommendations and the successful outcomes of the anti-TNF α agents reported in the literature as an alternative treatment, we have chosen etanercept as treatment. The marked clinical and laboratory regression, the significant improvements in disease activity scores without any side effects confirm the efficacy and the safety of etanercept in the treatment of ankylosing spondylitis patient undergoing peritoneal dialysis.

DECLARATIONS

Ethical approval and consent to participate

Not applicable.

Consent for publication

Written informed consent for publication was obtained from the patient.

Availability of data and material

The datasets are available from the corresponding author on reasonable request.

Competing interests

The authors declare that they have no competing interests.

Funding

There was no funding for the research concerning this manuscript.

Authors' contributions

SB drafted this manuscript, collected the data and reviewed the literature. BA, IE, SR and RB reviewed critically the manuscript. All authors have read and approved the final manuscript.

Acknowledgement

I am grateful for the help and the assistance of my professor Bouchra Amine.

REFERENCES

1. Tezcan ME, Temizkan S, Ozal ST, Gul D, Aydin K, et al. (2016) Evaluation of acute and chronic MRI features of sacroiliitis in asymptomatic primary hyperparathyroid patients. *Clin Rheumatol* 35: 2777-2782.
2. Piccoli GB, Quaglia M, Mezza E, Burdese M, Lacuzzo C, et al. (2002) Ankylosing spondylitis: A difficult diagnosis in patients on long-term renal replacement therapy. *J Nephrol* 15:177-1782.
3. Antonelli JM, Magrey M (2017) Sacroiliitis mimics: A case report and review of the literature. *BMC Musculoskelet* 18: 170.
4. Wendling D, Lukas C, Prati C, Claude pierre P, Gossec L, et al. (2018) Update of French Society for Rheumatology (SFR) recommendations about the everyday management of patients with spondylo arthritis. *Joint Bone Spine* 85: 275-284.
5. Heijde DV, Ramiro S, Land ewe R, Baraliakos X, Bosch FV, et al. (2017) 2016 update of the ASAS-EULAR management recommendations for axial spondylo arthritis. *Ann Rheum Dis* 76: 978-991.
6. Sumida K, Ubara Y, Suwabe T, Hayami N, Hiramatsu R, et al. (2013) Adalimumab treatment in patients with rheumatoid arthritis with renal insufficiency. *Arthritis Care Res (Hoboken)* 65: 471-475.
7. Choi SA, Lee S, Song S, Kim J, Jang HY, et al. (2013) A case of etanercept treatment in a patient with ankylosing spondylitis on peritoneal dialysis. *J Rheum Dis* 20: 361-363.
8. Malhotra A, Kalil R, Jones R, Schwartz D, Qadeer AH, et al. (2017) Infectious sacroiliitis: A radiographic no touch lesion. *J Gen Pract* 5: 5.
9. Kang Y, Hong SH, Kim JY, Yoo HJ, Choi JY, et al. (2015) Unilateral sacroiliitis: Differential diagnosis between infectious sacroiliitis and spondylo arthritis based on MRI findings. *AJR Am J Roentgenol* 205: 1048-1055.
10. Stürzenbecher A, Braun J, Paris S, Biedermann T, Hamm B, et al. (2000) MR imaging of septic sacroiliitis. *Skeletal Radiol* 29: 439-446.
11. Yu HI, Lu CH (2012) Sacroiliitis-like pain as the initial presentation of primary hyperparathyroidism. *Arch Osteoporos* 7: 315-318.
12. Heijde DV, Sieper J, Maksymowych WP, Dougados M, Burgos-Vargas R, et al. (2011) Assessment of Spondylo Arthritis International Society. 2010 Update of the International ASAS recommendations for the use of anti-TNF agents in patients with axial spondyloarthritis. *Ann Rheum Dis* 70: 905-908.
13. Club Rhumatismes et Inflammations (2014) Clinical tools guides: Anti-TNF α -Therapy and Safety Management.
14. Hueber AJ, Tunc A, Schett G, Manger B (2007) Anti-tumor necrosis factor α therapy in patients with impaired renal function. *Ann Rheum Dis* 66: 981-982.
15. Don BR, Spin G, Nestorov I, Hutmacher M, Rose A, et al. (2005) The pharmacokinetics of etanercept in patients with end-stage renal disease on hemodialysis. *J Pharm Pharmacol* 57: 1407-1413.
16. Hammoudeh M (2006) Infliximab treatment in a patient with rheumatoid arthritis on hemodialysis. *J Rheumatol* 45: 357-359.
17. Sugioka Y, Inui K, Koike T (2008) Use of etanercept in a patient with rheumatoid arthritis on hemodialysis. *Mod Rheumatol* 18: 293-295.
18. Saougou I, Papagoras C, Markatseli TE, Voulgari PV, Drosos AA (2010) A case report of a psoriatic arthritis patient on hemodialysis treated with tumor necrosis factor blocking agent and a literature review. *Clin Rheumatol* 29: 1455-1459.
19. Shimojima Y, Matsuda M, Ishii W, Ikeda S (2012) Adalimumab immunotherapy in a patient with psoriatic arthritis associated with chronic renal failure on hemodialysis: A case report and literature review. *Clin Med Insights Case Rep* 5:13-17.
20. Kobak S (2012) Efficacy and safety of adalimumab in a patient with ankylosing spondylitis on peritoneal dialysis. *Rheumatol Int* 32: 1785-1787.